

JOURNAL OF SHOULDER AND ELBOW SURGERY

The Compendium of Shoulder Outcomes and Research

A 2017 Review of the Last Decade

Guest Editor: T. Bradley Edwards, MD

Publication support provided by Exactech, Inc.

ELSEVIER

ISSN 1058-2746

www.jshoulderelbow.org

JOURNAL OF SHOULDER AND ELBOW SURGERY

Editor-in-Chief

William J. Mallon, MD, *Hilton Head Island, SC, USA*

Deputy International Editor

Pierre Mansat, MD, PhD
Toulouse, France

Editor Emeritus - 1996-2008

Robert J. Neviaser, MD
Washington, DC, USA

Founding Editor - 1991-1996

Robert H. Cofield, MD
Rochester, MN, USA

BOARD OF TRUSTEES

Evan L. Flatow, MD, Chairman, *New York, NY, USA*

Frances Cuomo, MD, Secretary, *New York, NY, USA*

Christopher M. Jobe, MD, Treasurer, *Loma Linda, CA, USA*

Frank A. Cordasco, MD, MS, *New York, NY, USA*

Roger Emery, MS, FRCS, *London, UK*

Eiji Itoi, MD, PhD, *Sendai, Japan*

Jon J.P. Warner, MD, *Boston, MA, USA*

W. Jaap Willems, MD, PhD, *Bergen, The Netherlands*

William J. Mallon, MD, *Hilton Head Island, SC, USA (ex-officio)*

Associate Editors

Samuel Antuña, MD
Madrid, Spain

April Armstrong, MD, FRCS
Hershey, PA, USA

Eiji Itoi, MD, PhD
Sendai, Japan

In-Ho Jeon, MD, PhD
Seoul, Republic of Korea

Chunyan Jiang, MD, PhD
Beijing, China

Peter MacDonald, MD, FRCS(C)
Winnipeg, MB, Canada

Nicole Pouliart, MD, PhD
Brussels, Belgium

Joaquín Sánchez-Sotelo, MD, PhD
Rochester, MN, USA/Spain

Michael J. Sandow, MD
Adelaide, SA, Australia

John W. Sperling, MD, MBA
Rochester, MN, USA

David Stanley, MD
Sheffield, UK

John M. "JT" Tokish, MD
Greenville, SC, USA

Review and Special Projects Editors

T. Bradley Edwards, MD, *Houston, TX, USA*

John E. Kuhn, MD, MS, *Nashville, TN, USA*

Basic Science Editors

Leesa Galatz, MD, *New York, NY, USA*

Thay Q. Lee, PhD, *Long Beach, CA, USA*

Social Media Editors

Joshua S. Dines, MD, *New York, NY, USA*, Chief Social Media Editor

Asheesh Bedi, MD, *Ann Arbor, MI, USA*

Salma Chaudhury, MD, PhD, MRCS, *Oxford, UK*

Derek Cuff, MD, *Sarasota, FL, USA*

Christopher C. Dodson, MD, *Philadelphia, PA, USA*

Dennis Liem, MD, *Münster, Germany*

Michael W. Maier, MD, *Heidelberg, Germany*

Assistant Editors

Joseph A. Abboud, MD
Philadelphia, PA, USA

J. Mack Aldridge, III
Durham, NC, USA

Thomas Ambacher, MD
Stuttgart-Feuerbach, Germany

George S. Athwal, MD, FRCS(C)

London, ON, Canada

Desmond J. Bokor, MD

Parramatta, NSW, Australia

Juan Bruguera, MD, PhD

Pamplona, Spain

Ulrich Brunner, MD

Hausham, Germany

Emilio Calvo, MD

Madrid, Spain

Antonio Cartucho, MD

Lisboa, Portugal

Alessandra Castagna, MD

Milano, Italy

Andrea Celli, MD

Modena, Italy

R. Sean Churchill, MD

Milwaukee, WI, USA

Carlos Alberto deAnquin, MD

Cordoba, Argentina

Mathijs A. de Beer, MD

Pretoria, South Africa

Lieven de Wilde, MD

Ghent, Belgium

Fabrice Duparc, PhD

Rouen, France

Xavier Duralde, MD

Atlanta, GA, USA

Roger Emery, MS, FRCS

London, UK

Donald Endrizzi, MD

Portland, ME, USA

Alain Farron, MD

Lausanne, Switzerland

Edward V. Fehringer, MD

Omaha, NE, USA

Mark A. Frankle, MD
Temple Terrace, FL, USA

Michael Q. Freehill, MD
Edina, MN, USA

Barbara G. Frieman, MD
Philadelphia, PA, USA

Grant E. Garrigues, MD

Durham, NC, USA

Dominique F. Gazielly, MD

Paris, France

Gordon I. Groh, MD

Asheville, NC, USA

Frank Handelberg, MD

Brussels, Belgium

Steven J. Hattrup, MD

Phoenix, AZ, USA

Marian M. "Moose" Herring, MD

Richmond, VA, USA

Hsu Horn-Chaung, MD

Taichung, Taiwan

Junji Ide, MD, PhD

Kumamoto, Japan

Andreas Imhoff, MD

München, Germany

Jörg Jerosch, MD

Neuss, Germany

Jay D. Keener, MD

St. Louis, MO, USA

Graham J. W. King, MD

London, ON, Canada

Joyce S. B. Koh, MD

Singapore

Sumant G. "Butch" Krishnan, MD

Dallas, TX, USA

Jun Kumagai, MD, PhD

Yamagata, Japan

V. Prem Kumar, MD

Singapore

Ofer Levy, MD

Reading, UK

Sven Lichtenberg, MD

Heidelberg, Germany

Petra Magosch, MD

Heidelberg, Germany

Marco Maiotti, MD
Rome, Italy

Nancy M. Major, MD
Philadelphia, PA, USA

Peter J. Millett, MD
Vail, CO, USA

A. Daniel Moya, MD

Buenos Aires, Argentina

George Murrell, MD, PhD

Sydney, NSW, Australia

Anand Murthi, MD

Baltimore, MD, USA

Gregory P. Nicholson, MD

Chicago, IL, USA

Thomas J. Noonan, MD

Denver, CO, USA

Richard W. Nyffeler, MD

Bern, Switzerland

Jin-Young Park, MD

Chonan, Republic of Korea

Steve A. Petersen, MD

Lutherville, MD, USA

Wolfgang Pözl, MD

Bad Rappenau, Germany

Giuseppe Porcellini, MD

Forlì, Italy

Shalini Ramasunder, MD

Durham, NC, USA

Markus Rickert, MD

Heidelberg, Germany

David C. Ring, MD, PhD

Austin, TX, USA

Raffaele Russo, MD

Naples, Italy

Felix H. "Buddy" Savole, III, MD

New Orleans, LA, USA

Markus Scheibel, MD

Berlin, Germany

Alberto G. Schneeberger, MD

Zürich, Switzerland

Paul M. Sethi, MD

Greenwich, CT, USA

Kim Seung-Ho, MD

Seoul, Republic of Korea

Kevin P. Speer, MD
Durham, NC, USA

Patrick St. Pierre, MD
Rancho Mirage, CA, USA

Scott P. Steinmann, MD
Rochester, MN, USA

Norbert Südkamp, MD

Freiburg, Germany

Hiroyuki Sugaya, MD

Chiba, Japan

Masatoshi Takahara, MD, PhD

Yamagata, Japan

Kazuya Tamai, MD, PhD

Tochigi, Japan

Matthew M. Tomaino, MD

Rochester, NY, USA

Carlos Torrens, MD

Barcelona, Spain

Markus Wambacher, MD

Innsbruck, Austria

Stephen C. Weber, MD

Chevy Chase, MD, USA

J. Michael Wiater, MD

Beverly Hills, MI, USA

Jaap Willems, MD

Amsterdam, The Netherlands

Basic Science Assistant Editors

Richard E. Debski, PhD
Pittsburgh, PA, USA

James A. Johnson, PhD
London, ON, Canada

Helmut Lill, PhD
Hannover, Germany

Statistical Editor
Deanne M. Dilley, MPH

Raleigh, NC, USA

Managing Editor
Sarah Nevill

Basel, Switzerland

JOURNAL OF SHOULDER AND ELBOW SURGERY

SPONSORING SOCIETIES

American Shoulder and Elbow Surgeons

Felix H. "Buddy" Savoie, III, MD, President,
New Orleans, LA
Anthony A. Romeo, MD, President-Elect, *Chicago, IL*
C. Craig Satterlee, MD, Secretary/Treasurer,
Kansas City, MO
American Shoulder and Elbow Surgeons
9400 West Higgins Road, Suite 500
Rosemont, IL 60018-4976, USA
www.ases-assn.org

European Society for Surgery of the Shoulder and Elbow

Roger Emery, MS FRCS, President, *London, UK*
Juan Bruguera, MD, Secretary, *Pamplona, Spain*
Emilio Calvo, MD, Treasurer, *Madrid, Spain*
European Society for Surgery of Shoulder and Elbow
50-52 Avenue Chanoine Cartellier
69230 Saint-Genis-Laval, France
www.secec.org/
British Elbow and Shoulder Society
Danish Society for Surgery of the Shoulder and Elbow
Finnish Shoulder Society
German Society for Shoulder and Elbow Surgery
French Society of Shoulder and Elbow
Italian Society of Shoulder and Elbow Surgery
Spanish Society for Surgery of Shoulder and Elbow
Swedish Society for Shoulder and Elbow Surgery

Japan Shoulder Society

Kazuya Tamai, MD, President, *Mibu, Tochigi, Japan*
Eiji Itoi, MD, PhD, Vice-President, *Sendai, Japan*
Yozo Shibata, MD, PhD, Vice-President, *Chikushino,
Fukuoka*
Secretariat (c/o ISS, INC.)
Mita MT Bldg. 8F,
3-13-12 Mita Minato-ku,
Tokyo, 108-0073 Japan
www.j-shoulder-s.jp

Shoulder and Elbow Society of Australia

Allan Wang, MD, President
Perth, WA, Australia
Paul Jarrett, MD, Secretary/Treasurer
Perth, WA, Australia
www.sesaaustralia.org.au

Latin American Shoulder and Elbow Society

Arturo Gutiérrez Meneşes, MD, President
Ciudad de México, México
Luis J. Macedo Linares, MD
Lima, Peru

South African Shoulder and Elbow Surgeons

Phillip Webster, MD, President, *Johannesburg,
South Africa*
Stephen Roche, MD, Secretary, *Cape Town,
South Africa*
South African Shoulder and Elbow Surgeons
c/o Dr P. Webster
1538 Cramerview
Johannesburg 2060
South Africa
pwebster@global.co.za

Asian Shoulder Association

Jiunn-Jer Wu, MD, President
Taipei, Taiwan
Kai-Ming Chan, MD, Secretary
Tai Wai, New Territories, Hong Kong
Asian Shoulder Association
c/o Dr Jiunn-Jer Wu
Department of Orthopaedics & Traumatology
Veterans General Hospital-Taipei
201 Shih-Pai Road, Sec. 2
Taipei, Taiwan 11217

Korean Shoulder and Elbow Society

Sang Jin Cheon, MD, PhD, President
Jae Chul Yoo, MD, Secretary General
Department of Orthopaedic Surgery
Samsung Medical Center
81 Irwon-ro Gangnam-gu
06351 Seoul, Republic of Korea
www.kses.or.kr

International Congress of Shoulder and Elbow Surgery

International Board of Shoulder and Elbow Surgery
Louis U. Bigliani, MD, Chairman
Columbia University Medical Center
Department of Orthopaedic Surgery
New York, NY 10032-2713, USA
www.icses.org

American Society of Shoulder and Elbow Therapists

Stephen Thomas, PhD, ATC, President,
Philadelphia, PA
Jeffrey Fleming, DPT, OCS, ATC, CSCS,
Secretary/Treasurer, *Iowa City, IA*
American Society of Shoulder and Elbow Therapists
9400 West Higgins Road, Suite 500
Rosemont, IL 60018-4976, USA
www.asset-usa.org

Shoulder and Elbow Society of India

J. Maheshwari, MD, President, *Delhi, India*
D. Bhatia, MD, Secretary, *Mumbai, India*
A. Babhulkar, MD, Academic Liaison, *Pune, India*
www.sessionline.org

JOURNAL OF SHOULDER AND ELBOW SURGERY

Copyright © 2017 by *Journal of Shoulder and Elbow Surgery* Board of Trustees

CONTENTS

The Journal is included in the *Index Medicus* and in MEDLINE

The Compendium of Shoulder Outcomes and Research
A 2017 Review of the Last Decade

Guest Editor: T. Bradley Edwards, MD

Introduction

T. Bradley Edwards, MD 5A

An evaluation of the relationships between reverse shoulder design parameters and range of motion, impingement, and stability

*Chris Roche, MS, Pierre-Henri Flurin, MD, Thomas Wright, MD, Lynn A. Crosby, MD,
Michael Mauldina, Joseph D. Zuckerman, MD* 18(2009)734-741

Outcomes of reverse total shoulder arthroplasty in a senior athletic population

*Ryan W. Simovitch, MD, Berenice K. Gerard, MS, Jordon A. Brees, PA-C, Robert Fullick, MD,
Justin C. Kearse, MD* 24(2015)1481-1485

The incidence of radiographic aseptic loosening of the humeral component in reverse total shoulder arthroplasty

*Gregory Gilot, MD, Andres M. Alvarez-Pinzon, MD, PhD, Thomas W. Wright, MD,
Pierre-Henri Flurin, MD, Michael Krill, MD, Howard D. Routman, DO,
Joseph D. Zuckerman, MD* 24(2015)1555-1559

Early revision within 1 year after shoulder arthroplasty: patient factors and etiology

*Brian C. Werner, MD, M. Tyrrell Burrus, MD, Itse Begho, BS, F. Winston Gwathmey, MD,
Stephen F. Brockmeier, MD* 24(2015)e323-330

Factors predicting postoperative range of motion for anatomic total shoulder arthroplasty

Jonathan C. Levy, MD, Moses T. Ashukem, MD, Nathan T. Formaini, DO 25(2016)55-60

Publication information. *Journal of Shoulder and Elbow Surgery* (ISSN: 1058-2746) is published monthly by Elsevier Inc., 360 Park Avenue South, New York, NY 10010-1710. Business and Editorial Offices: 1600 John F. Kennedy Blvd., Suite 1800, Philadelphia, PA 19103-2899. Elsevier Customer Service Office: 3251 Riverport Lane, Maryland Heights, MO 63043. Periodicals postage paid at New York, NY and additional mailing offices.

USA POSTMASTER: Send address changes to *Journal of Shoulder and Elbow Surgery*, Elsevier Periodicals Customer Service, 3251 Riverport Lane, Maryland Heights, MO 63043.

Posterior augmented glenoid implants require less bone removal and generate lower stresses: a finite element analysis	
<i>Jared J. Allred, MD, Cesar Flores-Hernandez, BS, Heinz R. Hoenecke Jr, MD, Darryl D. D'Lima, MD, PhD</i>	25(2016)823-830
Reverse total shoulder arthroplasty with structural bone grafting of large glenoid defects	
<i>Richard B. Jones, MD, Thomas W. Wright, MD, Joseph D. Zuckerman, MD</i>	25(2016)1425-1432
Comparison of Reverse Total Shoulder Arthroplasty Outcomes With and Without Subscapularis Repair	
<i>Richard J. Friedman, MD, FRCSC, Pierre-Henri Flurin, MD, Thomas W. Wright, MD, Joseph D. Zuckerman, MD, Christopher P. Roche, MSE, MBA</i>	In press(2017)
Impact of scapular notching on clinical outcomes after reverse total shoulder arthroplasty: an analysis of 476 shoulders	
<i>Brent Mollon, MD, FRCSC, Siddharth A. Mahure, MBA, MD, Christopher P. Roche, MSE, Joseph D. Zuckerman, MD</i>	In press(2017)
Sports after shoulder arthroplasty: a comparative analysis of hemiarthroplasty and reverse total shoulder replacement	
<i>Joseph N. Liu, MD, Grant H. Garcia, MD, Gregory Mahony, BA, Hao-Hua Wu, BA, David M. Dines, MD, Russell F. Warren, MD, Lawrence V. Gulotta, MD</i>	25(2016)920-926
Preoperative patient-reported scores can predict postoperative outcomes after shoulder arthroplasty	
<i>Stephanie E. Wong, MD, Alan L. Zhang, MD, Jonathan L. Berliner, MD, C. Benjamin Ma, MD, Brian T. Feeley, MD</i>	25(2016)913-919

JOURNAL OF SHOULDER AND ELBOW SURGERY

INTRODUCTION

It is my honor to serve as guest editor for this special supplement of the *Journal of Shoulder and Elbow Surgery*. In this issue, we present a portion of the ongoing work of the Exactech Equinox research team and some selected studies from others in the field of shoulder arthroplasty. The Exactech Equinox team has been prolific, and selecting only eleven studies for inclusion in this special issue was no easy task. I believe, however, the eleven papers selected represent the "best of the best" of recent work in shoulder arthroplasty.

This issue opens with a basic science study that has provided the basis for implant innovation and design. Roche and colleagues demonstrate how small changes in design parameters can influence impingement-free mobility and stability in reverse shoulder arthroplasty. In a second basic science study included in this issue, Allred et al. shift direction from reverse shoulder arthroplasty to anatomic shoulder arthroplasty and demonstrate a potential role for posterior augmented glenoid components in preserving glenoid bone.

Building on the foundation of basic science, the nine selected clinical papers provide valuable information as we move forward with our use of both anatomic and reverse shoulder arthroplasty. Gilot and colleagues show that our initial concerns of humeral loosening in reverse shoulder arthroplasty are largely unfounded with reverse humeral components loosening less frequently than anatomic stems. Simovitch's group further allayed our fears of failure of reverse shoulder arthroplasty by showing that athletic participation does not lead to loosening of reverse shoulder implants, while the Hospital for Special Surgery group shows that reverse shoulder

arthroplasty is superior to hemiarthroplasty in the older athletic population. Friedman et al. sought to further clarify the importance of the subscapularis following reverse shoulder arthroplasty determining that the subscapularis is perhaps not as important to prosthetic stability when using a lateralized implant compared to a more traditional "Grammont style" implant. Jones and colleagues demonstrated that structural allografts may be an acceptable alternative to autograft when performing reverse shoulder arthroplasty in the setting of large glenoid bone defects. Mollon and colleagues' contribution to this issue shows that our quest to eliminate scapular notching is important as notching indeed compromised the clinical results of reverse shoulder arthroplasty in this large patient cohort.

Werner et al. identified several patient related factors that are predictive of early failure following shoulder arthroplasty. Levy and associates confirm that preoperative mobility is predictive of postoperative mobility following anatomic shoulder arthroplasty. Finally, this special issue concludes with the work of Wong and colleagues examining the role of preoperative patient reported score in predicting the results of shoulder arthroplasty.

Hopefully, this issue will serve as a valuable reference for orthopedic surgeons performing shoulder arthroplasty. I would like to thank the contributors who took their time to provide others with their research and their experience. I truly appreciate the invitation extended to me to edit this issue.

T. Bradley Edwards, MD
Guest Editor



An evaluation of the relationships between reverse shoulder design parameters and range of motion, impingement, and stability

Chris Roche, MS^a, Pierre-Henri Flurin, MD^b, Thomas Wright, MD^c, Lynn A. Crosby, MD^d, Michael Mauldin^a, Joseph D. Zuckerman, MD^{e,*}

^aExactech Inc, Gainesville, FL

^bBordeaux-Merignac Clinic, Bordeaux-Merignac, France

^cDepartment of Orthopaedic Surgery, University of Florida School of Medicine, Gainesville, FL

^dDepartment of Orthopaedic Surgery, Wright State University, Dayton, OH

^eDepartment of Orthopaedic Surgery, New York University Hospital for Joint Diseases, New York, NY

Background: The purpose of this study was to evaluate the role of reverse shoulder design parameters on performance.

Methods: A computer analysis was conducted on the Grammont reverse shoulder to quantify the effect of varying design parameters on functional measurements during humeral abduction/adduction. To demonstrate the application of these relationships, a novel prosthesis was designed.

Results: The Grammont reverse shoulder impinged inferiorly and superiorly on the glenoid at 31° and 95° of humeral abduction with an average jump distance of 10 mm. Several linear relationships were identified. The proposed 38 mm, 42 mm, and 46 mm reverse shoulder designs impinged inferiorly and superiorly on the glenoid at 7.3°/87.5°, 1°/87.5°, and 0°/89.3° of humeral abduction with an average jump distance of 11.7 mm, 13.5 mm, and 14.1 mm, respectively.

Conclusions: The results of this study demonstrate that subtle changes in design parameters can minimize inferior glenoid impingement and offer potential for dramatic functional improvements in ROM (39%) and jump distance (36%).

Level of evidence: Basic Science Study, Computer Analysis.

© 2009 Journal of Shoulder and Elbow Surgery Board of Trustees.

Keywords: Reverse shoulder prosthesis; computer analysis; glenoid impingement; glenoid; design parameters; shoulder range-of-motion; Exactech Equinox[®]

In the early 1990s, Paul Grammont designed a novel reverse shoulder prosthesis. Like previous designs,^{1,3,8,9,18,19,23,24,37}

*Reprint requests: Joseph D. Zuckerman, MD, Professor and Chairman, NYU Hospital for Joint Diseases, Department of Orthopaedic Surgery, 301 E 17 St, 14 Flr, New York, NY.

E-mail address: 10003.joseph.zuckerman@med.nyu.edu (J.D. Zuckerman).

the Grammont inverted the anatomic concavities of the glenohumeral joint to resolve superior humeral head migration. Unlike previous designs, the Grammont shifted the center of rotation medially to the glenoid fossa to reduce the effective lever arm and distally to tension the deltoid and improve its mechanics.⁵ These design improvements have been demonstrated to alleviate pain and improve function in patients with

cuff tear arthropathy,^{5-7,11,16,17,25,29,31,34} a degenerative condition that has been previously treated, with unpredictable results.^{2,10,14,22,27,30,32,35,36,38}

Reports of successful outcomes with reverse shoulder arthroplasty have led to an expansion of its indications and an increase in the number of analogous reverse shoulder designs available in the marketplace, despite the well-documented complication rates. The incidence of scapular notching is often reported to be greater than 50%,^{6,28,29,31,34} whereas the incidence of instability and dislocation is often reported to exceed 10%, particularly in revisions.^{4,17} Several studies have also documented that scapular notching can be progressive^{20,28,34} and clinically significant,^{12,28,29,33} being associated with poorer clinical outcomes as well as reduced motion and strength.²⁸ These concerns have led surgeons to modify the implantation technique in a manner not originally intended by the manufacturers by placing the glenosphere in an inferior position or with a inferiorly directed tilt, or both.²¹

More recent reverse shoulder designs have attempted to minimize inferior glenoid impingement by lateralizing the humerus and center of rotation. The clinical effects of such design modifications are historical^{1,3,8,9,18,19,23,24,37} and associated with both positive and negative consequences. A study by Gutiérrez et al¹⁵ demonstrated that lateralizing the center of rotation was linearly correlated with improved range of motion (ROM) but was also associated with a larger lever arm and (by definition) increased torque on the glenoid.

Lateralizing the center of rotation (ie, increasing glenosphere thickness relative to diameter) is not the only approach to improve ROM and minimize inferior glenoid impingement. As mentioned, surgeons have modified their implantation techniques to distally shift or inferiorly tilt, or both, the glenosphere to improve ROM and minimize inferior glenoid impingement.²¹ These modifications, however, are associated with secondary consequences. For example, in reverse shoulder designs with fixed-angle screws, a distal shift of the glenosphere can lead to screw perforation in certain glenoid morphologies (ie, a “squared-off scapular neck”), as described by Roberts et al²⁶ (Figure 1). In addition, inferiorly tilting the glenosphere is more technically challenging, particularly for a superior–lateral surgical approach, and requires removal and reaming of the inferior portion of the glenoid (Figure 2).

Therefore, the purpose of this study was to quantify the relationships between these and other design parameters and the commonly reported clinical failure modes, and to use this data to design a novel reverse shoulder prosthesis that minimizes inferior impingement and maximizes ROM and stability without removing the inferior glenoid or excessively lateralizing the center of rotation.

Materials and methods

The Grammont reverse shoulder prosthesis was geometrically modeled using 3-dimensional (3D) computer-aided design

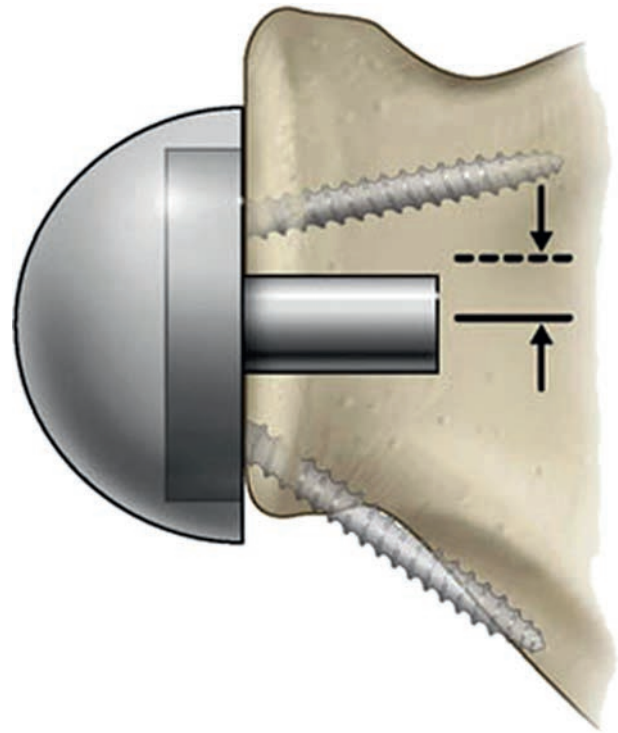


Figure 1 Distally shifting the glenosphere can lead to inferior screw perforation in certain glenoid morphologies if the inferior screw has a fixed angle.²⁶

software (Unigraphics, UGS Inc/Siemens, Plano, TX) and assembled to a 3D digitized male scapula (Zygot Media Group Inc, Lindon, UT) to create a functional glenohumeral joint. Before assembly, about 2 mm of bone was digitally removed from the glenoid fossa of the digitized scapula to create a flat surface and simulate surgical preparation. A geometric computer analysis then quantified the effect of varying prosthesis design parameters on functionally relevant measurements during simulated humeral abduction/adduction in the scapular plane. The evaluated design parameters were humeral neck angle, humeral liner constraint, and glenosphere thickness, diameter, and distal offset. The evaluated functionally relevant measurements were inferior impingement, superior impingement, ROM, and jump distance.

We defined humeral liner constraint as the ratio of humeral liner depth to width. It should be noted that a humeral liner constraint exceeding 0.5 is a constrained joint. We defined glenosphere distal offset as the amount of glenosphere distal overhang achieved by shifting the glenosphere distally on the glenoid fossa. As a point of reference, the glenoid baseplate (eg, “the metaglene”) was assembled so that 0 mm of glenosphere distal offset corresponded to where the glenoid baseplate stem was “slightly inferior to the center of the glenoid,” the implantation position recommended in the manufacturers’ surgical technique.

We used the following definitions in our study:

- Inferior impingement was the degree of humeral abduction at which point the medial portion of the humeral liner impinged on the inferior scapula.
- Superior impingement was the degree of humeral abduction at which point the lateral portion of the humeral liner impinged on the superior portion of the glenoid articular surface.

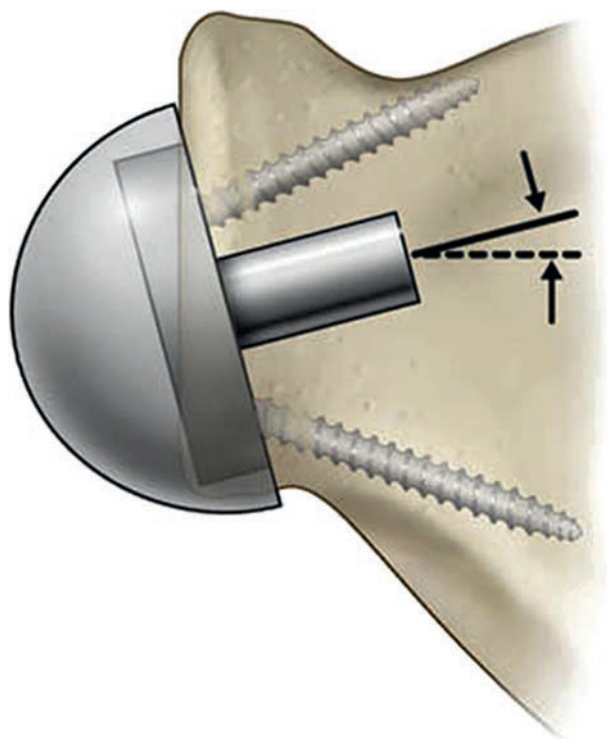


Figure 2 Inferiorly tilting the glenosphere requires removal of the inferior portion of the glenoid (shown translucently).

- ROM was the humeral abduction/adduction occurring between inferior and superior impingement.
- Jump distance was the lateral distance necessary for the glenosphere to escape from the humeral liner at varying degrees of abduction; it is a measure of stability, the resistance to dislocation (discounting the contribution of lever-out by impingement; Figure 3).

Specifically, inferior impingement, superior impingement, ROM, and jump distance were quantified and compared for each of the following design conditions: as humeral neck angle varied from 135° to 165° ; as humeral constraint varied from 0.250 to 0.300; as glenosphere thickness varied from 18 to 24 mm; as glenosphere diameter varied from 34 to 44 mm, and as the glenosphere was distally offset from 0 to 6 mm of overhang. The effect of each was assessed independently to evaluate individual contributions on impingement, motion, and jump distance and in combination to evaluate combined contributions on impingement and motion. The coefficient of determination (R^2) was used to quantify the linear regression of each design parameter and each functionally relevant measurement.

To demonstrate the applications of these elucidated relationships, a novel reverse shoulder prosthesis was designed and geometrically modeled using Unigraphics 3D computer-aided design software. Specifically, 3 prostheses were proposed (38, 42, and 46 mm), each with a humeral neck angle of 145° , a curved-back glenoid baseplate with a 4-mm superiorly offset stem, and different combinations of humeral liner constraint, glenosphere diameter, and glenosphere thickness. The 38-mm design has a humeral liner constraint of 0.260, a 38×21 -mm glenosphere, and provides 2.25 mm of distal glenosphere overhang. The 42-mm

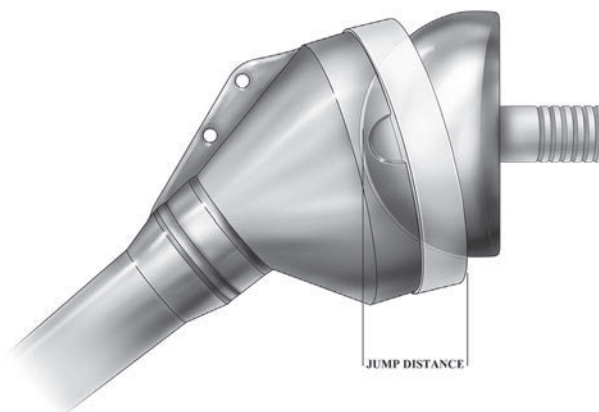


Figure 3 Jump distance is defined as the lateral distance necessary for the glenosphere to escape from the humeral liner at varying degrees of abduction.

design has a humeral liner constraint of 0.250, a 42×23 -mm glenosphere, and provides 4.25 mm of distal glenosphere overhang. The 46-mm design has a humeral liner constraint of 0.240, a 46×25 -mm glenosphere, and provides 6.25-mm of distal glenosphere overhang.

Prior to conducting the geometry analysis, each proposed prosthesis was assembled to the digitized scapula (<1 mm of bone was removed to create a spherical curvature on the glenoid fossa to simulate surgical preparation). For comparative purposes, inferior impingement, superior impingement, and jump distance were quantified during simulated humeral abduction/adduction in the scapular plane.

The relationships derived from the geometric computer analysis were validated by conducting a sawbones laboratory analysis using the proposed reverse shoulder prostheses. This laboratory validation was completed in 2 stages; in each stage a goniometer was used to measure the angle of abduction when the proposed humeral prostheses contacted the inferior scapula (ie, inferior impingement) and when the proposed humeral prostheses contacted the superior scapula (ie, superior impingement).

The first stage enabled a direct comparison of impingement and motion for each proposed prosthesis with that predicted by the geometric analysis. The proposed glenoid prostheses were prepared according to the prescribed technique in a left glenoid sawbone (model 1050-10, Pacific Research Labs, Vashon WA). The glenoid/sawbone assembly was then fixed to the table as the proposed humeral prostheses were abducted/adducted in the scapular plane.

The second stage enabled quantification of the effect of humeral/acromial impingement on ROM. The proposed humeral prostheses were prepared according to the prescribed technique in a left humeral sawbone (model 1051; Pacific Research Labs) as the humerus was abducted/adducted in the scapular plane about the glenoid/sawbone assembly.

A few points in the humeral implantation technique should be noted: the humeral osteotomy was conducted at the anatomic humeral neck, insertion of the humeral stem was accomplished after reaming the intramedullary canal and broaching the shape of the prosthesis (no spherical reaming of the proximal humerus was required), and finally, the humeral prosthesis was inserted in the humeral sawbone at about 20° retroversion.

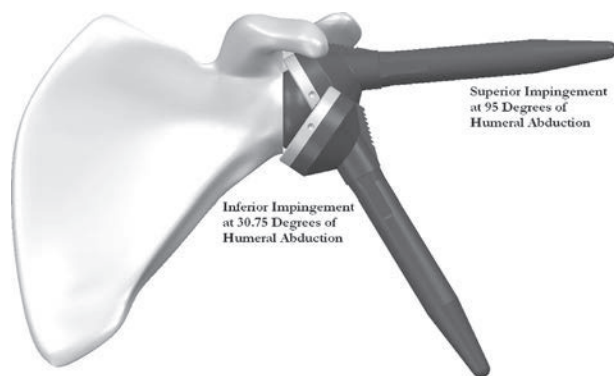


Figure 4 Inferior and superior impingement as determined by the geometric analysis for the Grammont reverse shoulder.

Results

The geometric computer analysis demonstrated that the Grammont reverse shoulder (ie, 155° neck angle, humeral constraint of 0.275, and 36- × 19-mm glenosphere with 0-mm distal overhang) impinged inferiorly and superiorly on the glenoid at 30.75° and 95° of humeral abduction thereby producing a total range of abduction/adduction of 64.25° with an average jump distance of 10.0 mm over that range (Figure 4).

By independently evaluating each design parameter the following linear relationships were elucidated: glenosphere thickness and ROM ($y = 5.3929x - 38.071$; $R^2 = 0.9995$), humeral liner constraint and ROM ($y = -224.59x + 126.05$; $R^2 = 0.9989$), glenosphere distal offset and ROM ($y = 4.0446x + 65.688$; $R^2 = 0.9744$), glenosphere diameter and jump distance ($y = 0.2333x - 0.0273$; $R^2 = 0.9999$), and humeral liner constraint and jump distance ($y = 46.861x - 4.523$; $R^2 = 0.9999$). Modifying the humeral neck angle did not show a linear correlation with jump distance or ROM; however, it did shift the points of impingement. To clarify, decreasing the humeral neck angle by 5° results in a 5° decrease in the inferior and superior impingement points.

Comparing the combined effect of each design parameter demonstrated that the largest improvements in ROM (from 58.75° to 108.5°) were achieved by distally offsetting the glenosphere from 0 to 6 mm and increasing glenosphere thickness from 18 to 24 mm, assuming a Grammont reverse shoulder design with a 36-mm glenosphere, 155° humeral neck angle, and a 0.275 humeral liner constraint. The next largest improvements in ROM (from 51.75° to 95.25°) were achieved by increasing glenosphere thickness from 18 to 24 mm while decreasing the humeral liner constraint from 0.300 to 0.250, assuming a Grammont reverse shoulder design with a 36-mm glenosphere, 155° humeral neck angle, and a 0-mm distal glenosphere offset. The next largest improvements in ROM (from 58.75° to 91.75°) were achieved by distally offsetting the glenosphere from 0 to 6 mm while decreasing the humeral liner constraint from

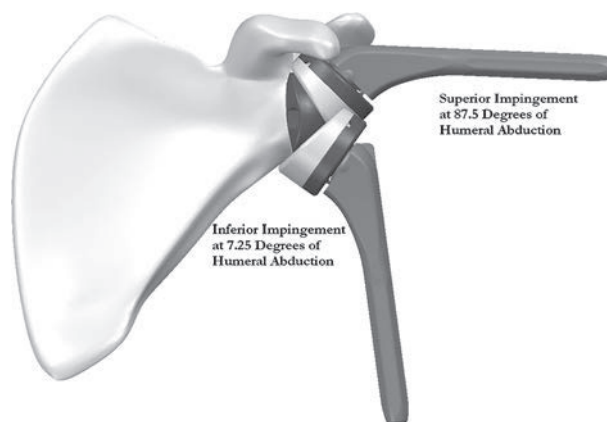


Figure 5 Inferior and superior impingement as determined by the geometric analysis for the proposed 38-mm reverse shoulder design.

0.300 to 0.250, assuming a Grammont reverse shoulder design with a 36- × 19-mm glenosphere and 155° humeral neck angle. Because independently varying the humeral neck angle had a negligible effect on ROM, the combined contribution of humeral neck angle on glenosphere thickness, glenosphere distal offset, and humeral liner constraint on ROM was also negligible.

The geometric computer analysis demonstrated that the proposed 38-, 42-, and 46-mm reverse shoulder designs impinged inferiorly and superiorly on the glenoid at 7.25°/87.5° (Figure 5), 1°/87.5° (Figure 6), and 0°/89.25° (Figure 7) of humeral abduction, having an average jump distance of 11.7, 13.5, and 14.1 mm over that range, respectively. Comparing the proposed 38-, 42-, and 46-mm designs with the Grammont demonstrated 24.9%, 34.6%, and 38.9% increases in ROM and 16.2%, 34.7%, and 36.3% increases in average jump distance over that range, respectively (Figure 8). The sawbone analysis demonstrated that the proposed 38-, 42-, and 46-mm designs impinged inferiorly and superiorly on the glenoid at 10°/100°, 1°/98°, and 0°/100°, respectively. When the contribution of the humerus (ie, humeral/acromial impingement) was included, the proposed 38-, 42-, and 46-mm designs impinged inferiorly on the glenoid while the humerus impinged superiorly on the acromion at 10°/85°, 1°/83°, and 0°/85°, respectively.

Discussion

The results of this study demonstrate that the design parameters of the Grammont reverse shoulder design are directly associated with the inferior glenoid impingement observed in this study and others (verified radiographically and clinically).^{13,15,21,26} From these observations, we conclude that the specific combinations of humeral neck angle, glenosphere geometry, and humeral liner geometry are interrelated but not necessarily optimized in the Grammont

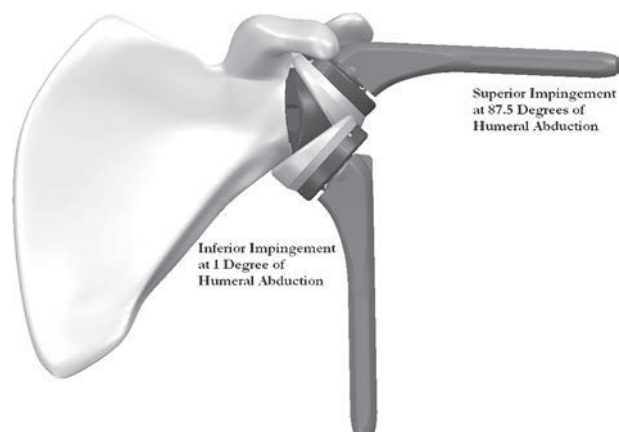


Figure 6 Inferior and superior impingement as determined by the geometric analysis for the proposed 42-mm reverse shoulder design.

design and, thus, make it susceptible to scapular notching and (potentially) dislocation via inferior impingement.

The results of this study further demonstrate that subtle changes in these design parameters can have dramatic effects on functionally relevant measurements. Selectively applying these design parameters in the proposed reverse shoulder designs demonstrated significant improvements in ROM (39%) and jump distance (36%) compared with the Grammont design. Inferior impingement can be minimized by decreasing humeral neck angle, decreasing humeral liner constraint, increasing glenosphere thickness, distally offsetting the glenosphere, or by any combination of the four. ROM can be increased by decreasing the humeral liner constraint, increasing the glenosphere thickness, distally offsetting the glenosphere, or by any combination of the three. Finally, jump distance can be increased by increasing the humeral constraint, increasing the glenosphere diameter, or by a combination of the two.

Applying the elucidated linear correlations for glenosphere thickness and humeral liner constraint derived from the Grammont design can predict increases in ROM of 14.3°, 27.4°, and 40.7° for the proposed 38-, 42-, and 46-mm reverse shoulder designs. These predicted values slightly overestimate the ROM improvements calculated by the geometric analysis (15.75°, 22.25°, and 25°, respectively) and slightly underestimate the ROM improvements calculated by the sawbone validation (25.75°, 32.75°, 35.75°, respectively). The primary difference between the predicted and actual values was due to the different points of superior impingement between the Grammont design and the proposed designs. The linear correlations were derived from the Grammont design, which has a flat-back glenoid baseplate. The proposed designs have a curved-back glenoid baseplate, the preparation of which removes less bone. When the glenosphere distal offset linear correlations are included, predicted improvements in ROM are overestimated for each design. This overestimation is

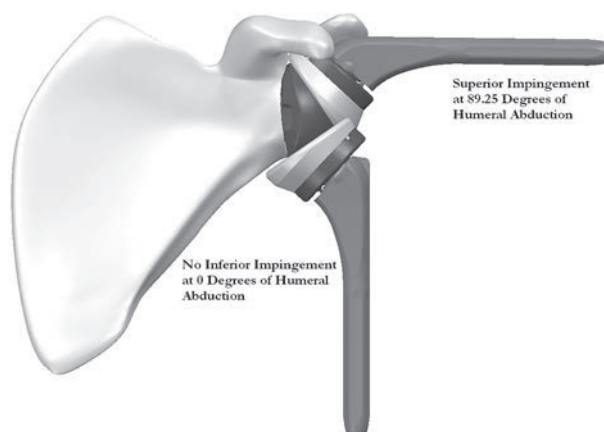


Figure 7 Inferior and superior impingement as determined by the geometric analysis for the proposed 46-mm reverse shoulder design.

primarily due to the measurement of ROM not recognizing values of less than 0° of abduction.

Limitations of this study are primarily related to scope and methodology. Regarding scope, the purpose of this study was to quantify the relationships between specific design parameters and measurements with functional application—no effort was made to identify a clinically successful range of these functional measurements. Future work should be conducted to:

1. identify the ideal position of the humerus that eliminates scapular notching, maximizes deltoid elongation without overstressing the acromion, and preserves the angular relationship of the deltoid and humerus (ie, the ideal “wrapping angle”)¹³ to improve stability;
2. identify the maximum torque that the glenoid can sustain in the long term without compromising fixation or stability; and
3. identify the minimum amount of jump distance required to resist dislocation.

The focus of this study was the 36-mm Grammont design. The 42-mm Grammont design was not included because it is used clinically in less than 10% of cases^{6,28,34} and because the specific humeral liner constraint was not known. However, if it is assumed that the liner constraint for the 42- × 22- mm design is the same as the 36- × 19-mm design, then the geometric analysis predicts identical impingement points and therefore ROM.

Regarding methodology, this geometric analysis was conducted in 2D and in 1 plane of motion; therefore, the results do not reflect the effect of anterior or posterior impingement that can occur during internal and external rotation. Future work should elucidate these relationships in 3D during different types of motion. In addition, the measurements of impingement obtained from the geometric analysis do not consider the effect of surrounding anatomic structures (ie, the acromion),^{15,21} soft tissue constraint, active motion, or the presence of osteophytes.²⁸

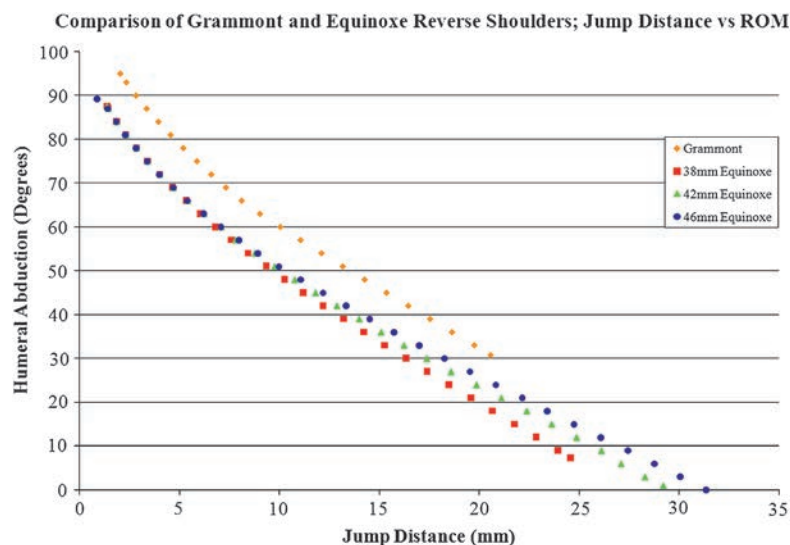


Figure 8 Comparison of range of motion and jump distance associated with the Grammont and the proposed reverse shoulder prostheses.

Furthermore, care should be taken in extrapolating these analytical ROM results to gross clinical motion because the clinical measurements include scapular motion. A comparison of the results from the sawbone validation demonstrates that acromial impingement does occur. Future work should evaluate the long-term effect of this impingement and also consider the role of anatomic variability on its occurrence; specifically, evaluating the role of variable greater tuberosity size, acromial geometry, humeral head diameter, and canal size on acromial impingement for varying amounts of humeral lateralization.

Despite these limitations, the results of our study are in general agreement with and are therefore validated by the results of Nyffeler et al²¹ and Gutiérrez et al.¹⁵ In a cadaveric study, Nyffeler et al quantified the points of impingement associated with different glenosphere implantation techniques during humeral abduction/adduction. When the 36-mm glenosphere was implanted as recommended by the manufacturer (ie, 0-mm distal offset), when the glenosphere was implanted flush with the inferior glenoid rim (ie, 2-mm distal offset), and when the glenoid baseplate was flush with the inferior glenoid rim (ie, 4-mm distal offset), Nyffeler et al observed inferior/superior impingement occurred on average at 25°/67°, 14°/68°, and 1°/81° of humeral abduction in the scapular plane, respectively. These ranges of inferior impingement generally agree with those calculated by our geometric analysis. Nyffeler et al observed lower values of superior impingement than those calculated by our analysis due to humeral impingement on the acromion.

In addition, the reductions in inferior impingement associated with each implantation technique are very similar: Nyffeler et al²¹ observed an 11° and 24° average improvement in inferior impingement by distally shifting the glenosphere by 2 and 4 mm, respectively. Our analysis calculated a 10.75° and 18.75° improvement in inferior impingement for each condition, respectively.

The overall ROM for the 4-mm distally shifted glenosphere was nearly identical: Nyffeler et al²¹ observed an average ROM of 80° and our analysis calculated 83°. Furthermore, we agree with the recommendations/conclusions by Nyffeler et al: “placing the glenosphere 2 mm to 4 mm more distally significantly improves abduction and adduction angles and may reduce the risk of inferior glenoid notching.” These recommendations are strengthened by Simovitch et al,²⁸ who demonstrated that scapular notching was less prevalent clinically when the peg–glenoid rim distance was smaller (indicative of glenosphere overhang). Simovitch et al observed in 77 shoulders that the mean peg–glenoid rim distance was 20.1 mm for shoulders without inferior notching and 24.7 mm for shoulders with inferior notching.

Gutiérrez et al¹⁵ conducted a sawbones ROM analysis comparing the DJO reverse shoulder designs (DJO Surgical, Austin, TX) with the Grammont during simulated humeral abduction/adduction in the scapular plane. When the 36-mm Grammont glenosphere was implanted as recommended by the manufacturer (ie, 0-mm distal offset), Gutiérrez et al observed inferior/superior impingement on average at 32.3°/86.7°. This point of inferior impingement is nearly identical with the 30.75° calculated by our analysis. Similar to the Nyffeler et al²¹ study, Gutiérrez et al observed slightly lower values of superior impingement due to humeral impingement on the acromion. Similarities in these reported Grammont inferior impingement values with those of our study suggest the role of the humeral osteotomy is negligible on inferior impingement but may be important in superior impingement via contact of the tuberosities on the acromion.

Comparing the DJO reverse shoulder designs, Gutiérrez et al¹⁵ identified a linear relationship between lateralizing the center of rotation (COR) and ROM ($ROM = 3.26(COR) + 61.8$; $R^2 = 0.962$). Our geometric analysis also demonstrates a linear correlation between COR (ie, increasing the

glenosphere thickness relative to diameter) and ROM. By converting glenosphere thickness to COR, we predict a linear correlation of $ROM = 5.3929(COR) + 59$; $R^2 = 0.999$. Although this linear correlation is similar, Gutiérrez et al predicted a slightly greater y intercept due to a variation in implantation methodology: Gutiérrez et al “removed the inferior edge of the glenoid” when implanting the DJO prostheses. Removing this bone effectively prenotches the glenoid and results in a more medial inferior impingement point, thereby increasing the overall ROM. Gutiérrez et al predicted a smaller slope due to a variation in measurement of superior impingement. They explained that several of the more laterally offset components impinged first on the acromion rather than the superior glenoid, thus truncating the overall ROM for the more laterally offset components.

We agree with mechanisms identified by Gutiérrez et al concerning inferior impingement: “if the center of rotation was further away from the scapula the proximal humerus and humeral socket had more clearance before impingement....”¹⁵ However, we temper their recommendations concerning more laterally offset designs because future work is needed to demonstrate that long-term glenoid fixation can be achieved at these elevated torques.

Conclusions

Linear relationships between several design parameters as well as functional measurements related to impingement and dislocation have been quantified. Applying these relationships in concert can provide substantial improvements in ROM and jump distance without removing the inferior glenoid or lateralizing the center of rotation, or both. Future reverse shoulder designs should make an effort to maximize ROM and stability while conserving bone stock and minimizing impingement and torque on the glenoid.

References

- Ahir SP, Walker PS, Squire-Taylor CJ, Blunn GW, Bayley JI. Analysis of glenoid fixation for a reversed anatomy fixed-fulcrum shoulder replacement. *J Biomech* 2004;37:1699-708.
- Arntz CT, Jackins S, Matsen FA 3rd. Prosthetic replacement of the shoulder for treatment of defects in the rotator cuff and the surface of the glenohumeral joint. *J Bone Joint Surg Am* 1993;75:485-91.
- Bayley I, Kessel L. The Kessel total shoulder replacement. In: Bayley I, Kessel L, editors. *Shoulder surgery*. New York: Springer; 1982. p. 160-4.
- Bohsali KI, Wirth MA, Rockwood CA Jr. Complications of total shoulder arthroplasty. *J Bone Joint Surg Am* 2006;88:2279-92.
- Boileau P, Watkinson DJ, Hatzidakis AM, Balg F. Grammont reverse prosthesis: design, rationale, and biomechanics. *J Shoulder Elbow Surg* 2005;14:147S-61.
- Boileau P, Watkinson D, Hatzidakis AM, Hovorka I, Neer Award 2005: the Grammont reverse shoulder: results in cuff tear arthritis, fracture sequelae, and revision arthroplasty. *J Shoulder Elbow Surg* 2006;15:527-40.
- Boualhia A, Edwards TB, Walch G, Baratta RV. Early results of a reverse design prosthesis in the treatment of arthritis of the shoulder in elderly patients with a large rotator cuff tear. *Orthopaedics* 2002;25:129-33.
- Broström LA, Wallensten R, Olsson E, Anderson D. The Kessel prosthesis in total shoulder arthroplasty. *Clin Orthop Relat Res* 1992; 257:155-60.
- Buechel FF, Pappas MJ, DePalma AF. “Floating socket” total shoulder replacement: anatomical, biomechanical, and surgical rationale. *J Biomed Mat Res* 1978;12:89-114.
- Clayton ML, Ferlic DC, Jeffers PD. Prosthetic arthroplasties of the shoulder. *Clin Orthop Relat Res* 1982;164:184-91.
- De Buttet A, Bouchon Y, Capon D, Delfosse J. Grammont shoulder arthroplasty for osteoarthritis with massive rotator cuff tears: a report of 71 cases. *J Shoulder Elbow Surg* 1997;6:197.
- Delloye C, Joris D, Colette A, Eudier A, Dubuc JE. Mechanical complications of total shoulder inverted prostheses. *Rev Chir Orthop Reparatrice Appar Mot* 2002;88:410-4.
- De Wilde LF, Audenaert EA, Berghs BM. Shoulder prostheses treating cuff tear arthropathy: a comparative biomechanical study. *J Orthop Res* 2004;22:1222-30.
- Field LD, Dines DM, Zabinski SJ, Warren RF. Hemiarthroplasty of the shoulder for rotator cuff arthropathy. *J Shoulder Elbow Surg* 1997;6:1823.
- Gutiérrez S, Levy JC, Lee WE 3rd, Keller TS, Maitland ME. Center of rotation affects abduction range of motion of reverse shoulder arthroplasty. *Clin Orthop Relat Res* 2007;458:78-82.
- Guery J, Favard L, Sirveaux F, Oudet D, Mole D, Walch G. Reverse total shoulder arthroplasty. *J Bone Joint Surg Am* 2006;88:1742-7.
- Katzer A, Sickelmann F, Seemann K, Loefer JF. Two-year results after exchange shoulder arthroplasty using inverse implants. *Orthopedics* 2004;27:1165-7.
- Kölbel R, et al. Stabilization of shoulders with bone and muscle defects in shoulder replacement. In: Kolbel R, Helbig B, Blauth W, editors. *Shoulder replacement*. Berlin, Heidelberg: Springer-Verlag; 1987. p. 189-95.
- Neer CS. *Shoulder reconstruction*. Philadelphia: WB Saunders Co; 1990. p. 146-50.
- Neyton L, Boileau P, Nové-Josserand L, Edwards TB, Walch G. Glenoid bone grafting with a reverse design prosthesis. *J Shoulder Elbow Surg* 2007;16:71S-8.
- Nyffeler RW, Werner CM, Gerber C. Biomechanical relevance of glenoid component positioning in the reverse Delta III total shoulder prosthesis. *J Shoulder Elbow Surg* 2005;14:524-8.
- Pollock RG, Deliz ED, McIlveen SJ, Flatow EL, Bigliani LU. Prosthetic replacement in rotator cuff deficient shoulders. *J Shoulder Elbow Surg* 1992;1:173-86.
- Reeves B, Jobbins B, Flowers M. Biomechanical problems in the development of a total shoulder endoprosthesis. *J Bone Joint Surg Br* 1972;54:193.
- Reeves B, Jobbins B, Dowson D, Wright V. A total shoulder endoprosthesis. *Eng Med* 1974;1:64-7.
- Rittmeister M, Kerschbaumer F. Grammont reverse total shoulder arthroplasty in patients with rheumatoid arthritis and nonreconstructable rotator cuff lesions. *J Shoulder Elbow Surg* 2001;10:17-22.
- Roberts CC, Ekelund AL, Renfree KJ, Liu PT, Chew FS. Radiologic assessment of reverse shoulder arthroplasty. *Radiographics* 2007;27: 223-35.
- Sanchez-Sotelo J, Cofield RH, Rowland CM. Shoulder hemiarthroplasty for glenohumeral arthritis associated with severe rotator cuff deficiency. *J Bone Joint Surg Am* 2001;83:1814-22.
- Simovitch RW, Zumstein MA, Lohri E, Helmy N, Gerber C. Predictors of scapular notching in patients managed with the Delta III reverse total shoulder replacement. *J Bone Joint Surg Am* 2007; 89:588-600.
- Sirveaux F, Favard L, Oudet D, Huquet D, Walch G, Molé D. Grammont inverted total shoulder arthroplasty in the treatment of

- glenohumeral osteoarthritis with massive rupture of the cuff. *J Bone Joint Surg Br* 2004;86:388-95.
30. Swanson AB, de Groot Swanson G, Sattel AB, Cendo RD, Hynes D, Jar-Ning W. Bipolar implant shoulder arthroplasty. long-term results. *Clin Orthop Relat Res* 1989;249:227-47.
 31. Vanhove B, Beugnies A. Grammont's reverse shoulder prosthesis for rotator cuff arthropathy. A retrospective study of 32 cases. *Acta Orthop Belg* 2004;70:219-25.
 32. Vretos BC, Wallace WA, Neumann L. Bipolar hemiarthroplasty of the shoulder for the elderly patient with cuff tear arthropathy. *J Bone Joint Surg Br* 1998;80:106.
 33. Warner JP, Iannotti JP, Flatow EL. Complex and revision problems in shoulder surgery. Philadelphia: Lippincott Williams and Wilkins; 2005. p. 506.
 34. Werner CM, Steinmann PA, Gilbert M, Gerber C. Treatment of painful pseudoparesis due to irreparable rotator cuff dysfunction with the Delta III reverse ball and socket total shoulder prosthesis. *J Bone Joint Surg Am* 2005;87:1476-86.
 35. Williams GR Jr, Rockwood CA Jr. Hemiarthroplasty in rotator cuff deficient shoulders. *J Shoulder Elbow Surg* 1996;5:362-7.
 36. Worland RL, Jessup DE, Arredondo J, Warburton KJ. Bipolar shoulder arthroplasty for rotator cuff arthropathy. *J Shoulder Elbow Surg* 1997; 6:512-5.
 37. Wretenberg PF, Wallensten R. The Kessel total shoulder arthroplasty. A 13- to 16-year retrospective follow-up. *Clin Orthop Relat Res* 1999; 365:100-3.
 38. Zuckerman JD, Scott AJ, Gallagher MA. Hemiarthroplasty for cuff tear arthroplasty. *J Shoulder Elbow Surg* 2000;9:169-72.



ELSEVIER

Outcomes of reverse total shoulder arthroplasty in a senior athletic population



Ryan W. Simovitch, MD^{a,*}, Berenice K. Gerard, MS^a, Jordon A. Brees, PA-C^a, Robert Fullick, MD^b, Justin C. Kearsse, MD^a

^a*Palm Beach Orthopaedic Institute, Palm Beach Gardens, FL, USA*

^b*Division of Orthopedic Surgery, Ironman Sports Medicine Institute, The University of Texas, Health Science Center at Houston, Houston, TX, USA*

Background: This study evaluated the clinical and radiographic outcomes of reverse total shoulder arthroplasty (RTSA) in a senior athletic population playing both low- and high-impact sports.

Materials and methods: We evaluated 41 RTSAs performed in 40 patients who continued to play both low- and high-impact sports after surgery. The mean age was 73 years, and the mean follow-up period was 43 months, with a minimum of 35 months. Clinical and radiographic outcomes were examined.

Results: Ninety-five percent of patients indicated that they were able to return to sports at the same level as before surgery or at a higher level, and only 13% reported increased pain after playing their sport after undergoing an RTSA. The median American Shoulder and Elbow Surgeons score improved from 31 preoperatively to 72 postoperatively ($P < .001$). The median Constant score improved from 25 preoperatively to 83 postoperatively ($P < .001$). The median Subjective Shoulder Value improved from 27% preoperatively to 90% postoperatively ($P < .001$), and the median visual analog scale score improved from 7.2 preoperatively to 1.1 postoperatively ($P < .001$). The overall complication rate was 7%. One zone of lucency was noted in 17% of humeral stems, with 1 case of early subsidence but no cases with loosening at final follow-up. The glenoid notching rate was 7%, with no cases of glenoid subsidence, lucency, or loosening.

Conclusion: RTSA in senior athletes can be safely performed with good clinical results. No prominent mode of mechanical or clinical failure has been identified with short-term follow-up.

Level of evidence: Level IV, Case Series, Treatment Study.

© 2015 Journal of Shoulder and Elbow Surgery Board of Trustees.

Keywords: Reverse shoulder arthroplasty; athlete; senior; sports; complications

Reverse total shoulder arthroplasty (RTSA) was introduced by Paul Grammont in the 1980s and gained popularity in the treatment of cuff tear arthropathy. Since then, the

indications for RTSA have been expanded to include the treatment of massive irreparable rotator cuff tears, rotator cuff tears with pseudoparalysis, inflammatory and non-inflammatory arthritis, osteoarthritis in the octogenarian with an at-risk rotator cuff, fractures, and tumors.^{3,8,9,11,18-21}

Historically, RTSA has been seen as a salvage operation, used to gain pain relief and restoration of overhead function in low-demand older (aged >70 years) patients. However, as the indications for RTSA have been expanded, so too have the

Institutional review board was received for this study (Western IRB CR09-005).

*Reprint requests: Ryan W. Simovitch, MD, Palm Beach Orthopaedic Institute, 4215 Burns Rd, Palm Beach Gardens, FL 33410, USA.

E-mail address: floridashoulder@gmail.com (R.W. Simovitch).

demographic characteristics of patients in whom RTSA prostheses are considered. Surgeons continue to implant RTSA prostheses in younger patients and patients with higher activity levels.^{7,12,16,17} There is a lack of consensus on the appropriate activity level and return to sports after RTSA. We are not aware of any study in the peer-reviewed literature that specifically evaluates the clinical and radiographic outcomes of RTSA in a senior athletic population that places increased stress and demand on the prosthetic shoulder.

We hypothesized that senior athletic higher-demand patients would have improvements in function and pain relief similar to historically low-demand patients reported in the literature without any increase in radiographic loosening or mechanical complications. The purpose of this study is to report the short-term and midterm clinical and radiographic outcomes of RTSA in a senior athletic high-demand population.

Materials and methods

We reviewed the records of 255 RTSA cases performed in 245 patients between 2007 and 2012. All operations were performed by a single high-volume, fellowship-trained shoulder surgeon (R.W.S.). We identified 67 patients (70 RTSA cases) who indicated that they played a high- or low-impact sport^{10,14} or engaged in strenuous athletic activity before undergoing RTSA. Forty-three of these patients (44 RTSA cases) indicated a return to sports and hence high-demand use of their prosthetic shoulder after RTSA. Three patients were lost to follow-up before their 2-year evaluation. This yielded a study group of 41 RTSA prostheses in 40 patients. Thus, the inclusion criteria included patients who underwent an RTSA, a return to sports after surgery, and greater than 2 years' follow-up.

In all cases, the RTSA was performed through the deltopectoral interval. Each case was performed with an RTSA prosthesis characterized by a medialized center of rotation; a laterally offset humerus; a proximal grit-blast humeral stem; and a concave-backside, oblong glenoid baseplate secured by a grit-blast bone cage with between 3 and 6 compression, variable-angle, locking screws (Equinox; Exactech, Gainesville, FL, USA). The subscapularis was uniformly not repaired. Various glenosphere and humeral tray sizes were used to maximize stability and intraoperative range of motion (ROM). The components used included 1 extended-cage baseplate, 2 superiorly augmented baseplates, 3 posteriorly augmented baseplates, 35 standard baseplates, two 46-mm glenospheres, fifteen 42-mm glenospheres, twenty-two 38-mm glenospheres, and two 38-mm expanded (+4 mm lateral offset) glenospheres. All of the 41 polyethylene trays but 1 were nonconstrained. Stems were either press fit or cemented with Cemex antibiotic-impregnated cement (Tecres SPA, Verona, Italy) depending on radiographic and intraoperative considerations. Twenty-four stems were cemented, and 17 were press fit. Each stem was placed at between 20° and 25° of retroversion. Postoperative immobilization in an abduction sling, along with passive ROM and isometric exercises, was prescribed for 4 weeks. Patients progressed through active ROM and strengthening at 6 weeks

and 12 weeks, respectively. A return to sports was permitted at 4 months postoperatively.

Variables recorded for each patient included age, sex, hand dominance, time of follow-up, shoulder diagnosis, whether the surgical procedure was a primary or revision operation, previous surgical procedures, procedures performed concomitantly with RTSA, size of the stem and glenosphere used, type of glenoid baseplate used, height and constraint of the polyethylene used, and whether the humeral stem was cemented or press fit. All patients underwent both clinical and radiographic evaluation. Evaluation took place preoperatively and then 2 weeks, 6 weeks, 3 months, 6 months, and 1 year after surgery, as well as every subsequent year thereafter. In the event that any particular follow-up appointment was missed, evaluation was resumed at the next appropriate time point.

Clinical evaluation included the recording of each patient's Subjective Shoulder Value and visual analog scale score. The recorded ROM included active flexion, active abduction, active external rotation with the shoulder adducted, and active internal rotation with the shoulder adducted. Internal rotation was assigned a numeric value beginning with 0 for reaching the anterior superior iliac spine, 1 for reaching the posterior iliac spine, and so on, with T10 assigned the value of 9. This helped with statistical analysis. Strength was recorded in abduction using a digital dynamometer (Chatillon, Largo, FL, USA). In addition, American Shoulder and Elbow Surgeons (ASES) and Constant scores were recorded at each visit.⁵ Sports activity was recorded including frequency; level of sport compared with preoperative abilities (better, same, or worse); time at which the patient reported being able to return to sports after surgery; and whether the patient had increased pain after playing a sport. Complication type, frequency, and treatment were also recorded.

Radiographic evaluation was performed at each visit and included anteroposterior, axillary lateral, and scapular-Y radiographic views. The radiographs were assessed for humeral stem lucencies according to the classification of Gruen adapted to the humerus¹⁵; subsidence; and loosening, which was determined if 3 or more zones of greater than 2 mm of lucency were identified. In addition, radiographs were assessed for signs of inferior scapular notching using the Nerot classification,¹⁹ glenoid lucency, glenoid subsidence, and osteophyte formation along the scapular neck and glenoid rim. Radiographs were also evaluated for heterotopic ossification, stress shielding of the humerus, and tuberosity resorption.

Statistical evaluation was performed using Wizard (version 1.5.2; Boston, MA, USA). Preoperative and postoperative values were compared using a paired *t* test.

Results

Of the 67 patients who played a sport before undergoing RTSA, 40 (60%) reported a return to sports after surgery. These 40 patients (41 RTSA prostheses) are the focus of the reported results. The mean age of these patients was 73 ± 7.2 years (range, 61-88 years). There were 25 women and 15 men. Of the RTSAs, 30 were performed on the dominant shoulder and 11 on the nondominant side. One patient underwent staged bilateral RTSA procedures. The frequency of diagnosis is reported in Table I. The mean follow-up period was 43 ± 12 months (range, 35-63 months). The frequency of sports played after surgery is listed in Table II.

Table I Frequency of diagnosis

Diagnosis	Data
OA/RCT	15 (36%)
Massive irreparable RCT	12 (28%)
Cuff tear arthropathy	5 (12%)
OA/age >80 y (at-risk cuff)	3 (7%)
Failed TSA	2 (5%)
Acute fracture	2 (5%)
Fracture malunion	2 (5%)
OA/type C glenoid	1 (2%)

OA, osteoarthritis; RCT, rotator cuff tear; TSA, total shoulder arthroplasty.

Table II Frequency of sport played

Sport played	%
Golf	75
Swimming	29
Water aerobics	24
Deep sea fishing	21
Skeet shooting, hunting, firearm sports	21
Weight lifting	18
Softball	11
Tennis	11
Table tennis	7
Scuba diving	7
Racquetball	5
Surfing	2
Water skiing	2

Seventy-three percent of patients played more than 1 sport.

Among the 40 patients who returned to sport, the mean reported frequency of participation was 2.7 ± 1.2 (range, 2-7) times per week. Of these patients, 12 (30%) indicated they were able to perform their sporting activities at a higher level, 2 (5%) indicated they were worse, and 26 (65%) reported no change in ability compared with before undergoing RTSA. Regarding pain, 35 patients (87%) reported no increase in pain in the operative shoulder after sports participation whereas 5 patients (13%) reported increased pain. Thirty patients (73%) reported playing more than 1 sport.

Eleven patients had undergone previous surgical procedures and hence were revision cases. Eight had undergone a single prior rotator cuff repair, of which 5 were arthroscopic and 3 were open. Two patients had undergone a previous anatomic shoulder replacement, whereas one patient had undergone shoulder resurfacing and 2 rotator cuff repairs previously. In 2 patients, a concomitant procedure was performed at the time of RTSA, comprising 1 latissimus dorsi tendon transfer for a Hornblower's sign and 1 case of glenoid bone grafting for a contained glenoid defect during revision for an anatomic total shoulder arthroplasty (TSA).

Table III Clinical results

Outcome measured	Preoperative	Postoperative	P value
Subjective Shoulder Value, %	27 ± 4.3	90 ± 4	<.001
Visual analog scale score	7.2 ± 0.5	1.1 ± 0.5	<.001
Constant score	25 ± 1.9	84 ± 1.7	<.001
ASES score	31 ± 1.9	72 ± 4.5	<.001
Flexion, °	78 ± 16	152 ± 12	<.001
Abduction, °	67 ± 14.6	148 ± 11.6	<.001
External rotation, °	26 ± 5.2	44 ± 5.7	<.001
Internal rotation	PSIS	L4	<.001
Strength, lb	3.1 ± 1.6	7.4 ± 2.8	.008

ASES, American Shoulder and Elbow Surgeons; PSIS, posterior superior iliac spine.

Data are presented as mean \pm standard deviation.

Preoperative and postoperative values for clinical outcomes were compared. These clinical results are summarized in Table III.

At final follow-up, 7 of the 41 stems (17%) showed lucencies. In those stems with lucencies, the lucency was confined to only 1 zone. There was 1 case of stem subsidence (4 mm) of a press-fit stem, but this was stable at 14 months. There were no cases of stem loosening at final follow-up. Moreover, there were no cases of stress shielding of the humerus. One shoulder showed tuberosity resorption, although this was a fracture stem used for a 4-part fracture and the tuberosity was repaired during the index surgical procedure. At final follow-up, there were 3 notches (7%). Two were grade 1, and one was grade 2. There were no cases of glenoid lucency, loosening, or subsidence. Three shoulders (7%) showed an inferior glenoid traction spur, and 6 shoulders (15%) showed heterotopic ossification.

There were complications in 3 of the 42 RTSAs performed (7%) and 2 reoperations (5%). One type II acromion stress fracture⁶ noted 6 months postoperatively was treated nonoperatively with sling immobilization. One postoperative infection with incidental intraoperative cultures noted to be positive for *Propionibacterium acnes* was treated with early irrigation and debridement, along with polyethylene exchange and retention of humeral and glenoid components. This occurred in 1 of the 2 cases that underwent revision of an anatomic total shoulder to an RTSA prosthesis. One postoperative dislocation occurred 5 days after surgery during toileting activities. This case was treated by revision with an open reduction and exchange of the polyethylene to a constrained component.

Discussion

Historically, RTSA has been performed in a low-demand older patient population with good results. Recently, however, there has been interest in examining subsets of

patients to identify whether results differ between groups. This has been demonstrated in a series of studies recently examining the results of RTSA in a younger population.^{7,16,17} Only one study to date has examined the outcomes of RTSA in senior athletes: Labriola and Edwards¹² reported on 4 senior athletes with over 2 years of follow-up, 3 of whom returned to their preinjury sports and half of whom faced limitations not present previously. In our study of 67 patients who played sports before undergoing RTSA, 40 were able to return to athletics. Unlike in the small series reported by Labriola and Edwards, only 2 of the 40 patients in our study reported a decline and faced limitations in their ability to play sports after surgery, with 95% of senior athletes returning to the same level or at a better level. This group of senior athletes enjoyed very good clinical outcomes on par with previous studies of low-demand individuals and likely heterogeneous populations.^{3,7,8,16-21} We believe that the postoperative mean Constant score in this study exceeds that reported in other series because of the homogeneous athletic population that was studied. In our experience, these athletic individuals are very functional and motivated patients who require very good ROM to return to sports and self-report higher subjective clinical values. They generally appear to have better muscle conditioning than low-demand patients.

As the population ages and sports-inclined seniors undergo RTSA, surgeons will increasingly have to counsel patients regarding the risk of returning to sports. In the current literature, there is no consensus on what sports are safe to return to after RTSA. Magnussen et al¹⁴ reported on an international survey of members of ASES and the European Society for Surgery of the Shoulder and Elbow (SECEC) regarding return to sports after RTSA. There was no clear unanimity on return to sports in general, although most surgeons allowed a return to sports with light upper extremity involvement. The recommended timing of return to sports postoperatively also was variable. Golant et al¹⁰ surveyed 310 members of ASES on their allowance of anatomic TSA and RTSA patients to return to sports after surgery. They stratified sports level into low-impact, high-impact, contact, and non-upper extremity sports. Fifty-nine percent and twenty percent of surgeons allowed their anatomic TSA patients to return to low-impact and high-impact sports without limitations, respectively, whereas 26% and 4% of surgeons allowed their RTSA patients to return to low-impact and high-impact sports without limitations, respectively. It has also been documented that RTSA patients self-report an activity level on par with that of anatomic TSA and hemiarthroplasty patients.¹³ It is therefore plausible that without a consensus on the types of sports and the activity level allowed after RTSA, this void is being filled by patient self-direction toward a higher activity level and participation in sports with which surgeons might feel uncomfortable.

Concern regarding activity level exists because of the biomechanics of the RTSA prosthesis. The RTSA

prosthesis is biomechanically different than an anatomic TSA or hemiarthroplasty prosthesis. It is a semiconstrained joint that experiences unique forces at the prosthetic joint and prosthesis-bone interface. In particular, concerns exist regarding long-term fixation, accelerated polyethylene wear, late instability, and deltoid fatigue or failure, especially in high-demand and athletically inclined patients. Several studies have examined in vivo glenohumeral joint loads using instrumented prostheses. However, these have only been performed for hemiarthroplasty patients, and testing has only been conducted regarding activities of daily living.^{1,2,22} Although similar investigations into the joint forces encountered by an RTSA prosthesis during sports would be enlightening, stringent regulations make this testing very difficult to perform. Therefore, clinical and radiographic studies remain the most practical way to evaluate standard guidelines and practice recommendations.

In our study, 17% of the humeral stems showed lucency. However, none of the stems developed loosening. There were no cases of glenoid lucency or loosening, and the notching rate was only 7%. We assume that osseous integration of the glenoid baseplate occurred because, with a minimum of 2 years' follow-up, no evidence of glenoid baseplate loosening or failure was found. Despite complications occurring in 7% of cases, there were no unusual modes of failure. This complication rate does not exceed that reported in the literature for other series.⁴

There are several limitations to our study. First, our length of follow-up was, on average, 43 months, with a minimum of 35 months. Favard et al⁸ have shown a decline in Constant scores and radiographic outcomes over the course of 10 years, so our outcomes may deteriorate with further follow-up. Second, the sports represented are heavily weighted toward golf and swimming, with fewer patients playing tennis and participating in high-impact sports. Thus, it is difficult to conclude that there will not be an alternate mode of failure or timeline of failure with more experience evaluating high-impact sports compared with low-impact sports. A larger sample size will be necessary to evaluate each sport for relative risk. Finally, we did not attempt to quantify patients' skill level regarding sports participation, and this may affect clinical and radiographic outcomes.

Despite no clear consensus in the literature regarding the acceptable activity level after RTSA, we believe it is relatively safe for a senior athlete to return to non-contact, low- and high-impact sports based on short-term and midterm follow-up. In this period, no radiographic or clinical modes of failure were identified. However, it is too soon to develop guidelines and standards of practice because this will require far larger series with stratification according to specific sport type, level, and frequency. In addition, biomechanical testing of the RTSA prostheses with simulated sports-specific forces should be performed to understand potential short- and long-term modes of failure.

Conclusion

RTSA in senior athletes results in significant clinical improvement without evidence of radiographic decline or failure with short-term follow-up. Although there are increased forces generated on the shoulder with low- and high-demand sports, there is no identifiable unique mode of failure to date. However, long-term studies with stratification of specific sports must be completed to identify relative risks of sports and activities to provide appropriate guidelines to patients after surgery.

Acknowledgments

Jaclyn Bovarnick assisted in data acquisition and compilation.

Disclaimer

The authors, their immediate families, and any research foundations with which they are affiliated have not received any financial payments or other benefits from any commercial entity related to the subject of this article.

References

- Bergmann G, Graichen F, Bender A, Kaab M, Rohlmann A, Westerhoff P. In vivo glenohumeral contact forces—measurements in the first patient 7 months postoperatively. *J Biomech* 2007;40:2139-49. <http://dx.doi.org/10.1016/j.jbiomech.2006.10.037>
- Bergmann G, Graichen F, Bender A, Rohlmann A, Halder A, Beier A, et al. In vivo gleno-humeral joint loads during forward flexion and abduction. *J Biomech* 2011;44:1543-52. <http://dx.doi.org/10.1016/j.jbiomech.2011.02.142>
- Boileau P, Gonzalez JF, Chuinard C, Bicknell R, Walch G. Reverse total shoulder arthroplasty after failed rotator cuff surgery. *J Shoulder Elbow Surg* 2009;18:600-6. <http://dx.doi.org/10.1016/j.jse.2009.03.011>
- Cheung E, Wills M, Walker M, Clark R, Frankle MA. Complications in reverse total shoulder arthroplasty. *J Am Acad Orthop Surg* 2011; 19:439-49.
- Constant CR, Murley AH. A clinical method of functional assessment of the shoulder. *Clin Orthop Relat Res* 1987:160-4.
- Crosby LA, Hamilton A, Twiss T. Scapula fractures after reverse total shoulder arthroplasty: classification and treatment. *Clin Orthop Relat Res* 2011;469:2544-9. <http://dx.doi.org/10.1007/s11999-011-1881-3>
- Ek ET, Neukom L, Cantanzaro S, Gerber C. Reverse total shoulder arthroplasty for massive irreparable rotator cuff tears in patients younger than 65 years old: results after five to fifteen years. *J Shoulder Elbow Surg* 2013;22:1199-208. <http://dx.doi.org/10.1016/j.jse.2012.11.016>
- Favard L, Levigne C, Nerot C, Gerber C, De Wilde L, Mole D. Reverse prosthesis in arthropathies with cuff tear: are survivorship and function maintained over time? *Clin Orthop Relat Res* 2011;469:2469-75. <http://dx.doi.org/10.1007/s11999-011-1833-y>
- Frankle M, Siegal S, Pupello D, Saleem A, Mighell M, Vasey M. The Reverse Shoulder Prosthesis for glenohumeral arthritis associated with severe rotator cuff deficiency. A minimum two-year follow-up study of sixty patients. *J Bone Joint Surg Am* 2005;87:1697-705. <http://dx.doi.org/10.2106/JBJS.D.02813>
- Golant A, Christoforou D, Zuckerman JD, Kwon YW. Return to sports after shoulder arthroplasty: a survey of surgeons preferences. *J Shoulder Elbow Surg* 2012;21:554-60. <http://dx.doi.org/10.1016/j.jse.2010.11.021>
- Guery J, Favard L, Sirveaux F, Oudet D, Mole D, Walch G. Reverse total shoulder arthroplasty: survivorship analysis of eighty replacements followed for five to ten years. *J Bone Joint Surg Am* 2006; 88:1742-7. <http://dx.doi.org/10.2106/JBJS.E.00851>
- Labriola JE, Edwards TB. Reverse total shoulder arthroplasty in the senior athlete. *Op Tech Sports Med* 2008;16:43-9. <http://dx.doi.org/10.1053/j.otsm.2008.08.007>
- Lawrence TM, Ahmadi S, Sanchez-Sotelo J, Cofield RH. Patient reported activities after reverse shoulder arthroplasty: part II. *J Shoulder Elbow Surg* 2012;21:1464-9. <http://dx.doi.org/10.1016/j.jse.2011.11.012>
- Magnussen RA, Mallon WJ, Williams WJ, Moorman CT. Long term activity restrictions after shoulder arthroplasty: an international survey of experienced shoulder surgeons. *J Shoulder Elbow Surg* 2011;20: 281-9. <http://dx.doi.org/10.1016/j.jse.2010.07.021>
- Melis B, DeFranco M, Ladermann A, Mole D, Favard L, Nerot C, et al. An evaluation of the radiological changes around the Grammont reverse geometry shoulder arthroplasty after eight to 12 years. *J Bone Joint Surg Br* 2011;93:1240-6. <http://dx.doi.org/10.1302/0301-620x.93B9.25926>
- Muh SJ, Streit JJ, Wanner JP, Lenarz CJ, Shishani Y, Rowland DY, et al. Early follow-up of reverse total shoulder arthroplasty in patients sixty years of age or younger. *J Bone Joint Surg Am* 2013;95:1877-83. <http://dx.doi.org/10.2106/JBJS.L.10005>
- Sershon RA, Van Thiel GS, Lin EC, McGill KC, Cole BJ, Verma NN, et al. Clinical outcomes of reverse total shoulder arthroplasty in patients aged younger than 60 years. *J Shoulder Elbow Surg* 2014;23: 395-400. <http://dx.doi.org/10.1016/j.jse.2013.07.047>
- Sirveaux F, Favard L, Oudet D, Huquet D, Walch G, Mole D. Grammont inverted total shoulder arthroplasty in the treatment of glenohumeral osteoarthritis with massive rupture of the cuff. Results of a multicenter study of 80 shoulders. *J Bone Joint Surg Br* 2004;86: 388-95. <http://dx.doi.org/10.1302/0301-620X.86B3.14024>
- Valenti PH, Boutens D, Nerot C. Delta 3 reverse prosthesis for osteoarthritis with massive rotator cuff tear: long term results (>5 years). In: Walch G, Boileau P, Mole D, editors. 2000 Protheses d'épaule ... recul de 2 a 10 ans. Paris: Sauramps Medical; 2001. p. 253-9.
- Wall B, Nové-Josserand L, O'Connor DP, Edwards TB, Walch G. Reverse total shoulder arthroplasty: a review of results according to etiology. *J Bone Joint Surg Am* 2007;89:1476-85. <http://dx.doi.org/10.2106/JBJS.F.00666>
- Werner CM, Steinmann PA, Gilbert M, Gerber C. Treatment of painful pseudoparesis due to irreparable rotator cuff dysfunction with the Delta III reverse-ball-and-socket total shoulder prosthesis. *J Bone Joint Surg Am* 2005;87:1476-86. <http://dx.doi.org/10.2106/JBJS.D.02342>
- Westerhoff P, Graichen F, Bender A, Halder A, Beier A, Rohlmann A, et al. In vivo measurement of shoulder joint loads during activities of daily living. *J Biomech* 2009;42:1840-9. <http://dx.doi.org/10.1016/j.jbiomech.2009.05.035>



The incidence of radiographic aseptic loosening of the humeral component in reverse total shoulder arthroplasty



Gregory Gilot, MD^a, Andres M. Alvarez-Pinzon, MD, PhD^{a,*}, Thomas W. Wright, MD^b, Pierre-Henri Flurin, MD^c, Michael Krill, MD^a, Howard D. Routman, DO^d, Joseph D. Zuckerman, MD^e

^aDepartment of Orthopaedic Surgery, Cleveland Clinic Florida, Weston, FL, USA

^bDepartment of Orthopaedic Surgery, University of Florida, Gainesville, FL, USA

^cDepartment of Orthopaedic Surgery, Clinique du Sport de Bordeaux-Mérignac, Mérignac, France

^dDepartment of Orthopaedic Surgery, Palm Beach Shoulder Service, Palm Beach, FL, USA

^eDepartment of Orthopaedic Surgery, NYU Langone Medical Center, New York, NY, USA

Background: The reverse total shoulder arthroplasty (RTSA) has been used in the treatment of complex shoulder problems. The incidence of aseptic loosening of the humeral component has not been previously reported.

Methods: This is a multicenter, retrospective, blinded, case-control radiographic review of 292 patients to determine the rate of humeral stem loosening. There were 177 cemented and 115 press-fit humeral components. Radiographs were critiqued for radiolucent lines adjacent to the humeral stem based on the method described by Gruen et al.

Results: The overall rate of loosening was 0.74%. No radiographic loosening occurred in the press-fit group (115 stems). In the cemented group (177 stems), 2 shoulders (1.18%) were identified with radiographically loose stems. No loosening occurred in the press-fit group. No statistically significant difference was found in humeral stem loosening when the press-fit group and the cemented group were compared ($P = .198$).

Discussion: Our study indicates the cemented or press-fit RTSA system will result in a low incidence of radiolucent lines and radiographic loosening. Compared with historical survivorship of conventional anatomic total shoulder arthroplasty, RTSA shows a lower rate of radiographic stem loosening at a mean of 38.46 months.

Conclusions: The RTSA has a low incidence of humeral stem loosening at midterm. These results underscore the importance of careful selection of patients to provide the benefits of this surgical technique. Press-fit fixation may provide a lower risk to stem loosening.

*Reprint requests: Andres M. Alvarez-Pinzon, MD, PhD, Department of Orthopaedic Surgery, Cleveland Clinic Florida, 2950 Cleveland Clinic Blvd, Weston, FL 33331, USA.

E-mail addresses: mauricioalvarez07@yahoo.com; andresmauricioalvarez07@gmail.com (A.M. Alvarez-Pinzon).

Level of evidence: Level III, Retrospective Cohort Design, Treatment Study.

© 2015 Journal of Shoulder and Elbow Surgery Board of Trustees.

Keywords: Reverse shoulder arthroplasty; failed shoulder replacement; humeral fixation; radiographic stem loosening; satisfactory outcome

Reverse total shoulder arthroplasty (RTSA) is a viable option for patients who have substantial shoulder pain and dysfunction that cannot be reliably treated with anatomic total shoulder arthroplasty (ATSA). Reports suggest ATSA may provide reliable pain relief, with long-term survivorship of 84% to 96% at 3.3 to 12.2 years.¹⁰ However, as with all joint replacements, complications, including aseptic loosening, instability, infection, and mechanical failure, present therapeutic challenges in long-term management of patients. Although research regarding RTSA complications has centered on the loosening of the glenoid component as a latent problem,^{3,10} there are limited studies to date that have focused on humeral loosening as a mode of failure in RTSA.¹³ In comparison with ATSA, investigators have reported varying degrees of success with cemented, press-fit, and ingrowth humeral stem designs.¹²

Studies have revealed a 5-fold increase in volumetric wear between ATSA and RTSA; however, there is not a 5-fold increase in clinical failure. The main cause of failure in the cemented ATSA prosthesis is loosening of the glenoid component, which may occur for several reasons.^{1,6} The inflammatory reaction to wear debris may not be the most important factor compared with malalignment of the ATSA components.⁸ Among RTSA, the glenoid component has a relatively low rate of loosening.⁵ The effect of wear debris in the RTSA may instead be associated with a higher rate of loosening of the humeral stem.³

Since approval by the United States Food and Drug Administration in 2004, RTSA prostheses are increasingly used for glenohumeral arthropathy associated with a deficiency of the rotator cuff.^{1,15} The medialized and semi-constrained construct restores stability and movement when the muscles of the rotator cuff are deficient. The glenohumeral force is estimated to be reduced by half in a RTSA compared with ATSA.^{12,14} Also, the articular surfaces of a reversed prosthesis are more congruent and inferior than those of the anatomic model, and the contact pressure should be significantly lower.¹¹ However, polyethylene wear in RTSA is not trivial,¹³ and the volume of wear particles is greater at lower contact pressures for larger contact surfaces and with larger sliding distances.^{2,14} Until recently, problems with wear have mainly been related to scapular notching, but abrasive wear of the humeral component may also be an issue.^{7,15}

The surgical technique for RTSA requires a method of secure fixation of the humeral component in the proximal portion of the humerus. Secure fixation of the humeral

component is achieved through the insertion of the component into the reamed and broached medullary canal with cement fixation or without cement fixation using a component with the capacity for osseous ingrowth.¹¹ Each method may be successful; however, whether one approach is superior to the other in terms of future development of loosening remains to be seen.

Materials and methods

This is a multicenter, retrospective, blinded, case-control radiographic study of aseptic humeral stem loosening in RTSA. This retrospective study was conducted to review radiographs of 292 individuals who underwent primary RTSA for rotator cuff tear arthropathy using the Equinoxe prosthesis (Exactech Inc, Gainesville, FL, USA) between June 2009 and June 2014. The operations were performed by 9 surgeons as part of a multicenter data collection program. There were 177 cemented humeral components and 115 press-fit humeral components.

Experienced fellowship-trained orthopedic physicians reviewed the radiographs and were blinded to all patient identifiers. An objectivity protocol of postoperative, 6 month, 1 year, 2 year, and 3 year follow-up radiographs was implemented to identify and assess radiolucent lines adjacent to the humeral stem. The appearance of radiolucent lines was classified by location in a manner equivalent to the method described previously by Gruen et al⁶ for total hip arthroplasty (Fig. 1).¹¹ Bone adjacent to the stem was divided into 8 zones. Zones 1, 2, and 3 represent the lateral aspect of the stem at the proximal, middle and distal thirds respectively. Zone 4 is the area around the distal stem tip. Zones 5, 6, 7, and 8 represent the medial portion of the stem from the distal, middle, proximal thirds, and base, respectively. The lines were also classified according to their width as <1.00 mm, 1.0 to 1.50 mm, 1.51 to 2.0 mm or >2.01 mm. A humeral stem was found to be radiographically at risk for essential clinical loosening if a radiolucent line ≥ 2 mm was present in ≥ 3 zones. If an evaluator identified a shift in stem position between the postoperative and the most recent follow-up radiograph, it was also classified as essential clinical loosening. All patients had a minimum of 2 years radiographic follow-up (range, 24-48 months).

Statistical methods

The Wilcoxon rank sum test was used for comparisons of continuous data between press-fit and cemented groups. Differences between means were analyzed with 2-sided *t* tests. Categorical data were compared with the Pearson χ^2 test or the Fisher exact test. Ordinal ranking scores were compared with the Mantel-Haenszel test.

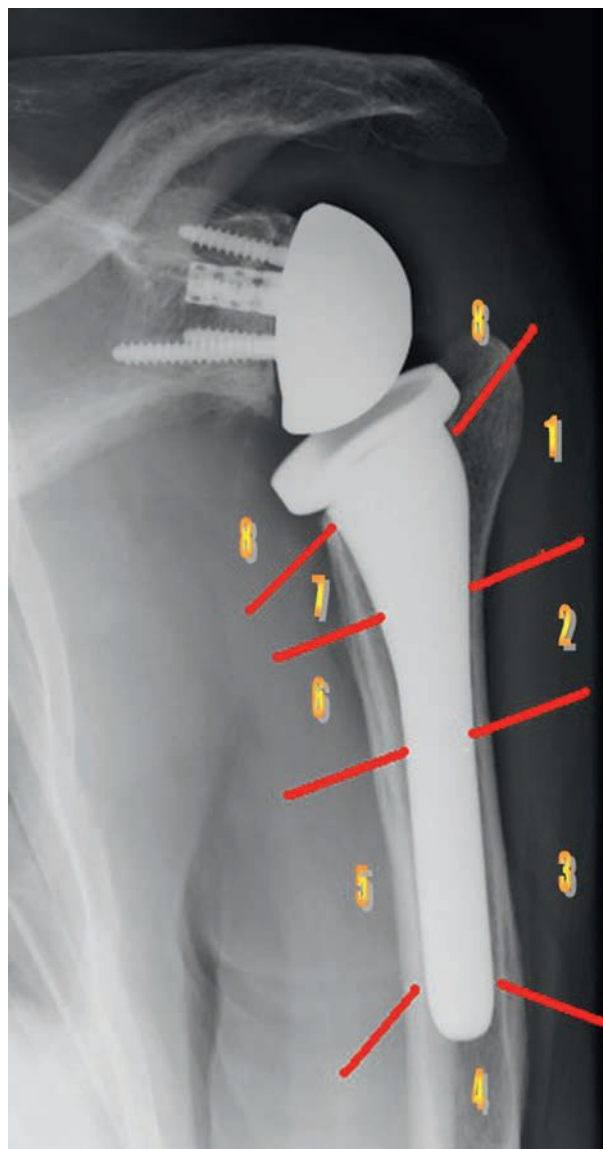


Figure 1 Humeral stem divided into thirds. Bone adjacent to the stem is divided into 8 zones. Zones 1, 2, and 3 represent the lateral aspect of the stem at the proximal, middle, and distal thirds, respectively. Zone 4 is the area around the distal stem tip. Zones 5, 6, 7, and 8 denote the medial portion of the stem from the distal, middle, and proximal thirds, and base, respectively.

Results

The radiographic evaluation did not identify radiolucent lines around any of the humeral stems during the early postoperative period. At the end of the study, with an average postoperative time of 39.76 months, no implants in either group had shifted position.

The overall rate of loosening in the cemented and press-fit groups was 0.74% (Table I). In the press-fit group (115 stems) at conclusion of the study (range, 24.64-40.6 months), there was no evidence of humeral radiographic loosening. At least 1 radiolucency line

of <1.00 mm was identified in 30 patients (26.4%) at 24 months. The lucency was most commonly observed in zone 4 at the stem's tip (Fig. 2).

The evaluation of 177 stems in the humeral cemented group, found 2 humeral components that were identified as radiographically loose (incidence rate of 1.14%). One humeral stem had radiolucent lines identified at 24 months in all radiographic zones except zones 2 and 4 (Fig. 3), whereas the other stem had radiolucent lines at 36 months in all zones except zone 4. There were 27 cases in which 1 radiolucent line was <1.00 mm (14%) during the postoperative follow-up evaluations. The most frequently appreciated radiolucent line was in zone 4 by the stem's tip.

There was no statistically significant difference in humeral stem loosening when the press-fit group and the cemented group were compared ($P = .198$).

Discussion

Although much of the discussion surrounding potential failure mechanisms of RTSA has concentrated on the glenoid component, loosening of the humeral component is another potential problem that can develop after this procedure. Multiple RTSA systems are offered, and with each system the surgeon must decide whether to cement the humeral head or use a noncemented press-fit technique.^{3,12,15} The current retrospective radiographic study indicates that cemented fixation and press-fit fixation will both result in a very low incidence of radiographic stem loosening at a mean of 39.76 months postoperatively in individuals with a minimum follow-up of 36 months. Melis et al⁹ concluded that radiologic signs of stress shielding were significantly more frequent with uncemented components, as was resorption of the greater and lesser tuberosities. In the Favard et al⁴ series, complications occurred in 3.4% of the reverse arthroplasties. There are certainly advantages for using a press-fit stem technique that relate to the ease of insertion and the potential for a less complicated future revision if stem removal is indicated. Cemented fixation provides the benefit of instant fixation, but then provides a greater challenge if stem removal becomes necessary. Our radiographic study shows that for the RTSA system used, either cemented or press-fit application will result in a minimal incidence of radiolucent lines and radiographic humeral stem loosening. Therefore, the specialist has the preference of selecting either approach with a high level of confidence that a stem fixation will not be an issue.

Although this retrospective study documents the results in 292 patients with a powered number of patients in each group, there are limitations. First, as a retrospective case series, it does not represent a randomized protocol. Each surgeon decided on the technique, whether cemented or press fit, that they preferred for each patient. Second, although some may consider the inclusion of 9 different

Table I Radiographic analysis of humeral stem fixation *

Stem Type	Shoulders numbness (No.)	Radiographically loose (%)	Radiolucency line (%)	Radiographic follow-up (y)
Cemented	177	2	27	2.7
Press fit	115	0	30	2.9
Total RTSA	292	0.7	17.8	2.8

RTSA, reverse total shoulder arthroplasty.

* Data documents the outcomes in 292 patients with a large number of subjects in each group. A humeral stem was determined to remain radiographically at risk in place of clinically main loosening if it had a radiolucent line ≥ 2.00 mm in 3 or more zones or when the observers identified a shift in stem position between the postoperative and the most recent follow-up radiographs.

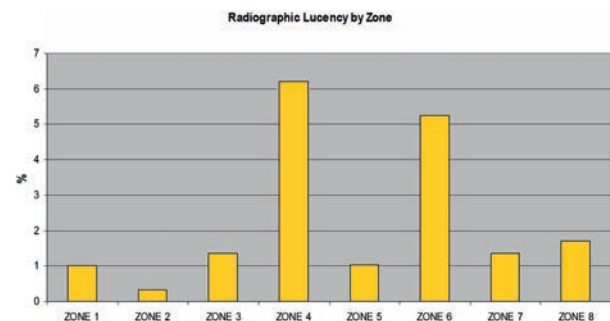


Figure 2 Radiographic lucency evaluated by humeral stem zone.⁵

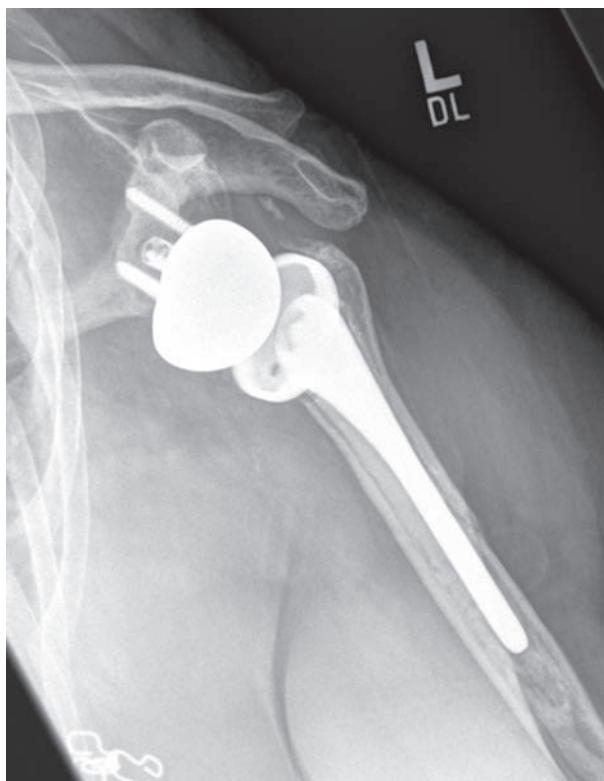


Figure 3 Stem loosening (radiographically loose). Radiolucent lines identified at 24 months. All radiographs contain lucency lines except in zones 2 and 4.

operating surgeons a limitation, we consider it a positive. Nine different surgeons can be expected to provide some individual variation in how each one approaches the fixation of the humeral component. This allows the results to translate better to the large number of orthopedic surgeons performing RTSA procedures. In an almost 3-year average follow-up, the incidence of radiographic loosening was less than 1%, which indicates that both approaches have a high likelihood of being successful according to our evaluation criteria.

Conclusions

The current data indicate that for RTSA using the system described, either cement or press-fit humeral component fixation can be expected to provide secure fixation, as evidenced by the low incidence of radiographic humeral stem loosening and radiolucent lines when evaluated after an average of a 3-year follow-up.

Disclaimer

The authors, their immediate families, and any research foundations with which they are affiliated have not received any financial payments or other benefits from any commercial entity related to the subject of this article.

Acknowledgements

The authors express their appreciation to Y. Marczuk, MD, S. Grey, MD, C.P. Roche, MD, and R. Jones for their contributions to this study.

References

- Boileau P, Melis B, Duperron D, Moineau G, Rumian AP, Han Y. Revision surgery of reverse shoulder arthroplasty. *J Shoulder*

- Elbow Surg 2013;22:1359-70. <http://dx.doi.org/10.1016/j.jse.2013.02.004>
2. De Wilde L, Walch G. Humeral prosthetic failure of reversed total shoulder arthroplasty: a report of three cases. *J Shoulder Elbow Surg* 2006;15:260-4. <http://dx.doi.org/10.1016/j.jse.2005.07.014>
 3. Farron A, Terrier A, Buchler P. Risks of loosening of a prosthetic glenoid implanted in retroversion. *J Shoulder Elbow Surg* 2006;15:521-6. <http://dx.doi.org/10.1016/j.jse.2005.10.003>
 4. Favard L, Katz D, Colmar M, Benkalfate T, Thomazeau H, Emily S. Total shoulder arthroplasty - arthroplasty for glenohumeral arthropathies: results and complications after a minimum follow-up of 8 years according to the type of arthroplasty and etiology. *Orthop Traumatol Surg Res* 2012;98(4 Suppl):S41-7. <http://dx.doi.org/10.1016/j.otsr.2012.04.003>
 5. Giuseffi SA, Streubel P, Sperling J, Sanchez-Sotelo J. Short-stem uncemented primary reverse shoulder arthroplasty: clinical and radiological outcomes. *Bone Joint J* 2014;96-B:526-9. <http://dx.doi.org/10.1302/0301-620X.96B3.32702>
 6. Gruen TA, McNeice GM, Amstutz HC. "Modes of failure" of cemented stem-type femoral components: a radiographic analysis of loosening. *Clin Orthop Relat Res* 1979;141:17-27.
 7. Levy JC, Everding NG, Gil CC Jr, Stephens S, Giveans MR. Speed of recovery after shoulder arthroplasty: a comparison of reverse and anatomic total shoulder arthroplasty. *J Shoulder Elbow Surg* 2014;23:1872-81. <http://dx.doi.org/10.1016/j.jse.2014.04.014>
 8. Mazzucco D, Spector M. Contact area as a critical determinant in the tribology of metal on polyethylene total joint arthroplasty. *J Tribology* 2006;128:113-21. <http://dx.doi.org/10.1115/1.2114930>
 9. Melis B, DeFranco M, Lädermann A. An evaluation of the radiological changes around the Grammont reverse geometry shoulder arthroplasty after eight to 12 years. *J Bone Joint Surg Br* 2011;93:1240-6. <http://dx.doi.org/10.1302/0301-620X.93B9.25926>
 10. Papadonikolakis A, Neradilek MB, Matsen FA 3rd. Failure of the glenoid component in anatomic total shoulder arthroplasty: a systematic review of the English-language literature between 2006 and 2012. *J Bone Joint Surg Am* 2013;95:2205-12. <http://dx.doi.org/10.2106/JBJS.L.00552>
 11. Raiss P, Edwards TB, Deutsch A, Shah A, Bruckner T, Loew M, Boileau P, Walch G. Radiographic changes around humeral components in shoulder arthroplasty. *J Bone Joint Surg Am* 2014;96:e54. <http://dx.doi.org/10.2106/JBJS.M.00378>
 12. Saltzman BM, Chalmers PN, Gupta AK, Romeo AA, Nicholson GP. Complication rates comparing primary with revision reverse total shoulder arthroplasty. *J Shoulder Elbow Surg* 2014;23:1647-54. <http://dx.doi.org/10.1016/j.jse.2014.04.015>
 13. Smith CD, Guyver P, Bunker TD. Indications for reverse shoulder replacement: a systematic review. *J Bone Joint Surg Br* 2012;94:577-83. <http://dx.doi.org/10.1302/0301-620X.94B5.27596>
 14. Terrier A, Reist A, Merlini F, Farron A. Simulated joint and muscle forces in reversed and anatomic shoulder prostheses. *J Bone Joint Surg Br* 2008;90:751-6. <http://dx.doi.org/10.1302/0301-620X.90B6.19708>
 15. Wiater BP, Moravek JE Jr, Wiater JM. The evaluation of the failed shoulder arthroplasty. *J Shoulder Elbow Surg* 2014;23:745-58. <http://dx.doi.org/10.1016/j.jse.2013.12.003>



ELSEVIER

Early revision within 1 year after shoulder arthroplasty: patient factors and etiology



Brian C. Werner, MD, M. Tyrrell Burrus, MD, Itse Begho, BS,
F. Winston Gwathmey, MD, Stephen F. Brockmeier, MD*

Department of Orthopaedic Surgery, University of Virginia Health System, Charlottesville, VA, USA

Background: The objective of this study is to investigate the patient factors associated with early revision within 1 year after shoulder arthroplasty, including total shoulder arthroplasty (TSA), hemiarthroplasty, and reverse TSA, and the cause of failure leading to early revision.

Methods: Patients who underwent shoulder arthroplasty from 2005 to 2012 were identified using *International Classification of Diseases, Ninth Revision* procedure codes. Those who underwent revision shoulder arthroplasty were then divided into early (<1 year) and late (>1 year) groups. Patients in each of the cohorts were queried for demographic data and etiologic factors for revision arthroplasty.

Results: A total of 221,381 patients who underwent shoulder arthroplasty were identified, including 115,956 TSAs, 75,208 hemiarthroplasties, and 30,217 reverse TSAs. The patient factors significantly associated with early revision after shoulder arthroplasty regardless of type were age younger than 65 years, smoking, obesity, and morbid obesity. Dislocation was the most common reason for early revision after all types of arthroplasties. Loosening was a more common reason for early revision after TSA compared with both hemiarthroplasty and reverse TSA.

Conclusions: Several patient factors appear to be associated with early revision after shoulder arthroplasty, including younger age, smoking, obesity, and male sex. The cause of failure leading to early revision varies between late and early revision cases. These findings are important to identify patients preoperatively who may be at risk of early revision after shoulder arthroplasty to allow appropriate patient counseling and risk stratification.

Level of evidence: Level III, Retrospective Cohort Design Using Large Database, Treatment Study.

© 2015 Journal of Shoulder and Elbow Surgery Board of Trustees.

Keywords: Total shoulder arthroplasty; shoulder hemiarthroplasty; reverse total shoulder arthroplasty; early revision arthroplasty; complications; risk factors; etiology

Shoulder arthroplasty is a well-established surgical treatment for the management of degenerative shoulder conditions and the sequelae of trauma, and it has been

performed with increasing frequency over the past decade.^{8,20} Numerous studies have shown long-term pain relief and improvement in shoulder function with reasonable implant longevity after conventional total shoulder arthroplasty (TSA), shoulder hemiarthroplasty, and reverse TSA for various indications.^{4,7,8,10,13,18,24,25,31,35,37} Despite the versatility and reasonable success of shoulder arthroplasty, the exponential increase in the number of arthroplasties performed, particularly reverse TSA, and

This study was deemed exempt by the University of Virginia Institutional Review Board Committee for Health Sciences Research.

*Reprint requests: Stephen F. Brockmeier, MD, Department of Orthopaedic Surgery, University of Virginia Health System, 400 Ray C. Hunt Dr, Ste 330, Charlottesville, VA 22908, USA.

E-mail address: sfb2e@virginia.edu (S.F. Brockmeier).

expanding indications for shoulder arthroplasty have also led to an increasing need for revision shoulder arthroplasty.^{1,5,11,12,14,15,28-30,33}

Outcomes after revision shoulder arthroplasty have been shown to be inferior to those after primary shoulder arthroplasty.^{9,12,30} Previous studies have identified obesity, younger age, and male sex as risk factors for failure of shoulder arthroplasty requiring revision.^{11,14,22,28,29,33} Causes of failure requiring revision are numerous and vary by arthroplasty type but include instability, infection, component loosening, periprosthetic fracture, motion loss, and soft tissue failure including rotator cuff disease.^{5,12,16,23,29,30,33,34}

Early revision within 1 year after shoulder arthroplasty, although uncommon, is devastating for both patient and surgeon and likely portends poor outcomes. Previous case series have implicated instability and infection as causes for early revision after shoulder arthroplasty.^{5,26} Existing studies examining risk and etiologic factors for revision after shoulder arthroplasty have focused on long-term outcomes, typically between 5 and 20 years postoperatively.^{12,14,21,27,33} The objective of our study is to investigate the patient factors associated with early revision within 1 year after shoulder arthroplasty, including TSA, hemiarthroplasty, and reverse TSA, and the cause of failure leading to early revision.

Methods

A publically available, subscription database (PearlDiver Patient Records Database [www.pearldiverinc.com]; PearlDiver Technologies, Fort Wayne, IN, USA) was used to identify patients who underwent primary TSA, shoulder hemiarthroplasty, and reverse TSA and revision shoulder arthroplasty. Data for this study were derived from a Medicare database within the PearlDiver records, which comprises data from 100% of the Medicare sample. The Medicare database contains over 100 million unique patient records from 2005 to 2012. The database contains procedure volumes and demographic data for patients with *International Classification of Diseases, Ninth Revision (ICD-9)* diagnoses and procedures or Current Procedural Terminology codes. PearlDiver Technologies granted access to the database for the purpose of academic research and maintained the data on a password-protected server.

Patients who underwent shoulder arthroplasty from 2005 to 2012 were identified using the following ICD-9 procedure codes: 81.80 (TSA), 81.81 (shoulder hemiarthroplasty), and 81.88 (reverse TSA). Patients who underwent subsequent revision shoulder arthroplasty within the confines of the database (up to 8 years postoperatively) were extracted from this cohort by searching for revision upper extremity arthroplasty (ICD-9 code 81.97) and excluding any patients who had procedural codes any time previously for total elbow replacement (ICD-9 code 81.84) or wrist and hand arthroplasty (ICD-9 codes 81.71-81.74). The resulting revision shoulder arthroplasty cohorts were then divided into early (<1 year after index shoulder arthroplasty) and late (>1 year after index shoulder arthroplasty) groups. A late revision arthroplasty group was not created for reverse TSA because the

ICD-9 procedure code was first introduced in 2010, which did not leave enough database years to create a useful late revision arthroplasty group. A control group for each shoulder arthroplasty group was created, which included patients who never underwent revision shoulder arthroplasty during the dates covered by the database.

Patients in each of the early revision and control cohorts were queried for basic demographic data including sex; age (<65 years, 65-74 years, 75-84 years, >84 years); obesity (body mass index [BMI], 30-40 kg/m²); morbid obesity (BMI >40 kg/m²); and smoking status. The etiologic factors for revision shoulder arthroplasty were compared between the revision cohorts using the ICD-9 diagnosis codes associated with the revision total shoulder procedure, including 7 categories: dislocation (ICD-9 codes 79.71, 79.81, 718.31, 831.00, 831.01, and 996.42); loosening (ICD-9 codes 996.41 and 996.43); infection (ICD-9 codes 682.3, 711.01, 711.81, 711.91, 996.66, 996.67, 996.69, and 998.59); fracture (ICD-9 codes 793.1, 812.00, 812.21, and 996.44); stiffness (ICD-9 codes 718.51, 719.51, and 726.0); rotator cuff disease (ICD-9 codes 726.10, 727.61, 840.3, 840.4, 840.5, and 840.6); and other (ICD-9 codes 996.4, 996.47, 996.77, and 996.78).

Odds ratios (ORs) and 95% confidence intervals were calculated for relevant comparisons between the cohorts. We performed χ^2 tests to determine statistical significance of univariate analysis, with $P < .05$ considered significant. All statistical analyses were completed using SPSS software, version 22 (IBM, Armonk, NY, USA).

Results

A total of 221,381 patients who underwent shoulder arthroplasty were identified, including 115,956 TSAs, 75,208 hemiarthroplasties, and 30,217 reverse TSAs. The TSA group included 2,059 patients who underwent early revision, 2,148 patients who underwent late revision, and 111,749 controls who did not undergo revision arthroplasty. The hemiarthroplasty group included 1,428 patients who underwent early revision, 1,957 patients who underwent late revision, and 71,823 controls who did not undergo revision arthroplasty. The reverse TSA group included 586 patients who underwent early revision and 29,631 patients who did not undergo revision arthroplasty.

Risk of early revision arthroplasty

The patient factors significantly associated with early revision after TSA were age younger than 65 years (OR, 1.9; $P < .0001$), smoking (OR, 1.6; $P < .0001$), obesity (OR, 1.3; $P < .0001$), and morbid obesity (OR, 1.4; $P < .0001$) (Table I). The patient factors significantly associated with early revision after shoulder hemiarthroplasty were age younger than 65 years (OR, 1.7; $P < .0001$), age 65 to 74 years (OR, 1.2; $P < .0001$), smoking (OR, 1.8; $P < .0001$), obesity (OR, 1.4; $P < .0001$), and morbid obesity (OR, 1.3; $P < .0001$) (Table II). Similar patient factors were significantly associated with early revision after reverse TSA, including male sex (OR, 2.2; $P < .0001$), age younger than

Table I Comparison of early revision (<1 year) and control total shoulder arthroplasty cohorts

Variable	Control	Early (<1 y) revision	OR (95% CI) *	P value
Overall, n	111,749	2,059		
Demographic data				
Female	67,385 (60.3%)	1,208 (58.7%)	—	—
Male	44,364 (39.7%)	851 (41.3%)	1.1 (1.0-1.2)	.14
Age <65 y	9,163 (8.2%)	293 (14.2%)	1.9 (1.6-2.1)	< .0001
Age 65-74 y	54,181 (48.5%)	927 (45.0%)	—	—
Age 75-84 y	42,249 (37.8%)	726 (35.3%)	—	—
Age >84 y	6,156 (5.5%)	113 (5.5%)	—	—
Smoker	14,178 (12.7%)	398 (19.3%)	1.6 (1.5-1.8)	< .0001
Obesity	18,392 (16.5%)	410 (19.9%)	1.3 (1.1-1.4)	< .0001
Morbid obesity	11,210 (10.0%)	272 (13.2%)	1.4 (1.2-1.6)	< .0001

CI, confidence interval; OR, odds ratio.

* ORs comparing prevalence of early revision for a given demographic or comorbidity.

Table II Comparison of early revision (<1 year) and control hemiarthroplasty cohorts

Variable	Control	Early (<1 y) revision	OR (95% CI) *	P value
Overall, n	71,823	1,428		
Demographic data				
Female	51,441 (71.6%)	1,013 (70.9%)	—	—
Male	20,382 (28.4%)	415 (29.1%)	1.0 (0.9-1.2)	.591
Age <65 y	8,205 (11.4%)	256 (17.9%)	1.7 (1.5-1.9)	< .0001
Age 65-74 y	26,918 (37.5%)	611 (42.8%)	1.2 (1.1-1.4)	< .0001
Age 75-84 y	28,197 (39.3%)	486 (34.0%)	—	—
Age >84 y	8,503 (11.8%)	76 (5.3%)	—	—
Smoker	10,952 (15.2%)	344 (24.1%)	1.8 (1.6-2.0)	< .0001
Obesity	10,303 (14.3%)	264 (18.5%)	1.4 (1.2-1.6)	< .0001
Morbid obesity	7,057 (9.8%)	183 (12.8%)	1.3 (1.2-1.6)	< .0001

CI, confidence interval; OR, odds ratio.

* ORs comparing prevalence of early revision for a given demographic or comorbidity.

65 years (OR, 2.1; $P < .0001$), smoking (OR, 1.6; $P < .0001$), obesity (OR, 1.4; $P = .003$), and morbid obesity (OR, 1.8; $P < .0001$) (Table III).

Etiologic factors for revision arthroplasty

A comparison of the etiologic factors for early revision after TSA, hemiarthroplasty, and reverse TSA is presented in Table IV, with statistical comparisons presented in Table V. Dislocation was the most common reason for early revision after reverse TSA. Dislocation was a more common reason for early revision arthroplasty after reverse TSA than after conventional TSA (38.8%, $P < .0001$) and hemiarthroplasty (26.2%, $P < .0001$). Implant loosening was a more common reason for early revision after TSA compared with both hemiarthroplasty and reverse TSA ($P < .0001$). Periprosthetic fracture was a significantly more common indication for early revision arthroplasty in patients who underwent hemiarthroplasty (7.1% of cases)

compared with both conventional TSA patients (4.0%, $P < .0001$) and reverse TSA patients (3.1%, $P = .001$). Stiffness was an infrequent indication for early revision but was significantly less commonly an indication after reverse TSA compared with conventional TSA ($P = .002$) and hemiarthroplasty ($P < .0001$). Rotator cuff disease was a more common reason for early revision after conventional TSA compared with hemiarthroplasty ($P = .001$) and reverse TSA ($P < .0001$) (Tables IV and V).

Tables VI and VII compare the etiologic factors for early revision and late revision after conventional TSA and hemiarthroplasty. For conventional TSA, dislocation ($P < .0001$) and stiffness ($P = .044$) were significantly more common reasons for early revision whereas loosening ($P < .0001$) was a significantly more common reason for late revision arthroplasty (Table VI). After shoulder hemiarthroplasty, dislocation ($P < .0001$) and infection ($P = .002$) were significantly more common reasons for early revision whereas loosening ($P = .016$) and rotator cuff

Table III Comparison of early revision (<1 year) and control reverse total shoulder arthroplasty cohorts

Variable	Control	Early (<1 y) revision	OR (95% CI)*	P value
Overall, n	29,631	586		
Demographic data				
Female	19,706 (66.5%)	281 (48.0%)	—	—
Male	9,925 (33.5%)	305 (52.0%)	2.2 (1.8-2.5)	< .0001
Age <65 y	2,033 (6.9%)	80 (13.7%)	2.1 (1.7-2.7)	< .0001
Age 65-74 y	11,966 (40.4%)	247 (42.2%)	1.1 (0.9-1.3)	.412
Age 75-84 y	12,817 (43.3%)	224 (38.2%)	—	—
Age >84 y	2,815 (9.5%)	35 (6.0%)	—	—
Smoker	4,257 (14.4%)	126 (21.5%)	1.6 (1.3-2.0)	< .0001
Obesity	4,911 (16.6%)	125 (21.3%)	1.4 (1.1-1.7)	.003
Morbid obesity	3,127 (10.6%)	103 (17.6%)	1.8 (1.5-2.2)	< .0001

CI, confidence interval; OR, odds ratio.

* ORs comparing prevalence of early revision for a given demographic or comorbidity.

Table IV Comparison of etiologic factors for early revision after shoulder arthroplasty

Variable	Total shoulder arthroplasty	Shoulder hemiarthroplasty	Reverse shoulder arthroplasty
Overall patients requiring early revision, n	2,059	1,428	586
Etiologic factor for revision			
Dislocation	799 (38.8%)	374 (26.2%)	331 (56.5%)
Loosening	378 (18.4%)	192 (13.4%)	60 (10.2%)
Infection	258 (12.5%)	151 (10.6%)	82 (14.0%)
Fracture	82 (4.0%)	102 (7.1%)	18 (3.1%)
Stiffness	106 (5.1%)	95 (6.7%)	12 (2.0%)
Rotator cuff disease	404 (19.6%)	215 (15.1%)	31 (5.3%)
Other	705 (34.2%)	686 (48.0%)	131 (22.4%)

Table V Statistical analysis of etiologic comparison

Variable	TSA vs hemiarthroplasty		TSA vs reverse shoulder arthroplasty		Hemiarthroplasty vs reverse shoulder arthroplasty	
	OR (95% CI)	P value	OR (95% CI)	P value	OR (95% CI)	P value
Dislocation	1.8 (1.5-2.1)	< .0001	0.5 (0.4-0.6)	< .0001	0.3 (0.2-0.3)	< .0001
Loosening	1.4 (1.2-1.7)	< .0001	2.0 (1.5-2.6)	< .0001	1.4 (1.0-1.9)	.057
Infection	1.2 (1.0-1.5)	.087	0.9 (0.7-1.2)	.388	0.7 (0.5-1.0)	.036
Fracture	0.5 (0.4-0.7)	< .0001	1.3 (0.8-2.2)	.37	2.4 (1.5-4.0)	.001
Stiffness	0.7 (0.6-1.0)	.072	2.6 (1.4-4.8)	.002	3.4 (1.9-6.3)	< .0001
Rotator cuff disease	1.4 (1.1-1.7)	.001	4.4 (3.0-6.4)	< .0001	3.2 (2.1-4.7)	< .0001
Other	0.6 (0.5-0.6)	< .0001	1.8 (1.5-2.2)	< .0001	3.2 (2.6-4.0)	< .0001

CI, confidence interval; OR, odds ratio; TSA, total shoulder arthroplasty.

disease ($P = .018$) were significantly more common reasons for late revision arthroplasty (Table VII).

Discussion

This study demonstrates the patient factors associated with early revision within 1 year after shoulder arthroplasty and

compares the etiologic factors for early revision among arthroplasty types, as well as between early and late revisions. The important findings of the study are the association of age younger than 65 years, smoking, obesity, and morbid obesity with early revision regardless of type of arthroplasty. Male sex was associated with early revision after reverse TSA but was not shown to have a significant association with the other arthroplasty types. Dislocation

Table VI Comparison of etiologic factors for revision after total shoulder arthroplasty

Variable	Early revision (<1 y)	Late revision (>1 y)	OR (95% CI)	P value
Overall, n	2,059	2,148		
Etiologic factor for revision				
Dislocation	799 (38.8%)	426 (19.8%)	3.2 (2.2-2.9)	< .0001
Loosening	378 (18.4%)	678 (31.6%)	0.5 (0.4-0.6)	< .0001
Infection	258 (12.5%)	236 (11.0%)	1.2 (1.0-1.4)	.132
Fracture	82 (4.0%)	102 (4.7%)	0.8 (0.6-1.1)	.255
Stiffness	106 (5.1%)	82 (3.8%)	1.4 (1.0-1.8)	.044
Rotator cuff disease	404 (19.6%)	419 (19.5%)	1.0 (0.9-1.2)	.956
Other	705 (34.2%)	855 (39.8%)	0.8 (0.7-0.9)	< .0001

CI, confidence interval; OR, odds ratio.

Table VII Comparison of etiologic factors for revision after hemiarthroplasty

Variable	Early revision (<1 y)	Late revision (>1 y)	OR (95% CI)	P value
Overall, n	1,428	1,957		
Reason for revision				
Dislocation	374 (26.2%)	227 (11.6%)	2.7 (2.3-3.2)	< .0001
Loosening	192 (13.4%)	323 (16.5%)	0.8 (0.6-1.0)	.016
Infection	151 (10.6%)	145 (7.4%)	1.5 (1.2-1.9)	.002
Fracture	102 (7.1%)	139 (7.1%)	1.0 (0.8-1.3)	.982
Stiffness	95 (6.7%)	98 (5.0%)	1.3 (1.0-1.8)	.05
Rotator cuff disease	215 (15.1%)	356 (18.2%)	0.8 (0.7-1.0)	.018
Other	686 (48.0%)	1,134 (57.9%)	0.7 (0.6-0.8)	< .0001

CI, confidence interval; OR, odds ratio.

was the most common diagnosis associated with revision shoulder arthroplasty, but the prevalence of the various etiologic factors for revision shoulder arthroplasty varied significantly among arthroplasty types and between early and late revisions.

Risk factors for late revision after shoulder arthroplasty have been previously investigated. Fevang et al¹⁴ investigated risk factors for 5- and 10-year revision after shoulder arthroplasty in 1,825 patients from the Norwegian Arthroplasty Register. They found that age younger than 70 years was a significant risk factor for requiring revision after shoulder hemiarthroplasty; male sex was a significant risk factor for requiring revision after reverse TSA. Younger age has also been associated with an increased risk of post-operative infection, and this may have an effect on the risk of early revision.²³ Singh et al³³ found that male sex and rotator cuff disease were independent risk factors for revision after conventional TSA. Obesity has also been shown to lead to higher rates of revision surgery after shoulder arthroplasty.^{21,22,32} Most of the remaining studies of revision shoulder arthroplasty have been unable to adequately identify risk factors because there was inadequate power to do so. Using a large national insurance database, we were able to review the records of over 4,000 patients who underwent early revision after shoulder arthroplasty.

Similar to studies of late revision, we found that younger age, obesity, and morbid obesity were significantly associated with early revision within 1 year of the index procedure regardless of type of shoulder arthroplasty. For reverse TSA, we found a significant association between male sex and early revision, similar to the findings of Fevang et al. We also found tobacco use to be significantly associated with early revision after shoulder arthroplasty, a finding not reported in other studies of late revision.

The important causes or diagnoses associated with revision after shoulder arthroplasty are varied and include dislocation or instability, component loosening, infection, periprosthetic fracture, stiffness, and rotator cuff failure. Dislocation, which was the most common reason for early revision after all types of shoulder arthroplasties in our study, is most commonly caused by improper implant positioning, failure of tuberosity repair after hemiarthroplasty, and subscapularis repair failure after conventional TSA or hemiarthroplasty.¹⁷ Instability has been previously recognized as a cause for early failure after reverse TSA. Chalmers et al⁵ noted a 2.9% dislocation rate for reverse TSA within 3 months postoperatively. In their series, 73% of patients with early dislocation after reverse TSA eventually required revision arthroplasty, including insertion of a thicker polyethylene insert or conversion to a

hemiarthroplasty. The cause of instability is often component malpositioning, which typically requires revision arthroplasty to correct and establish a stable shoulder.^{19,30} Although instability was the most common reason for failure requiring early revision in our series, it was significantly more common in reverse TSA cases compared with conventional TSA and hemiarthroplasty cases.

Periprosthetic infection after shoulder arthroplasty is a challenging complication that occurs in approximately 0.7% of patients.^{3,30,36} Periprosthetic infection can occur in the early postoperative period, potentially caused either by intraoperative bacterial seeding of the implant or by direct inoculation through a surgical incision that has not yet healed.^{2,3} Late postoperative infection can be caused by indolent infection or seeding due to transient bacteremia.^{2,3,23} We found that between 11% and 14% of early revision shoulder arthroplasties were performed for periprosthetic infection, with no significant difference among arthroplasty types. Infection was a more common reason for failure requiring early revision compared with late revision for hemiarthroplasty; this difference was not noted for conventional TSA.

Periprosthetic fracture was a comparatively infrequent cause for early revision in our study, although it was found significantly more frequently after hemiarthroplasty compared with both conventional TSA and reverse TSA. We found no difference in the frequency of periprosthetic fracture as an etiologic factor for early or late revision after conventional TSA or hemiarthroplasty. Most periprosthetic fractures in shoulder arthroplasty patients occur intraoperatively, and overall, the incidence ranges from 0.5% to 3%.⁶

Implant loosening, typically of the glenoid component, occurs in 0% to 12.5% of patients after shoulder arthroplasty and is often a cause for late revision arthroplasty because it results from chronic, repetitive insults to even well-positioned implants.^{1,16,17} Franta et al¹⁷ noted glenoid component loosening in 85 of 136 painful conventional TSAs, showing the prevalence of this complication over the life of shoulder arthroplasty implants. Fox et al¹⁵ used a regression analysis to show that glenoid component loosening and instability become more prevalent as the time from surgery increases. In our study, loosening as an etiologic factor for early revision was most common after conventional TSA compared with hemiarthroplasty and reverse TSA. Loosening was a significantly more common reason for late revision compared with early revision for both conventional TSA and hemiarthroplasty. For conventional and reverse TSA, this likely reflects primarily glenoid component loosening; however, the ICD-9 code for implant loosening is not specific for the exact component, so there is no method to differentiate between glenoid component and humeral stem loosening.

This study has several advantages. This is the largest study evaluating early revision after TSA. The large number of patients allowed for comparison of early and late

revision TSA and comparison of etiologic factors for each. Lastly, by using the PearlDiver database, this study allows tracking of patients to report long-term complication rates, in contrast to other databases such as the Nationwide Inpatient Sample (NIS), which only allows reporting of in-hospital complications, and the National Surgical Quality Improvement Program (NSQIP), which only allows reporting of complications within 30 days postoperatively.

This study also has several limitations that require mention. Many of the limitations of our study are inherent to all studies using large administrative databases such as PearlDiver. The power of the analysis is dependent on the quality of the available data, which includes accuracy of billing codes and miscoding or noncoding by physicians all as potential sources of error. Furthermore, not all ICD-9 codes are specific enough to determine the extent of postoperative complications or exhaustively characterize them. For example, the code for implant loosening does not specify which implant (glenoid or humeral); it only indicates that the loosening is due to mechanical reasons. Although we attempted to accurately represent a large population of interest by using the PearlDiver database, we cannot ensure that the database represents a true cross section of the United States because only Medicare data were included in the analysis. In addition, the data are reported in cohorts, preventing multivariate analysis, and thus the independent effect of BMI on postoperative complications cannot be reported because factors such as age, sex, and medical comorbidities cannot be controlled. Finally, although numerous statistically significant associations were found, statistical significance does not necessarily indicate clinical significance. Clinical significance cannot be determined from an insurance database such as PearlDiver because outcome measures are not included.

Conclusion

Several patient factors appear to be associated with early revision after shoulder arthroplasty, including younger age, smoking, obesity, and male sex. The cause of failure leading to early revision varies between late and early revision cases. These findings are important to identify patients preoperatively who may be at risk of early revision after shoulder arthroplasty to allow appropriate patient counseling and risk stratification.

Disclaimer

The authors, their immediate families, and any research foundations with which they are affiliated have not received any financial payments or other benefits from any commercial entity related to the subject of this article.

References

1. Antuna SA, Sperling JW, Cofield RH, Rowland CM. Glenoid revision surgery after total shoulder arthroplasty. *J Shoulder Elbow Surg* 2001;10:217-24.
2. Bauer TW, Parvizi J, Kobayashi N, Krebs V. Diagnosis of periprosthetic infection. *J Bone Joint Surg Am* 2006;88:869-81. <http://dx.doi.org/10.2106/JBJS.E.01149>
3. Bohsali KI, Wirth MA, Rockwood CA Jr. Complications of total shoulder arthroplasty. *J Bone Joint Surg Am* 2006;88:2279-92. <http://dx.doi.org/10.2106/JBJS.F.00125>
4. Carter MJ, Mikuls TR, Nayak S, Fehring EV, Michaud K. Impact of total shoulder arthroplasty on generic and shoulder-specific health-related quality-of-life measures: a systematic literature review and meta-analysis. *J Bone Joint Surg Am* 2012;94:e127. <http://dx.doi.org/10.2106/JBJS.K.00204>
5. Chalmers PN, Rahman Z, Romeo AA, Nicholson GP. Early dislocation after reverse total shoulder arthroplasty. *J Shoulder Elbow Surg* 2014;23:737-44. <http://dx.doi.org/10.1016/j.jse.2013.08.015>
6. Della Rocca GJ, Leung KS, Pape HC. Periprosthetic fractures: epidemiology and future projections. *J Orthop Trauma* 2011;25(Suppl 2):S66-70. <http://dx.doi.org/10.1097/BOT.0b013e31821b8c28>
7. Denard PJ, Raiss P, Sowa B, Walch G. Mid- to long-term follow-up of total shoulder arthroplasty using a keeled glenoid in young adults with primary glenohumeral arthritis. *J Shoulder Elbow Surg* 2013;22:894-900. <http://dx.doi.org/10.1016/j.jse.2012.09.016>
8. Dillon MT, Inacio MC, Burke MF, Navarro RA, Yian EH. Shoulder arthroplasty in patients 59 years of age and younger. *J Shoulder Elbow Surg* 2013;22:1338-44. <http://dx.doi.org/10.1016/j.jse.2013.01.029>
9. Dines JS, Fealy S, Strauss EJ, Allen A, Craig EV, Warren RF, et al. Outcomes analysis of revision total shoulder replacement. *J Bone Joint Surg Am* 2006;88:1494-500. <http://dx.doi.org/10.2106/JBJS.D.02946>
10. Ek ET, Neukom L, Catanzaro S, Gerber C. Reverse total shoulder arthroplasty for massive irreparable rotator cuff tears in patients younger than 65 years old: results after five to fifteen years. *J Shoulder Elbow Surg* 2013;22:1199-208. <http://dx.doi.org/10.1016/j.jse.2012.11.016>
11. Farnig E, Zingmond D, Krenek L, Soohoo NF. Factors predicting complication rates after primary shoulder arthroplasty. *J Shoulder Elbow Surg* 2011;20:557-63. <http://dx.doi.org/10.1016/j.jse.2010.11.005>
12. Farshad M, Grogli M, Catanzaro S, Gerber C. Revision of reversed total shoulder arthroplasty. Indications and outcome. *BMC Musculoskelet Disord* 2012;13:160. <http://dx.doi.org/10.1186/1471-2474-13-160>
13. Favard L, Katz D, Colmar M, Benkalfate T, Thomazeau H, Emily S. Total shoulder arthroplasty—arthroplasty for glenohumeral arthropathies: results and complications after a minimum follow-up of 8 years according to the type of arthroplasty and etiology. *Orthop Traumatol Surg Res* 2012;98(Suppl 4):S41-7. <http://dx.doi.org/10.1016/j.otsr.2012.04.003>
14. Fevang BT, Lie SA, Havelin LI, Skredderstuen A, Furnes O. Risk factors for revision after shoulder arthroplasty: 1,825 shoulder arthroplasties from the Norwegian Arthroplasty Register. *Acta Orthop* 2009;80:83-91. <http://dx.doi.org/10.1080/17453670902805098>
15. Fox TJ, Cil A, Sperling JW, Sanchez-Sotelo J, Schleck CD, Cofield RH. Survival of the glenoid component in shoulder arthroplasty. *J Shoulder Elbow Surg* 2009;18:859-63. <http://dx.doi.org/10.1016/j.jse.2008.11.020>
16. Fox TJ, Foruria AM, Klika BJ, Sperling JW, Schleck CD, Cofield RH. Radiographic survival in total shoulder arthroplasty. *J Shoulder Elbow Surg* 2013;22:1221-7. <http://dx.doi.org/10.1016/j.jse.2012.12.034>
17. Franta AK, Lenters TR, Mounce D, Neradilek B, Matsen FA III. The complex characteristics of 282 unsatisfactory shoulder arthroplasties. *J Shoulder Elbow Surg* 2007;16:555-62. <http://dx.doi.org/10.1016/j.jse.2006.11.004>
18. Griffin JW, Hadeed MM, Novicoff WM, Browne JA, Brockmeier SF. Patient age is a factor in early outcomes after shoulder arthroplasty. *J Shoulder Elbow Surg* 2014;23:1867-71. <http://dx.doi.org/10.1016/j.jse.2014.04.004>
19. Hasan SS, Leith JM, Campbell B, Kapil R, Smith KL, Matsen FA. Characteristics of unsatisfactory shoulder arthroplasties. *J Shoulder Elbow Surg* 2002;11:431-41. <http://dx.doi.org/10.1067/mse.2002.125806>
20. Kim SH, Wise BL, Zhang Y, Szabo RM. Increasing incidence of shoulder arthroplasty in the United States. *J Bone Joint Surg Am* 2011;93:2249-54. <http://dx.doi.org/10.2106/JBJS.J.01994>
21. Li X, Williams PN, Nguyen JT, Craig EV, Warren RF, Gulotta LV. Functional outcomes after total shoulder arthroplasty in obese patients. *J Bone Joint Surg Am* 2013;95:e160. <http://dx.doi.org/10.2106/JBJS.L.01145>
22. Linberg CJ, Sperling JW, Schleck CD, Cofield RH. Shoulder arthroplasty in morbidly obese patients. *J Shoulder Elbow Surg* 2009;18:903-6. <http://dx.doi.org/10.1016/j.jse.2009.02.006>
23. Mook WR, Garrigues GE. Diagnosis and management of periprosthetic shoulder infections. *J Bone Joint Surg Am* 2014;96:956-65. <http://dx.doi.org/10.2106/JBJS.M.00402>
24. Muh SJ, Streit JJ, Wanner JP, Lenarz CJ, Shishani Y, Rowland DY, et al. Early follow-up of reverse total shoulder arthroplasty in patients sixty years of age or younger. *J Bone Joint Surg Am* 2013;95:1877-83. <http://dx.doi.org/10.2106/JBJS.L.10005>
25. Pappou I, Virani NA, Clark R, Cottrell BJ, Frankle MA. Outcomes and Costs of reverse shoulder arthroplasty in the morbidly obese: a case control study. *J Bone Joint Surg Am* 2014;96:1169-76. <http://dx.doi.org/10.2106/JBJS.M.00735>
26. Portillo ME, Salvado M, Alier A, Sorli L, Martinez S, Horcajada JP, et al. Prosthesis failure within 2 years of implantation is highly predictive of infection. *Clin Orthop Relat Res* 2013;471:3672-8. <http://dx.doi.org/10.1007/s11999-013-3200-7>
27. Raiss P, Schmitt M, Bruckner T, Kasten P, Pape G, Loew M, et al. Results of cemented total shoulder replacement with a minimum follow-up of ten years. *J Bone Joint Surg Am* 2012;94. <http://dx.doi.org/10.2106/JBJS.K.00580>. e1711-10.
28. Rasmussen JV. Outcome and risk of revision following shoulder replacement in patients with glenohumeral osteoarthritis. *Acta Orthop Suppl* 2014;85:1-23. <http://dx.doi.org/10.3109/17453674.2014.922007>
29. Rasmussen JV, Polk A, Brorson S, Sorensen AK, Olsen BS. Patient-reported outcome and risk of revision after shoulder replacement for osteoarthritis. 1,209 cases from the Danish Shoulder Arthroplasty Registry, 2006-2010. *Acta Orthop* 2014;85:117-22. <http://dx.doi.org/10.3109/17453674.2014.893497>
30. Sajadi KR, Kwon YW, Zuckerman JD. Revision shoulder arthroplasty: an analysis of indications and outcomes. *J Shoulder Elbow Surg* 2010;19:308-13. <http://dx.doi.org/10.1016/j.jse.2009.05.016>
31. Shields E, Iannuzzi JC, Thorsness R, Noyes K, Voloshin I. Perioperative complications after hemiarthroplasty and total shoulder arthroplasty are equivalent. *J Shoulder Elbow Surg* 2014;23:1449-53. <http://dx.doi.org/10.1016/j.jse.2014.01.052>
32. Singh JA, Sperling JW, Cofield RH. Risk factors for revision surgery after humeral head replacement: 1,431 shoulders over 3 decades. *J Shoulder Elbow Surg* 2012;21:1039-44. <http://dx.doi.org/10.1016/j.jse.2011.06.015>

33. Singh JA, Sperling JW, Cofield RH. Revision surgery following total shoulder arthroplasty: analysis of 2588 shoulders over three decades (1976 to 2008). *J Bone Joint Surg Br* 2011;93:1513-7. <http://dx.doi.org/10.1302/0301-620X.93B11.26938>
34. Singh JA, Sperling JW, Schleck C, Harmsen WS, Cofield RH. Periprosthetic infections after total shoulder arthroplasty: a 33-year perspective. *J Shoulder Elbow Surg* 2012;21:1534-41. <http://dx.doi.org/10.1016/j.jse.2012.01.006>
35. Sperling JW, Cofield RH, Rowland CM. Minimum fifteen-year follow-up of Neer hemiarthroplasty and total shoulder arthroplasty in patients aged fifty years or younger. *J Shoulder Elbow Surg* 2004;13:604-13. <http://dx.doi.org/10.1016/j.jse.2004.03.013>
36. Strickland JP, Sperling JW, Cofield RH. The results of two-stage re-implantation for infected shoulder replacement. *J Bone Joint Surg Br* 2008;90:460-5. <http://dx.doi.org/10.1302/0301-620X.90B4.20002>
37. Young SW, Zhu M, Walker CG, Poon PC. Comparison of functional outcomes of reverse shoulder arthroplasty with those of hemiarthroplasty in the treatment of cuff-tear arthropathy: a matched-pair analysis. *J Bone Joint Surg Am* 2013;95:910-5. <http://dx.doi.org/10.2106/JBJS.L.00302>



Factors predicting postoperative range of motion for anatomic total shoulder arthroplasty



Jonathan C. Levy, MD^{a,*}, Moses T. Ashukem, MD^b, Nathan T. Formaini, DO^a

^aHoly Cross Orthopedic Institute, Fort Lauderdale, FL, USA

^bUniversity of Miami/Jackson Memorial Hospital, Miami, FL, USA

Background: Total shoulder arthroplasty (TSA) has repeatedly been shown to be an effective and durable treatment option for end-stage arthritis with good long-term survivorship. Whereas pain relief is typically the primary goal, improvements in range of motion are typically expected as well. The factors that influence postoperative motion have not been well characterized. The purpose of the study was to examine the factors that influence ultimate postoperative motion after TSA.

Methods: A retrospective review was conducted of prospectively collected data of 230 patients with minimum 1-year follow-up after TSA for end-stage arthropathy with an intact rotator cuff. Analysis was focused on factors that may correlate with postoperative measured forward flexion, abduction, external rotation, and internal rotation. Included in this analysis was perception of motion, age, body mass index (BMI), comorbidities (smoking, diabetes, osteoporosis, hypercholesterolemia, inflammatory arthritis, and thyroid disease), and number of comorbidities.

Results: Preoperative motion in all directions was predictive of postoperative motion for forward flexion ($R = 0.235$; $P < .001$), abduction ($R = 0.363$; $P < .001$), external rotation ($R = 0.325$; $P < .001$), and internal rotation ($R = 0.213$; $P = .002$). BMI and diabetes both negatively correlated with internal rotation ($R = -0.134$, $P = .40$ and $R = -0.196$, $P = .003$, respectively). Individual and total number of comorbidities were not predictive of postoperative motion. The patient's perception of preoperative motion also did not correlate with postoperative motion.

Conclusions: Preoperative range of motion before TSA is most predictive of final motion achieved. Individual and total number of comorbidities are not predictive of postoperative motion. Patients with high diabetes and increased BMI have limited postoperative internal rotation.

Level of evidence: Level IV, Case Series, Treatment Study.

© 2016 Journal of Shoulder and Elbow Surgery Board of Trustees.

Keywords: Total shoulder arthroplasty; TSA; range of motion; comorbidities

An exemption from Institutional Review Board review was obtained as this study met the conditions for exemption under 45 CFR 46.101(b) (4). A Request for Waiver of Authorization for Use and Disclosure of Protected Health Information (PHI) was obtained. No informed consent was necessary.

*Reprint requests: Jonathan C. Levy, MD, Holy Cross Orthopedic Institute, 5597 North Dixie Highway, Fort Lauderdale, FL 33334, USA.

E-mail address: jonlevy123@yahoo.com (J.C. Levy).

Anatomic total shoulder arthroplasty (TSA) is widely accepted as a reliable treatment option for patients suffering from end-stage glenohumeral arthritis.^{6,19} Through multiple studies, TSA has been shown to be effective¹⁰ and durable,¹⁰ with good long-term survivorship of the operation.^{4,24} Whereas pain relief is typically the primary goal of patients who elect to undergo this procedure, improvements in range of motion (ROM) are usually expected as well.¹²

Numerous studies have shown that TSA improves shoulder motion,^{5,10,12,13,20} but the factors that predict postoperative motion in TSA are not well understood. In total knee arthroplasty, it is well established that preoperative ROM is the strongest predictor of postoperative ROM.^{1,2,21} Other factors, such as intraoperative motion,^{1,21} soft tissue releases,^{1,21} gender,¹¹ and obesity,¹⁸ have been shown to influence postoperative motion achieved after total knee arthroplasty. Unfortunately, there is a paucity of data regarding the factors that influence postoperative motion in shoulder arthroplasty. Analyzing patients undergoing reverse shoulder arthroplasty, Schwartz et al²³ determined that intraoperative forward flexion is the greatest predictor of postoperative ROM. Other studies have isolated factors that influence overall outcomes, such as better preoperative shoulder function,⁷ limited preoperative external rotation,¹³ and certain comorbidities.²² However, no study to date has specifically analyzed the factors that influence ultimate postoperative motion after TSA.

It is imperative to educate patients on realistic expectations and outcomes after TSA to help achieve better overall patient satisfaction with the procedure. With this in mind, gaining a better understanding of which factors truly influence postoperative motion after TSA is vital in defining realistic patient expectations and ultimately producing satisfactory patient outcomes. The purpose of the study was to examine the factors that influence ultimate postoperative motion after TSA. We hypothesized that preoperative ROM would be the greatest predictor of postoperative ROM.

Materials and methods

A retrospective query of prospective collected data of all patients treated with TSA was conducted by the Holy Cross Shoulder Outcomes Repository. It has previously been established that postoperative motion plateaus at 12 months after TSA.¹⁵ Thus, all patients who underwent TSA with an intact rotator cuff and a minimum follow-up of 12 months were included in this analysis. Patients with complications requiring revision surgery were excluded from this analysis.

A single shoulder fellowship-trained surgeon performed each TSA during a 7-year period (November 2006–November 2013). The surgical technique was identical for all patients with the exception of management of the subscapularis tendon. Patients were treated with a subscapularis peel if preoperative external rotation was $<0^\circ$ or there were signs of poor bone quality (i.e., history of osteoporosis or osteopenia). The remaining patients were treated with a lesser tuberosity osteotomy. All patients were treated with a TSA system that uses a cemented polyethylene glenoid and a modular humeral head (Encore Foundation or DJO Turon, Austin, TX, USA). Postoperative rehabilitation was standardized for all patients. Patients were placed in a shoulder immobilizer for the initial 6-week period and encouraged to initiate pendulum exercises 3 times daily. At 6 weeks, patients were instructed in self-directed supine active assisted exercises

and were encouraged to use the extremity for light activities of daily living with a 2-pound weight restriction. After 3 months, patients were encouraged to continue self-directed stretching and strengthening exercises and were allowed to return to activities within comfort level.

ROM measurements including forward flexion, abduction, and external rotation were performed with a manual goniometer and entered into the repository as part of the standard protocol for all repository patients. Motion measurements were typically performed with the patient in a gown and were referenced on the basis of the angles formed between the arm and the torso. For forward elevation, the measurement was made from the side of the patient. For abduction, the measurement was made from behind the patient. External rotation measurements were made with the elbow pressed on the patient's torso with the arm at 0° of abduction. Internal rotation motion was based on the highest midline segment of the back that can be reached. Perceived motion was assessed using the repository by allowing each patient to select the picture that best represented his or her ability to achieve different directions of shoulder motion (forward flexion, abduction, and internal rotation). Each picture was correlated with its degree of motion (Fig. 1).

Data analyzed from the repository included measured preoperative and most recent postoperative motion, perceived preoperative and most recent postoperative motion, age at the time of surgery, body mass index (BMI), individual comorbidities (smoking, diabetes, osteoporosis, hypercholesterolemia, inflammatory arthritis, and thyroid disease), and total number of comorbidities. The focus of the data analysis was on the correlations of each variable with measured postoperative motion in each direction.

To determine the relationship between the variables analyzed in this study and postoperative ROM, linear regression analyses, Pearson correlations, Spearman correlations, and point-biserial correlations were used where appropriate. Correlation coefficients (R) and P values were reported to determine level of significance. Statistical analyses were performed with SPSS version 21 (SPSS Inc., Chicago, IL, USA), with significance set at $P < .05$.

Results

A total of 238 patients met the inclusion criteria for this study. The average age of subjects was 70 years (range, 45–89 years), with an average follow-up of 28 months (range, 12–82 months). There were a total of 121 men and 117 women. BMI averaged 29 (range, 18–49). Eight of the 238 subjects were removed from the final analysis because of postoperative complications: 1 patient with posterior subluxation, 4 patients with subscapularis insufficiency, 1 patient with a postoperative infection, 1 patient with postoperative neuropathy, and 1 patient with a postoperative rotator cuff tear. The remaining 230 patients were included in the final analysis.

Significant improvements in measured ROM were observed for all directions of motion (Table I). As seen in Table II and Figure 2, preoperative motion was predictive of measured postoperative motion. This was true for forward flexion ($R = 0.235$; $P < .001$), abduction ($R = 0.363$;

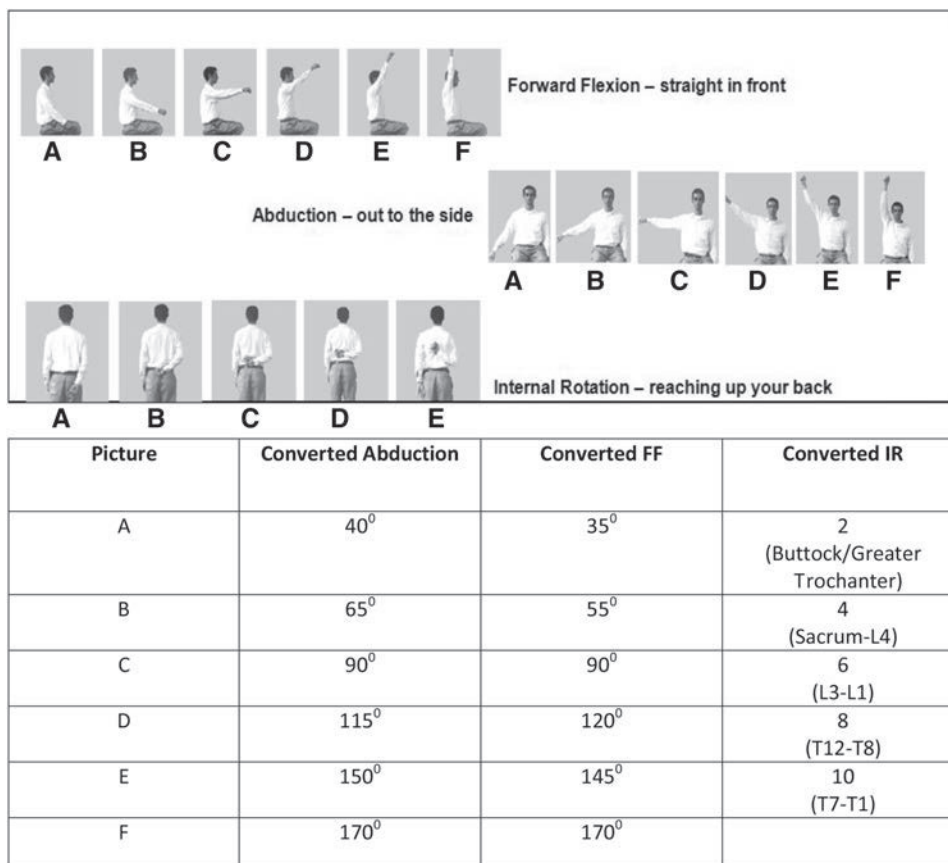


Figure 1 Perceived motion. Pictures used in the repository, which allow patients to estimate their motion. Each patient selects the picture that represents his or her ability to reach straight in front (forward flexion, *FF*), out to the side (abduction), and up the back (internal rotation, *IR*). Each picture was then converted to a measured degree of motion.

Table I Improvements in measured range of motion

Change in measured range of motion				
	Average measured preoperative motion	Average measured postoperative motion	Change in motion	<i>P</i> value
Abduction	69°	101°	32°	<.001
Forward flexion	98°	142°	44°	<.001
Internal rotation	4 (sacrum-L4)	8 (T12-T8)	40% (improvement)	<.001
External rotation	18°	50°	32°	<.001

$P < .001$), external rotation ($R = 0.325$; $P < .001$), and internal rotation ($R = 0.213$; $P = .002$). However, the patient’s perception of preoperative motion was not correlated with postoperative motion (P value range, .113-.991).

Of the comorbidities analyzed, only BMI and diabetes were found to negatively correlate with postoperative measured ROM. This is summarized in Table II. BMI and diabetes negatively correlated with preoperative internal rotation only ($R = -0.134$, $P = .40$ and $R = -0.196$, $P = .003$, respectively). BMI and diabetes, however, were positively correlated with each other ($R = 0.171$; $P = .10$). No other comorbidity was predictive of any direction of measured postoperative motion. Looking specifically at

preoperative internal rotation, BMI was negatively correlated with measured preoperative internal rotation ($R = -0.206$; $P = .002$).

Discussion

TSA is widely accepted as a reliable treatment option for end-stage glenohumeral arthritis with an intact rotator cuff.^{4,10,14,16,19} It has consistently been shown to improve pain, function, and overall quality of life.^{16,19} As noted in this and multiple other studies, TSA results in significant improvements in motion.^{3,6-8} However, before this study,

Table II Predictors of measured postoperative motion

Predictors of forward elevation		
Predictor variable	Postoperative abduction	<i>P</i> value
Preoperative forward flexion	<i>R</i> = .363	< .001
Perceived preoperative forward flexion	<i>R</i> = .102	.181
Age	<i>R</i> = .068	.293
BMI	<i>R</i> = .063	.334
Any comorbidity	<i>R</i> = .006	.926
Total number of comorbidities	<i>R</i> = .002	.972
Smoking	<i>R</i> = .078	.230
Diabetes	<i>R</i> = -.034	.604
Osteoporosis	<i>R</i> = -.041	.526
Hypercholesterolemia	<i>R</i> = .032	.617
Inflammatory arthritis	<i>R</i> = -.117	.079
Thyroid disease	<i>R</i> = .007	.909
Predictors of abduction		
Preoperative abduction	<i>R</i> = .245	< .001
Perceived preoperative abduction	<i>R</i> = .009	.991
Age	<i>R</i> = .045	.490
BMI	<i>R</i> = .003	.959
Any comorbidity	<i>R</i> = .080	.219
Total number of comorbidities	<i>R</i> = .028	.669
Smoking	<i>R</i> = .074	.252
Diabetes	<i>R</i> = -.073	.264
Osteoporosis	<i>R</i> = -.103	.111
Hypercholesterolemia	<i>R</i> = .076	.246
Inflammatory arthritis	<i>R</i> = -.102	.117
Thyroid disease	<i>R</i> = .036	.575
Predictors of external rotation		
Preoperative external rotation	<i>R</i> = .325	< .001
Age	<i>R</i> = .013	.844
BMI	<i>R</i> = .082	.205
Any comorbidity	<i>R</i> = .026	.688
Total number of comorbidities	<i>R</i> = .074	.253
Smoking	<i>R</i> = .031	.636
Diabetes	<i>R</i> = -.007	.913
Osteoporosis	<i>R</i> = .056	.389
Hypercholesterolemia	<i>R</i> = .036	.584
Inflammatory arthritis	<i>R</i> = .012	.848
Thyroid disease	<i>R</i> = .097	.135
Predictors of internal rotation		
Preoperative internal rotation	<i>R</i> = .213	.002
Perceived preoperative internal rotation	<i>R</i> = .117	.133
Age	<i>R</i> = .001	.992
BMI	<i>R</i> = -.134	.040
Any comorbidity	<i>R</i> = -.101	.121
Total number of comorbidities	<i>R</i> = -.075	.250
Smoking	<i>R</i> = -.016	.811
Diabetes	<i>R</i> = -.196	.003
Osteoporosis	<i>R</i> = -.032	.624
Hypercholesterolemia	<i>R</i> = .093	.152
Inflammatory arthritis	<i>R</i> = -.088	.178
Thyroid disease	<i>R</i> = -.016	.806

BMI, body mass index.

Bold values indicate statistical significance.

the factors that may influence postoperative motion had not been well established. The results of this study demonstrate that preoperative motion is the factor most predictive of postoperative motion in all directions. Comorbidities, for the most part, did not correlate with overall postoperative motion.

Factors that influence overall outcomes of TSA have been previously described. Most reports have focused on radiographic findings, such as glenoid erosion, rotator cuff degeneration, and humeral head subluxation.^{6,8,13} Matsen et al¹⁷ reported that higher preoperative physical function, social function, mental health, and shoulder function correlated with postoperative shoulder function after TSA. Henn et al¹² found that increased patient expectations correlated with better outcomes, whereas decreased patient expectations correlated with poorer overall outcomes. Iannotti and Norris¹³ noted that postoperative external rotation was dependent on the degree of measured preoperative external rotation. Finally, Donigan et al⁵ were unable to correlate preoperative motion with postoperative outcome; however, admittedly, the study may have been underpowered.

In our study, with the exception of BMI and diabetes (for internal rotation only), comorbidities did not correlate with postoperative motion. This was true for the individual comorbidities as well as for the number of comorbidities for each patient. Patient demographics and comorbidities such as age, smoking, osteoporosis, hypercholesterolemia, inflammatory arthritis, and thyroid disease were not predictive of final postoperative motion, nor did the number of comorbidities correlate with postoperative motion. Donigan et al⁵ noted similar findings in their study as it relates to final outcome, as the number of comorbidities did not correlate with postoperative patient outcomes. In contrast, others have reported poor outcomes in patients with an increasing number of comorbidities.^{17,22} Interestingly, whereas BMI and diabetes were shown to significantly correlate with postoperative internal rotation, BMI also was shown to negatively correlate with preoperative internal rotation. Thus, this study suggests that patients with increased BMI tend to have limited internal rotation regardless of treatment.

The strengths of this study relate to the large cohort of patients included in the analysis as well as the examination of all major directions of postoperative motion. The study was focused specifically on the factors that correlate with measured postoperative motion. In addition, as a single-surgeon series, all patients were treated with identical postoperative rehabilitation protocols and essentially the same surgical technique, which helped to control for variations seen in surgical technique and rehabilitation with multisurgeon studies. However, as with any single-surgeon series, the results may not be applicable to the other orthopedic surgeons. Whereas statistically significant correlations between measured preoperative and postoperative motion were observed, the observed effect (*R* ranged from

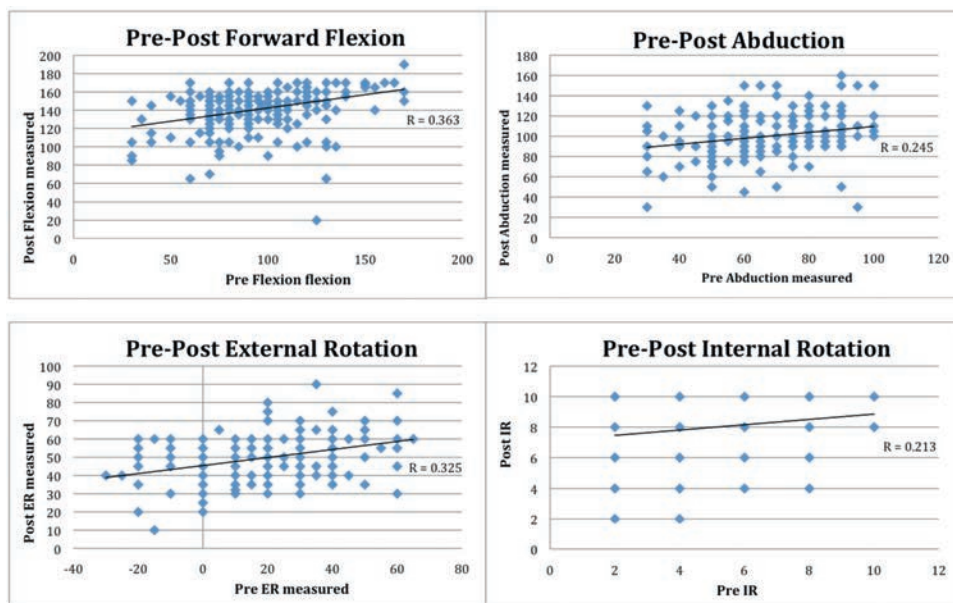


Figure 2 Scatter plots illustrating the correlation between preoperative measured motion and postoperative measured motion for forward flexion, abduction, external rotation (*ER*), and internal rotation (*IR*).

0.213 to 0.363) may be of less clinical significance. Finally, measurement bias from goniometric measurements of motion⁹ may have been introduced by several factors, including patient effort and clinician measurement.

Conclusions

TSA significantly improves shoulder ROM, with preoperative motion being the most important factor in predicting a patient's final postoperative ROM. With the exception of a negative correlation of internal rotation with increased BMI and diabetes, comorbidities did not correlate with postoperative motion.

Disclaimer

Jonathan C. Levy is a consultant for and receives royalties from DJO Orthopaedics. All the other authors, their immediate families, and any research foundation with which they are affiliated have not received any financial payments or other benefits from any commercial entity related to the subject of this article.

References

- Ahmed I, Gray A, Linden M, Nutton R. Range of flexion after primary TKA: the effect of soft tissue release and implant design. *Orthopedics* 2009;32:811. <http://dx.doi.org/10.3928/01477447-20090922-13>
- Anouchi YS, McShane M, Kelly F Jr, Elting J, Stiehl J. Range of motion in total knee replacement. *Clin Orthop Relat Res* 1996;87-92.
- Buckley T, Miller R, Nicandri G, Lewis R, Voloshin I. Analysis of subscapularis integrity and function after lesser tuberosity osteotomy versus subscapularis tenotomy in total shoulder arthroplasty using ultrasound and validated clinical outcome measures. *J Shoulder Elbow Surg* 2014;23:1309-17. <http://dx.doi.org/10.1016/j.jse.2013.12.009>
- Deshmukh AV, Koris M, Zurakowski D, Thornhill TS. Total shoulder arthroplasty: long-term survivorship, functional outcome, and quality of life. *J Shoulder Elbow Surg* 2005;14:471-9. <http://dx.doi.org/10.1016/j.jse.2005.02.009>
- Donigan JA, Frisella WA, Haase D, Dolan L, Wolf B. Pre-operative and intra-operative factors related to shoulder arthroplasty outcomes. *Iowa Orthop J* 2009;29:60-6.
- Edwards TB, Kadakia NR, Boulahia A, Kempf JF, Boileau P, Nemoz C, et al. A comparison of hemiarthroplasty and total shoulder arthroplasty in the treatment of primary glenohumeral osteoarthritis: results of a multicenter study. *J Shoulder Elbow Surg* 2003;12:207-13. [http://dx.doi.org/10.1016/S1058-2746\(02\)86804-5](http://dx.doi.org/10.1016/S1058-2746(02)86804-5)
- Fehring EV, Kopjar B, Boorman RS, Churchill RS, Smith KL, Matsen FA III. Characterizing the functional improvement after total shoulder arthroplasty for osteoarthritis. *J Bone Joint Surg Am* 2002; 84:1349-53.
- Figgie HE, Inglis AE, Goldberg VM, Ranawat CS, Figgie MP, Wile JM. An analysis of factors affecting the long-term results of shoulder arthroplasty for inflammatory arthritis. *J Arthroplasty* 1988;2:123-30.
- Gajdosik RL, Bohannon RW. Clinical measurement of range of motion. Review of goniometry emphasizing reliability and validity. *Phys Ther* 1987;67:1867-72.
- Goldberg BA, Smith K, Jackins S, Campbell B, Matsen FA 3rd. The magnitude and durability of functional improvement after total shoulder arthroplasty for degenerative joint disease. *J Shoulder Elbow Surg* 2001;10:464-9.
- Harvey IA, Barry K, Kirby SP, Johnson R, Elloy MA. Factors affecting the range of movement of total knee arthroplasty. *J Bone Joint Surg Br* 1993;75:950-5.
- Henn RF III, Ghomrawi H, Rutledge JR, Mazumdar M, Mancuso CA, Marx RG. Preoperative patient expectations of total shoulder arthroplasty. *J Bone Joint Surg Am* 2011;93:2110-5. <http://dx.doi.org/10.2106/JBJS.J.01114>

13. Iannotti JP, Norris TR. Influence of preoperative factors on outcome of shoulder arthroplasty for glenohumeral osteoarthritis. *J Bone Joint Surg Am* 2003;85:251-8.
14. Jandhyala S, Unnithan A, Hughes S, Hong T. Subscapularis tenotomy versus lesser tuberosity osteotomy during total shoulder replacement: a comparison of patient outcomes. *J Shoulder Elbow Surg* 2011;20:1102-7. <http://dx.doi.org/10.1016/j.jse.2011.03.019>
15. Levy JC, Everding NG, Gill CC, Stephens S, Giveans MR. Speed of recovery after shoulder arthroplasty: a comparison of reverse and anatomic total shoulder arthroplasty. *J Shoulder Elbow Surg* 2014;23:1872-81. <http://dx.doi.org/10.1016/j.jse.2014.04.014>
16. Lo IKY, Litchfield RB, Griffin S, Faber K, Patterson SD, Kirkley A. Quality-of-life outcome following hemiarthroplasty or total shoulder arthroplasty in patients with osteoarthritis. A prospective randomized trial. *J Bone Joint Surg Am* 2005;87:2178-85. <http://dx.doi.org/10.2106/JBJS.D.02198>
17. Matsen FA, Antoniou J, Rozencwaig R, Campbell B, Smith KL. Correlates with comfort and function after total shoulder arthroplasty for degenerative joint disease. *J Shoulder Elbow Surg* 2000;9:465-9.
18. Natarajan GB, Narayan VR, Vijayaraghavan. Does preoperative flexion factor influence the postoperative range of motion in total knee arthroplasty. *J Orthop Traumatol Rehabil* 2014;7:78-83. <http://dx.doi.org/10.4103/0975-7341.134025>
19. Norris TR, Iannotti JP. Functional outcome after shoulder arthroplasty for primary osteoarthritis: a multicenter study. *J Shoulder Elbow Surg* 2002;11:130-5. <http://dx.doi.org/10.1067/mse.2002.121146>
20. Rasmussen JV, Polk A, Brorson S, Sørensen AK, Olsen BS. Patient-reported outcome and risk of revision after shoulder replacement for osteoarthritis. 1,209 cases from the Danish Shoulder Arthroplasty Registry, 2006-2010. *Acta Orthop* 2014;85:117-22. <http://dx.doi.org/10.3109/17453674.2014.893497>
21. Ritter MA, Harty LD, Davis KE, Meding JB, Berend ME. Predicting range of motion after total knee arthroplasty. Clustering, log-linear regression, and regression tree analysis. *J Bone Joint Surg Am* 2003;85:1278-85.
22. Rozencwaig R, van Noort A, Moskal MJ, Smith KL, Sidles JA, Matsen FA III. The correlation of comorbidity with function of the shoulder and health status of patients who have glenohumeral degenerative joint disease. *J Bone Joint Surg Am* 1998;80:1146-53.
23. Schwartz DG, Cottrell BJ, Teusink MJ, Clark RE, Downes KL, Tannenbaum RS, et al. Factors that predict postoperative motion in patients treated with reverse shoulder arthroplasty. *J Shoulder Elbow Surg* 2014;23:1289-95. <http://dx.doi.org/10.1016/j.jse.2013.12.032>
24. Torchia ME, Cofield RH, Settergren CR. Total shoulder arthroplasty with the Neer prosthesis: long-term results. *J Shoulder Elbow Surg* 1997;6:495-505.



ELSEVIER

Posterior augmented glenoid implants require less bone removal and generate lower stresses: a finite element analysis



Jared J. Allred, MD^a, Cesar Flores-Hernandez, BS^b, Heinz R. Hoenecke Jr, MD^a, Darryl D. D'Lima, MD, PhD^{b,*}

^aDivision of Orthopaedic Surgery, Scripps Clinic, La Jolla, CA, USA

^bShiley Center for Orthopaedic Research & Education at Scripps Clinic, La Jolla, CA, USA

Hypothesis: Glenoid retroversion can be corrected with standard glenoid implants after anterior-side asymmetric reaming or by using posterior augmented glenoid implants with built-in corrections. The purpose of this study was to compare 2 augmented glenoid designs with a standard glenoid design, measure the amount of bone removed, and compute the stresses generated in the cement and bone.

Methods: Finite element models of 3 arthritic scapulae with varying severities of posterior glenoid wear were each implanted with 4 different implant configurations: standard glenoid implant in neutral alignment with asymmetric reaming, standard glenoid implant in retroversion, glenoid implant augmented with a posterior wedge in neutral alignment, and glenoid implant augmented with a posterior step in neutral alignment. The volume of cortical and cancellous bone removed and the percentage of implant back surface supported by cortical bone were measured. Stresses and strains in the implant, cement, and glenoid bone were computed.

Results: Asymmetric reaming for the standard implant in neutral version required the most bone removal, resulted in the lowest percentage of back surface supported by cortical bone, and generated strain levels that risked damage to the most bone volume. The wedged implant removed less bone, had a significantly greater percentage of the back surface supported by cortical bone, and generated strain levels that risked damage to significantly less bone volume.

Conclusions: The wedged glenoid implants appear to have various advantages over the standard implant for the correction of retroversion.

Level of evidence: Basic Science Study; Computer Modeling

© 2016 Journal of Shoulder and Elbow Surgery Board of Trustees.

Keywords: Total shoulder arthroplasty; glenoid; finite element analysis; posterior augment wedged; stepped; retroversion; arthritis

Scripps Institutional Review Board approval was obtained for this study (Protocol No. IRB-13-6297).

*Reprint requests: Darryl D. D'Lima, MD, PhD, Shiley Center for Orthopaedic Research and Education at Scripps Clinic, 11025 North Torrey Pines Road, Suite 200, La Jolla, CA 92027, USA.

E-mail address: ddlima@scripps.edu (D.D. D'Lima).

Posterior glenoid wear is common in the setting of glenohumeral osteoarthritis.^{30,31} Cadaveric and computer modeling studies have revealed the potential risks of excessive retroversion on implant stability, eccentric glenoid loading, and fixation stresses, which can increase the risk for glenoid loosening.^{1,7,16,29} Multiple studies have highlighted the importance of

correcting glenoid retroversion to restore the normal biomechanics of the glenohumeral joint.^{19,32} Surgical options for correcting glenoid retroversion during total shoulder replacement include asymmetric (anterior) reaming of the high side of the glenoid, correcting the posterior wear with a bone graft, and implanting an augmented glenoid component.

Although a precise threshold has not been established, there is a limit to the amount of retroversion that can be corrected with anterior reaming. This is in part due to the increased risk of peg perforation, excessive bone removal, downsizing of the glenoid component, and medialization with possible glenoid loosening.^{5,7,24,28} Whereas bone grafting to correct glenoid retroversion is one alternative, it is technically demanding, and clinical results have been mixed.^{12,17} A third option for treating patients with posterior wear is implanting a glenoid prosthesis with a posterior augment. This design feature can reduce glenoid bone removal due to asymmetric reaming as well as avoid the pitfalls of bone grafting while correcting retroversion.

Two posterior augmented designs have recently become commercially available: a design with a posterior step (StepTech; DePuy Orthopaedics, Warsaw, IN, USA) and a design with a posterior wedge (Equinox; Exactech, Gainesville, FL, USA). Despite the alternative approaches available to correct a retroverted glenoid, quantitative comparisons to inform the decision-making process are limited.²⁷ The purpose of this study was to determine which augmented implant design required the least amount of bone removal and resulted in the lowest stresses on the cement and adjacent glenoid bone in a finite element analysis model.

Materials and methods

Preoperative computed tomography (CT) scans of the shoulder were obtained from 121 consecutive patients with osteoarthritis scheduled for total shoulder arthroplasty. CT was performed in a GE LightSpeed RT 16 scanner (GE Healthcare, Waukesha, WI, USA) with 0.625-mm slice thickness. Glenoid version was measured with respect to the axis of the scapular body on 3-dimensional reconstructions of the CT scan as previously described.^{8,13,15} From this CT data set, we selected 3 scapulae with B2 glenoids to represent increasing severity of retroversion: mild, moderate, and severe posterior glenoid wear. Our analysis of shoulders without arthritis revealed an average retroversion of $3^\circ \pm 4.5^\circ$.¹³ A clinical study of our total shoulder arthroplasty patients found an average retroversion of $8.6^\circ \pm 9.8^\circ$.¹⁴ We therefore chose 8° (1 standard deviation above the average for normal retroversion) to represent a mild case and 17° (1 standard deviation above the average for arthritic shoulders) to represent a severe case. We selected a scapula approximately midway between the 2 extremes to represent a moderate degree of retroversion. The scapula with mild wear had 8° of retroversion, the scapula with moderate wear had 13° of retroversion, and the scapula with severe wear had 17° of retroversion.

Surface meshes were generated for both cortical and cancellous bone regions using 3-dimensional image segmentation software (Mimics; Materialise, Leuven, Belgium). These surface meshes were converted to solid meshes with 10-node quadratic tetrahedral element in HyperMesh (Altair Engineering, Troy, MI, USA). To simulate surgical reaming and surgical drilling for fixation of pegged glenoid components, appropriate volumes of bone were removed from the scapular models using Boolean subtraction. Correction of the retroversion of the osteoarthritic scapulae by eccentric reaming was simulated by Boolean subtraction using a sphere with a radius matching that of the back surface of the glenoid component, which was translated medially until the entire back surface was in contact with bone. The Young modulus of the elements composing cancellous bone was based on local cancellous bone density for each element obtained from the CT images with a K_2HPO_4 calibration phantom and calculated using previously described relationships.^{3,26} The cortical elements were assigned a Young modulus of 20 GPa.¹¹

Implant geometry

Computer-aided design models (Fig. 1) of the following glenoid designs were reverse engineered from retrievals and marketing images:

1. A standard glenoid component (Global APG+, DePuy Orthopaedics)
2. A posterior augmented glenoid with 8° , 12° , and 16° wedges (Equinox, Exactech)
3. A glenoid component augmented with 3-, 5-, and 7-mm steps (StepTech, DePuy Orthopaedics) with an estimated version correction of 6° , 10° , and 13° , respectively.

The polyethylene glenoid components were meshed using hexahedral elements with Young modulus of 1 GPa.⁶ The humeral head was modeled as a rigid sphere with a radius of a corresponding humeral component sized for each shoulder: 24.3 mm for the 8° and 12° retroverted glenoids and 29.7 mm for the 17° retroverted glenoid. The corresponding radius of curvature for the glenoid articular surface was 30 mm for the 8° and 12° retroverted glenoids and 32.7 mm for the 17° retroverted glenoid. A cement mantle was simulated around the fixation pegs of the glenoid implants (Fig. 2). The thickness of the cement mantle represented the differences between the radius of the implant peg and that of the surgical drill bit used for drilling the peg holes. The thickness of the cement mantle was 0.2 mm around the pegs for the standard and stepped designs. The cement mantle thickness varied from 0.36 to 0.7 mm for the wedged design because of the tapered pegs. Implant-cement and cement-bone interfaces were treated as perfectly bonded to simulate ideal fixation.

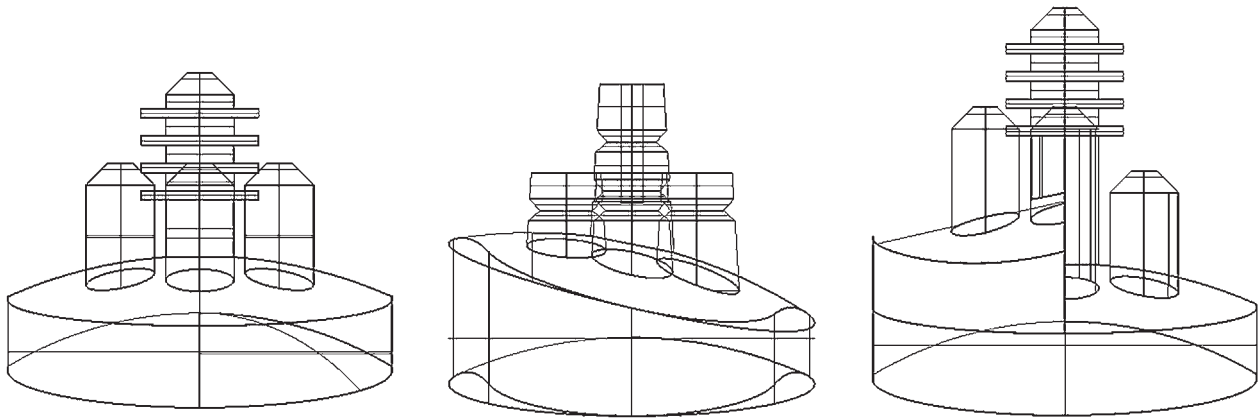


Figure 1 Design geometry of the glenoid components analyzed. From *left to right*, the standard glenoid component, the wedged glenoid design, and the stepped glenoid design.

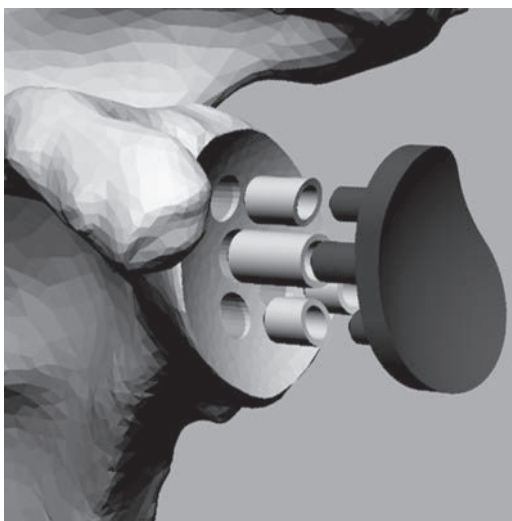


Figure 2 Finite element model of scapula bone, glenoid implant, and cement mantle around the fixation pegs.

Surgical conditions

Each of the 3 scapulae were virtually implanted in 4 different conditions (Fig. 3): a standard pegged glenoid placed in neutral version after eccentric reaming of the glenoid face (Std-A); a standard pegged glenoid placed with minimal glenoid surface reaming and no correction of retroversion (Std-R); a glenoid component with a wedged posterior augment (Wedge); and a glenoid component with a stepped posterior augment (Step). This implantation of different designs in the same scapula allowed a pairwise comparison in the same subject. Table I lists the net version after correction for each of the surgical conditions.

Boundary conditions

The medial border of the scapula blade was fixed. The humeral head component was translated posteriorly by 0.5 mm for each degree of retroversion based on a cadaveric experimental study

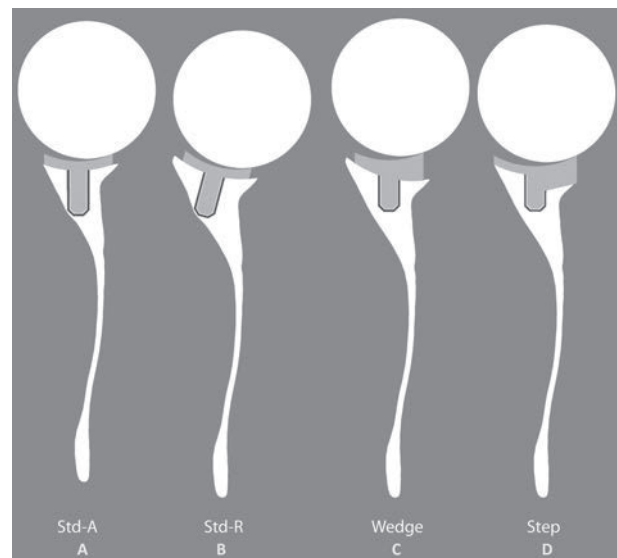


Figure 3 Comparison of posterior augmented designs to standard design in each scapula model. (A) Standard glenoid design in neutral alignment (medialized). (B) Standard glenoid design in retroversion. (C) Wedged glenoid design with retroversion corrected to neutral. (D) Stepped glenoid design with retroversion corrected to neutral. Note that the humeral head is translated 0.5 mm posteriorly for every degree of preoperative retroversion.²⁵

of retroverted glenoids (Table II).²⁵ Contact between the humeral and glenoid components was simulated, and a compressive force of 625 N (representing 85% body weight) was applied through the humeral head into the glenoid surface. This glenohumeral contact force was chosen on the basis of published in vivo measurements of glenohumeral joint reaction forces at 90° elevation of the arm in the scapular plane.²

Finite element solver

Implicit static finite element analysis was conducted in Abaqus v6.12 (Dassault Systèmes Simulia Corp, Providence, RI, USA). Second-order tetrahedral elements (C3D10) were used for the

Table I Patient demographics and correction of version

Severity of wear	Age	Gender	Bone density (g/mL) Mean (±SD)	Retroversion before correction (degrees)	Retroversion after correction (degrees)
Mild wear	87	Female	0.28 (±0.18)	8	0
Moderate wear	62	Male	0.29 (±0.18)	13	1
Severe wear	64	Male	0.27 (±0.22)	17	2

SD, standard deviation.

Table II Posterior shift of the humeral head to account for retroversion

Severity of wear	Retroversion before correction (degrees)	Posterior translation (mm)
Mild wear	8	4
Moderate wear	13	6
Severe wear	17	8

scapular bone, whereas hexahedral elements (C3D8) were used for the glenoid component and for the cement mantle.

Analysis of bone

The volume of cortical and cancellous bone removed during simulated surgical placement was computed for the 4 surgical conditions in each scapula using Mimics.

Anatomic boundaries were used to define 3 regions of interest: the glenoid joint surface laterally, the medial vertex of a cone defining the glenoid vault, and the cortical bone at the scapular neck in superoinferior and anteroposterior directions.¹¹ Within each region of interest, we identified the maximum compressive stress and computed the corresponding fatigue life for that region using the following power law expression to calculate the cyclic failure of cortical bone⁴:

$$Nf = 4.79 \times 10^{-25} (\Delta\sigma / E)^{-11.88}$$

where Nf is the fatigue life, 4.79×10^{-25} and -11.88 are constants derived from fitting to experimental data, and $\Delta\sigma/E$ is the compression stress normalized to the modulus of cortical bone.

In a similar manner, fatigue life of the trabecular bone was calculated using a power law derived from experimental compression tests on human trabecular bone of vertebrae in function of strain by the following expression¹⁰:

$$Nf = 4.57 \times 10^{-18} (\Delta\sigma / E)^{-8.54}$$

where Nf is the fatigue life, 4.57×10^{-18} and -8.54 are constants derived from fitting to experimental data, and $\Delta\sigma/E$ is the compression stress normalized to the modulus of trabecular bone.

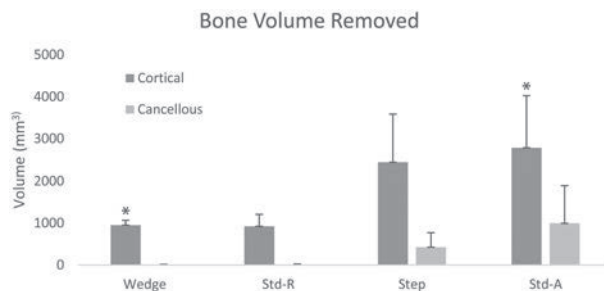


Figure 4 Cortical and cancellous bone removed for each surgical condition averaged across the 3 specimens. *The difference in cortical bone volume between the wedged design and the standard design placed in neutral version approached statistical significance ($P = .055$).

Analysis of the cement mantle

Cyclic fatigue life of the cement layer was predicted using a power law function of the maximum principal stress that yielded the probability of survival of each finite element over 10 million loading cycles²³ and was given by

$$Ps = -A\hat{\sigma}^3 + B\hat{\sigma}^2 - C\sigma + D$$

where Ps is the probability of survival, σ is the maximum principal stress (MPa), $A = 0.0005$, $B = 0.0202$, $C = 0.3304$, and $D = 1.8365$.

Statistical analysis

Repeated-measures analysis of variance and post hoc paired t tests ($P < .05$) were used to determine the statistical significance of differences in volume of bone removed, cortical bone support, volume of bone with strain $> 0.8\%$, and fatigue life of cement among the different glenoid conditions.

Results

Bone volume removed

The average volume of cortical bone removed was lowest for the wedged design and highest for the standard design placed in neutral version (Fig. 4). In general, less cancellous bone was removed than cortical bone, but the cancellous volume removed also followed the same trend. The difference in cortical bone volume between the wedged design and the standard

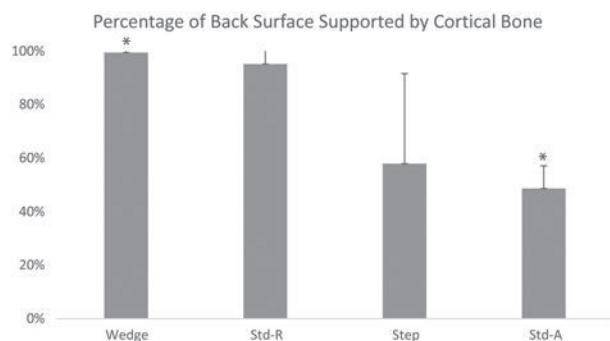


Figure 5 The percentage of back surface of the glenoid component that was supported by cortical bone. *The percentage of cortical support for the wedged implant was significantly greater than that for the standard design placed in neutral version ($P = .009$).

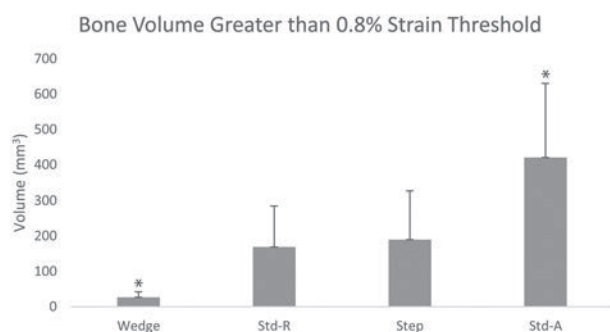


Figure 6 The volume of bone at risk for damage (>0.8% strain). *The volume of bone with strain higher than 0.8% for the wedged implant was significantly lower than that for the standard design placed in neutral version ($P < .001$).

design placed in neutral version approached statistical significance ($P = .055$). However, none of the other differences were statistically significant.

Cortical bone support

Consistent with the volume of cortical bone removal, the wedged implant had the highest percentage of cortical support, whereas the asymmetrically reamed standard implant had the least cortical support (Fig. 5). The percentage of cortical support for the wedged implant was significantly greater than that for the standard design placed in neutral version ($P = .009$). No other comparisons were statistically significant.

Bone strain

We used the magnitude of bone strain as one measure of the risk for acute bone damage. A threshold value of 0.8% strain was chosen to approximate the average of the yield strain reported for bone.²² The average volume of bone with strain higher than 0.8% was highest for the asymmetrically reamed standard design and lowest for the wedged design (Fig. 6). The volume of bone with strain higher than 0.8% for the

wedged implant was significantly lower than that for the standard design placed in neutral version ($P < .001$). No other comparisons were statistically significant.

Fatigue life

The wedged implant resulted in longer expected fatigue lives for bone in all four of the scapular regions evaluated (Fig. 7), although no statistically significant differences were found. The average percentage of cement mantle volume expected to survive 10 million loading cycles with 95% certainty was similar for the wedged, stepped, and standard designs implanted in retroversion (Fig. 8). However, this percentage was lower and more variable in the cement mantle of the asymmetrically reamed standard design.

Discussion

Posterior glenoid wear is a common consequence of glenohumeral osteoarthritis and is an important issue to be addressed in performing total shoulder arthroplasty in patients with glenohumeral osteoarthritis.^{8,15} Failure to correct glenoid retroversion can result in eccentric glenoid component loading, subluxation of the humeral head, and early loosening.^{7,25} Three commonly recommended procedures for correcting glenoid retroversion include asymmetric reaming of the glenoid, bone grafting to replace lost bone, and implanting a posterior augmented glenoid component. We compared the biomechanical benefits of 4 different implant options: a retroverted standard implant, a standard implant after asymmetric reaming, a wedged implant, and a stepped implant.

In a prior finite element analysis, we reported decreased cement interface stresses and increased bone fatigue life when a glenoid component augmented with a posterior wedge was implanted in an arthritic scapula with severe (17°) retroversion.¹¹ We concluded that a wedged component can be a viable option to correct severe arthritic retroversion by reducing the need for eccentric reaming and lessening the risk of implant failure. However, that analysis was conducted in a single arthritic scapula implanted with a generic wedged design. In this study, we constructed models of 3 scapulae representing a range of severities of posterior glenoid bone loss due to wear. In addition, we used computer-aided design models of 2 commercially available posterior augmented glenoids have been available in the United States since 2009 and 2010, respectively. The present study found that use of posterior augmented wedged glenoid components reduced the volume of bone removal, increased the cortical support of the glenoid polyethylene, and enhanced bone fatigue life compared with a standard design implanted in neutral version after asymmetric reaming.

We have also previously reported on the volume of surgical bone removal in arthritic scapulae classified as Walch

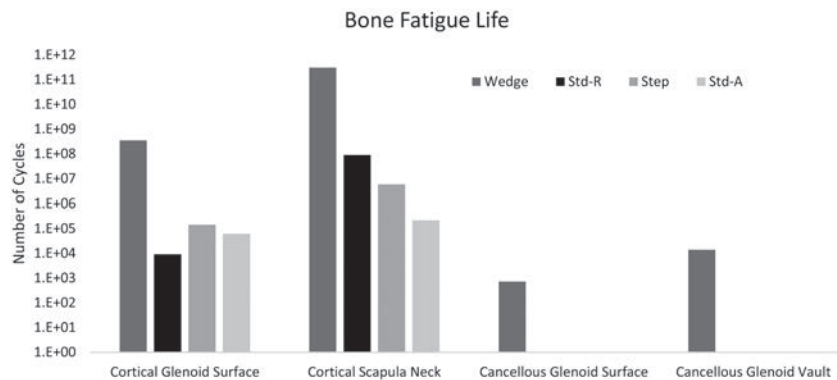


Figure 7 The predicted fatigue life of bone in the various regions.

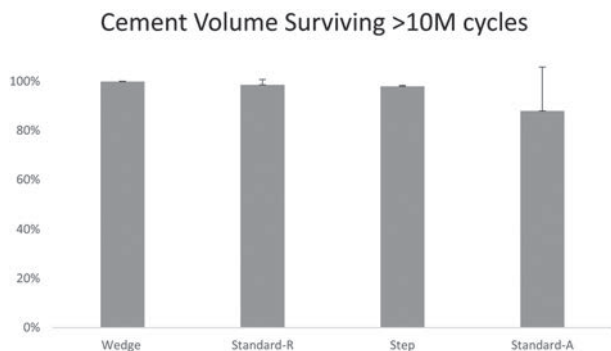


Figure 8 The average percentage of cement mantle expected to survive 10 million loading cycles like the one simulated in this study with a 95% certainty.

B2 glenoids that were virtually implanted with standard, stepped, and wedged components.²⁰ In that study, stepped and wedged components required less bone removal to correct glenoid version to neutral, with the wedged design requiring the least amount of bone removed. In the present study, also the wedged design required less bone removal than the standard design implanted in neutral version (approaching statistical significance). Modifications to the wedge design can further reduce the volume of bone removal. In a similar analysis, Knowles et al reported that a posterior wedge design required less bone removal to fully correct glenoid retroversion than a full wedge or a stepped design.²¹

Our study also suggested that the percentage of the back surface of the glenoid supported by cortical bone was associated with the volume of cement expected to survive at least 10 million loading cycles. The standard glenoid design implanted after asymmetric reaming had the least percentage of back surface supported by cortical bone and the lowest volume of cement to survive fatigue damage. These results indicate that preservation of cortical bone may have an added advantage in maintaining the structural integrity of cement mantle. Preservation of cortical bone may be an important factor to consider in correcting retroversion by asymmetric reaming.

Iannotti et al studied micromotion and liftoff of glenoid designs implanted in polyurethane foam blocks (Sawbones; Pacific Research Laboratories, Vashon, WA, USA).¹⁸ Anterior liftoff was measured when the humeral head was translated 4 mm in the posterior and superior direction over 100,000 cycles. The authors concluded that a stepped glenoid design generated less anterior liftoff with eccentric loading than a wedged design and therefore indicated superior fixation. We did not study liftoff in our study. However, we translated the humeral head 0.5 mm posteriorly for each degree of retroversion, resulting in 4, 6, and 8 mm of posterior translation. The stresses and strains in our model did not reveal differences that could be attributed to inferior fixation in the wedged design relative to the stepped design.

Few studies have clinically evaluated augmented glenoid implants. Rice et al²⁶ published midterm outcomes of a case series of 14 patients who underwent insertion of a keeled, augmented glenoid component, which provided a 4° correction of version. No shoulder required revision surgery at a minimum of 2 years. However, 2 patients had unsatisfactory results, 3 patients had residual posterior subluxation, and 2 had anterior subluxation after surgery, which was attributed to a weakened subscapularis. Custom augmented implants have also been evaluated. Gunther and Lynch⁹ reported a 3-year follow-up of 7 patients who underwent shoulder arthroplasty with a custom, augmented implant designed to address severe bone deficiency. Clinical scores were excellent (mean American Shoulder and Elbow Surgeons score of 94.1), and there was no evidence of loosening.

Our study was a computer model that is limited by our assumptions. We assumed a perfect cement mantle, which likely does not represent the variations in the cement that is surgically implanted during shoulder arthroplasty. Also, our model did not account for the interdigitation of cement into cancellous bone that occurs in vivo. We simulated forces generated only during one activity (shoulder abduction to 90°); other activities may generate different stresses and strains. We did not compute micromotion or liftoff under conditions in which the humeral head is translated in a superior-posterior direction (as reported by Iannotti et al¹⁸). Nevertheless, under the conditions we analyzed, the volume of surgical bone

removal and the fatigue life of bone were lower in scapulae implanted with posterior augmented wedged glenoid designs.

Conclusion

The results of this finite element analysis indicate that posterior augmented glenoid implants have several advantages when used to correct clinically relevant retroversion due to posterior glenoid wear. The wedged and stepped designs tested in our study tended to require lower volume of bone removal, provided greater cortical support, and had longer bone and cement fatigue life compared with a standard design implanted after asymmetric reaming. These results need to be corroborated by *in vitro* validation and well-designed clinical outcome studies.

Disclaimer

Funding support for this study was provided by Exactech and in part by a Scripps Clinic Medical Group Research & Education Grant. The authors, their immediate families, and any research foundation with which they are affiliated have not received any financial payments or other benefits from any commercial entity related to the subject of this article.

References

1. Armstrong AD, Lewis GS. Design evolution of the glenoid component in total shoulder arthroplasty. *J Bone Joint Surg Am* 2013;95:1000-10. <http://dx.doi.org/10.2106/JBJS.RVW.M.00048>
2. Bergmann G, Graichen F, Bender A, Kaab M, Rohlmann A, Westerhoff P. In vivo glenohumeral contact forces—measurements in the first patient 7 months postoperatively. *J Biomech* 2007;40:2139-49. <http://dx.doi.org/10.1016/j.jbiomech.2006.10.037>
3. Buchler P, Ramaniraka NA, Rakotomanana LR, Iannotti JP, Farron A. A finite element model of the shoulder: application to the comparison of normal and osteoarthritic joints. *Clin Biomech (Bristol, Avon)* 2002;17:630-9.
4. Caler WE, Carter DR. Bone creep-fatigue damage accumulation. *J Biomech* 1989;22:625-35.
5. Clavert P, Millett PJ, Warner JJ. Glenoid resurfacing: what are the limits to asymmetric reaming for posterior erosion? *J Shoulder Elbow Surg* 2007;16:843-8. <http://dx.doi.org/10.1016/j.jse.2007.03.015>
6. D'Lima DD, Steklov N, Fregly BJ, Banks SA, Colwell CW Jr. In vivo contact stresses during activities of daily living after knee arthroplasty. *J Orthop Res* 2008;26:1549-55. <http://dx.doi.org/10.1002/jor.20670>
7. Farron A, Terrier A, Büchler P. Risks of loosening of a prosthetic glenoid implanted in retroversion. *J Shoulder Elbow Surg* 2006;15:521-6. <http://dx.doi.org/10.1016/j.jse.2005.10.003>
8. Friedman RJ, Hawthorne KB, Genez BM. The use of computerized tomography in the measurement of glenoid version. *J Bone Joint Surg Am* 1992;74:1032-7.
9. Gunther SB, Lynch TL. Total shoulder replacement surgery with custom glenoid implants for severe bone deficiency. *J Shoulder Elbow Surg* 2012;21:675-84. <http://dx.doi.org/10.1016/j.jse.2011.03.023>
10. Haddock SM, Yeh OC, Mummaneni PV, Rosenberg WS, Keaveny TM. Similarity in the fatigue behavior of trabecular bone across site and species. *J Biomech* 2004;37:181-7. [http://dx.doi.org/10.1016/S0021-9290\(03\)00245-8](http://dx.doi.org/10.1016/S0021-9290(03)00245-8)
11. Hermida JC, Flores-Hernandez C, Hoenecke HR, D'Lima DD. Augmented wedge-shaped glenoid component for the correction of glenoid retroversion: a finite element analysis. *J Shoulder Elbow Surg* 2014;23:347-54. <http://dx.doi.org/10.1016/j.jse.2013.06.008>
12. Hill JM, Norris TR. Long-term results of total shoulder arthroplasty following bone-grafting of the glenoid. *J Bone Joint Surg Am* 2001;83:877-83.
13. Hoenecke HR Jr, Hermida JC, Dembitsky N, Patil S, D'Lima DD. Optimizing glenoid component position using three-dimensional computed tomography reconstruction. *J Shoulder Elbow Surg* 2008;17:637-41. <http://dx.doi.org/10.1016/j.jse.2007.11.021>
14. Hoenecke HR Jr, Hermida JC, Flores-Hernandez C, D'Lima DD. Accuracy of CT-based measurements of glenoid version for total shoulder arthroplasty. *J Shoulder Elbow Surg* 2010;19:166-71. <http://dx.doi.org/10.1016/j.jse.2009.08.009>
15. Hoenecke HR Jr, Tibor LM, D'Lima DD. Glenoid morphology rather than version predicts humeral subluxation: a different perspective on the glenoid in total shoulder arthroplasty. *J Shoulder Elbow Surg* 2012;21:1136-41. <http://dx.doi.org/10.1016/j.jse.2011.08.044>
16. Hopkins AR, Hansen UN, Amis AA, Emery R. The effects of glenoid component alignment variations on cement mantle stresses in total shoulder arthroplasty. *J Shoulder Elbow Surg* 2004;13:668-75. <http://dx.doi.org/10.1016/j.jse.2004.04.008>
17. Iannotti JP, Frangiamore SJ. Fate of large structural allograft for treatment of severe uncontained glenoid bone deficiency. *J Shoulder Elbow Surg* 2012;21:765-71. <http://dx.doi.org/10.1016/j.jse.2011.08.069>
18. Iannotti JP, Lappin KE, Klotz CL, Reber EW, Swope SW. Lift-off resistance of augmented glenoid components during cyclic fatigue loading in the posterior-superior direction. *J Shoulder Elbow Surg* 2013;22:1530-6. <http://dx.doi.org/10.1016/j.jse.2013.01.018>
19. Iannotti JP, Norris TR. Influence of preoperative factors on outcome of shoulder arthroplasty for glenohumeral osteoarthritis. *J Bone Joint Surg Am* 2003;85:251-8.
20. Kersten AD, Flores-Hernandez C, Hoenecke HR, D'Lima DD. Posterior augmented glenoid designs preserve more bone in biconcave glenoids. *J Shoulder Elbow Surg* 2015;24:1135-41. <http://dx.doi.org/10.1016/j.jse.2014.12.007>
21. Knowles NK, Ferreira LM, Athwal GS. Augmented glenoid component designs for type B2 erosions: a computational comparison by volume of bone removal and quality of remaining bone. *J Shoulder Elbow Surg* 2015;24:1218-26. <http://dx.doi.org/10.1016/j.jse.2014.12.018>
22. Kopperdahl DL, Keaveny TM. Yield strain behavior of trabecular bone. *J Biomech* 1998;31:601-8.
23. Murphy BP, Prendergast PJ. On the magnitude and variability of the fatigue strength of acrylic bone cement. *Int J Fatigue* 2000;22:855-64.
24. Nowak DD, Bahu MJ, Gardner TR, Dyrszka MD, Levine WN, Bigliani LU, et al. Simulation of surgical glenoid resurfacing using three-dimensional computed tomography of the arthritic glenohumeral joint: the amount of glenoid retroversion that can be corrected. *J Shoulder Elbow Surg* 2009;18:680-8. <http://dx.doi.org/10.1016/j.jse.2009.03.019>
25. Nyffeler RW, Sheikh R, Atkinson TS, Jacob HA, Favre P, Gerber C. Effects of glenoid component version on humeral head displacement and joint reaction forces: an experimental study. *J Shoulder Elbow Surg* 2006;15:625-9. <http://dx.doi.org/10.1016/j.jse.2005.09.016>
26. Rice JC, Cowin SC, Bowman JA. On the dependence of the elasticity and strength of cancellous bone on apparent density. *J Biomech* 1988;21:155-68.
27. Roche CP, Diep P, Grey SG, Flurin PH. Biomechanical impact of posterior glenoid wear on anatomic total shoulder arthroplasty. *Bull Hosp Jt Dis* 2013;2013(Suppl 2):S5-11.
28. Sabesan V, Callanan M, Sharma V, Iannotti JP. Correction of acquired glenoid bone loss in osteoarthritis with a standard versus an augmented

- glenoid component. *J Shoulder Elbow Surg* 2014;23:964-73. <http://dx.doi.org/10.1016/j.jse.2013.09.019>
29. Shapiro TA, McGarry MH, Gupta R, Lee YS, Lee TQ. Biomechanical effects of glenoid retroversion in total shoulder arthroplasty. *J Shoulder Elbow Surg* 2007;16:S90-5. <http://dx.doi.org/10.1016/j.jse.2006.07.010>
 30. Sperling JW, Hawkins RJ, Walch G, Zuckerman JD. Complications in total shoulder arthroplasty. *J Bone Joint Surg Am* 2013;95:563-9.
 31. Walch G, Badet R, Boulahia A, Khoury A. Morphologic study of the glenoid in primary glenohumeral osteoarthritis. *J Arthroplasty* 1999;14:756-60.
 32. Walch G, Moraga C, Young A, Castellanos-Rosas J. Results of anatomic nonconstrained prosthesis in primary osteoarthritis with biconcave glenoid. *J Shoulder Elbow Surg* 2012;21:1526-33. <http://dx.doi.org/10.1016/j.jse.2011.11.030>



Reverse total shoulder arthroplasty with structural bone grafting of large glenoid defects

Richard B. Jones, MD^{a,*}, Thomas W. Wright, MD^b, Joseph D. Zuckerman, MD^c

^a*Southeastern Sports Medicine, Asheville, NC, USA*

^b*Orthopaedics and Sports Medicine Institute, University of Florida, Gainesville, FL, USA*

^c*Department of Orthopaedic Surgery, NYU Langone Medical Center, New York, NY, USA*

Background: Large glenoid defects pose difficulties in shoulder arthroplasty. Structural grafts consisting of a humeral head autograft, iliac crest, and allograft have been described. Few series describe grafts used with reverse total shoulder arthroplasty (RTSA).

Methods: We retrospectively reviewed patients who had undergone primary or revision RTSA. We identified 44 patients (20 men and 24 women; mean age, 69 years) as having a bulk structural graft to the glenoid behind the baseplate. The grafts consisted of a humeral head autograft in 29, iliac crest autograft in 1, or femoral head allograft in 14. Range of motion data, American Shoulder and Elbow Surgeons score, simple shoulder test, shoulder pain and disability index, and Constant scores were obtained from preoperative and the latest follow-up visits. Radiographs were reviewed from the initial postoperative visit and the latest follow-up. The grafting cohort was compared with an age- and sex-matched cohort of RTSA patients without glenoid grafting.

Results: Improvements were seen in the functional outcome scores at the latest follow-up. No significant differences were found in the preoperative or postoperative data between allografts and autografts. Postoperative scores for the bone graft cohort were significantly lower than those in the cohort without grafting. Complete or partial incorporation was shown radiographically in 81% of grafts. Six baseplates were considered loose. Complications included 2 infections, 1 dislocation, 1 humeral loosening, and 2 instances of clinical aseptic baseplate loosening. Six patients showed mild scapular notching.

Conclusions: The use of bulk structural grafts is a promising treatment option. Allografts may yield equally acceptable results compared with autografts.

Level of evidence: Level IV; Case Series; Treatment Study

© 2016 Journal of Shoulder and Elbow Surgery Board of Trustees. All rights reserved.

Keywords: Bulk structural grafts; glenoid defects; reverse total shoulder arthroplasty; glenoid grafting; autograft; allograft

The Western Institutional Review Board approved this study (study number: 1135020).

*Reprint requests: Richard B. Jones, MD, Southeastern Sports Medicine, 21 Turtle Creek Dr., Asheville, NC 28803, USA.

E-mail address: sportdoerbj@aol.com (R.B. Jones).

Lack of sufficient glenoid bone stock caused by erosion or dysplasia is one of the most difficult problems in shoulder arthroplasty. Numerous studies have reported compromised results when anatomic total shoulder arthroplasty (TSA) is performed in the presence of significant posterior glenoid erosion.^{13,16,23} Iannotti and Norris¹⁶ found that, compared with

other patients in their study, patients with posterior subluxation of the humeral head and posterior glenoid erosion had lower final American Shoulder and Elbow Surgeons (ASES) scores, increased pain, and decreased active external rotation after TSA or hemiarthroplasty. Levine et al²⁰ divided glenoid wear into 2 types. Type I showed only concentric wear, and type II was nonconcentric wear. They showed only 63% satisfactory results after hemiarthroplasty in patients with type II glenoids.

Walch et al³⁴ developed the most commonly used classification system for glenoid morphology. Walch types B2 and C (hypoplastic) pose the most difficult reconstruction challenges. Frankle et al¹⁰ described common glenoid wear patterns in rotator cuff tear arthropathy. These include posterior, superior, anterior, and global wear.

Adverse consequences can occur from implantation of a reverse TSA (RTSA) in patients with severely eroded glenoids. Excessive medialization of the implants can lead to inferomedial impingement causing scapular notching that results in bone erosion, instability, and polyethylene wear.^{4,11} Anterior posterior impingement from significant abnormal version can limit internal and external rotation.^{4,11} Finally, excessive humeral medialization can decrease deltoid wrapping around the greater tuberosity, leading to instability and cosmetic issues in some patients.^{4,5,12}

Options to address abnormal wear include eccentric reaming, augmented implants, and bone grafting. Numerous studies have reported successful results of autografts with RTSA.^{3,19,21,22,25,28,29} Large structural grafts from the humeral head or iliac crest have been used to reconstruct posterior, superior, and anterior defects. Screws used for baseplate fixation can be used to secure the graft. More recently, extended pegged baseplates have been used to assist fixation to the native scapula.^{21,35} However, far fewer studies report results of structural allografts for glenoid reconstructions with RTSA^{2,17,21,35} and, to our knowledge, no studies have compared results of allografts vs. autografts.

Our study quantified the clinical outcomes and compared results using a structural allograft or autograft placed behind the glenoid baseplate to address large structural defects of the glenoid during RTSA. We hypothesized (1) that a single-stage reconstruction for these defects combined with RTSA would achieve significant improvements in standard outcome measures and motion, (2) that there would be no difference in autograft vs. allograft outcomes, and (3) that patients requiring glenoid bone graft would not perform as well as a cohort of patients undergoing RTSA without the need for bone graft.

Materials and methods

A multicenter data registry was used to identify patient candidates from 3 fellowship-trained shoulder surgeons. Preoperative and postoperative data were analyzed from 44 patients (20 men and 24 women), with an average age of 69.1 ± 7.4 years, who received primary RTSA or revision RTSA (Equinox RTSA; Exactech, Inc.,

Gainesville, FL, USA) requiring a structural bone graft behind the baseplate for a severe glenoid defect. Average follow-up was 40.6 ± 16 months.

Thirty patients received an autograft (29 autograft humeral heads and 1 autograft iliac crest) behind the baseplate, and 14 patients received an allograft femoral head. The choice of graft was determined by the availability and quality of the humeral head. If there was no head, such as in revisions, allograft femoral head or autograft iliac crest was chosen. The head in some primary cases was too small or worn to adequately correct the deformity, and allograft was chosen.

These patients were evaluated and scored preoperatively and at the latest follow-up using the ASES, Constant, simple shoulder test (SST), and shoulder pain and disability index (SPADI) scoring metrics. Daily pain, active abduction, forward flexion, and external rotation were also measured. Measurements were performed by a physical therapist or athletic trainer using a goniometer with consistent technique between sites. A Student 2-tailed, unpaired *t* test was used to identify differences in preoperative and postoperative results, for which $P < .05$ denoted a significant difference.

The data were evaluated using 3 comparisons: (1) the entire cohort was evaluated by comparing preoperative vs. postoperative results; (2) the autograft group was compared with the allograft group using preoperative scores, postoperative scores, and amount of improvement; and (3) the entire cohort was compared with an age- and sex-matched control cohort of patients receiving a RTSA without bone grafting.

All patients underwent radiographic evaluation to compare immediate postoperative vs. latest follow-up images. Radiographs consisting of anteroposterior Grashey, axillary lateral, and outlet views were assessed for graft incorporation, evidence of baseplate loosening, humeral lucent lines, and scapular notching. Graft incorporation, which can be difficult to determine, was defined for the purposes of this study as fully incorporated ($\geq 75\%$), partially incorporated (25% to 75%), or not incorporated ($< 25\%$) according to the amount of graft remaining at the latest radiographs. One of the authors (T.W.W.) reviewed all radiographs.

Surgical technique

A deltopectoral approach was performed in all shoulders. The biceps was tenodesed, and the subscapularis, if present, was released. After exposure of the humeral head and removal of osteophytes, the humeral head was resected and saved as a bone graft. In revision RTSA or if the humeral head was not suitable for grafting, a femoral head allograft was used for glenoid reconstruction. (An iliac crest autograft was used in 1 shoulder.) The glenoid was initially reamed slightly to provide a smoother concentric surface for the graft. Small holes were often drilled in the glenoid surface to facilitate blood flow and potentially enhance incorporation of the graft.

The graft was shaped by hand initially to achieve an approximate fit to correct the defect. Once this was satisfactorily achieved, custom inverse reamers (Exactech, Inc.) were used to ream the backside of the graft to match the previously reamed native glenoid surface more precisely. Allograft bone matrix gel was used between the graft and native glenoid to fill any small voids. The graft was provisionally held with Kirschner wires inserted at an angle that did not impede placement of the baseplate. A Kirschner wire was then inserted through the graft into the native glenoid down the center of the glenoid vault (based on finger palpation of the anterior glenoid neck at the Matsen point).



Figure 1 Standard length cage baseplate compared with extended cage baseplate (Exactech, Inc., Gainesville, FL, USA).

The new surface was reamed with the standard cannulated reamers to accept the baseplate in the proper orientation. When graft thickness exceeded 5 mm, an extended cage baseplate was used to span the graft into the native glenoid (Fig. 1). The final fixation of the graft was achieved using screws through the baseplate, spanning the graft into the native glenoid (Fig. 2). The goals of grafting were to restore version and inclination to as close to neutral as possible and increase glenoid bone stock. The baseplate used in these cases allows the ability to place all screws at variable angles. Therefore, version was not significantly altered to achieve adequate screw purchase for baseplate fixation. After final fixation of the glenoid, the humerus was completed using the standard technique.

Results

All patients who received an allograft or autograft demonstrated significant improvements after treatment with RTSA. Comparison of preoperative with postoperative results for the entire cohort (autografts and allografts) showed that the ASES scores improved from 36 to 75 ($P < .001$), Constant scores improved from 30 to 57.7 ($P < .001$), SST scores improved from 3.2 to 8.2 ($P < .001$), and SPADI scores improved from 85.2 to 35 ($P < .001$). Abduction improved from 69° to 102° ($P < .001$), forward flexion improved from 75° to 116° ($P < .001$), and external rotation improved from 14° to 26° ($P = .02$). Pain scores improved from 6.3 to 1.9 ($P < .001$; Table I).

Comparison of preoperative to postoperative results for the allograft group alone showed that the ASES scores improved from 38.3 to 72.5 ($P = .002$), Constant scores improved from 34.5 to 57 ($P = .003$), and SST scores improved from 3.8 to 8.1 ($P = .005$). Abduction improved from 60° to 100° ($P < .001$), and forward flexion improved from 63° to 116° ($P < .0001$). No significant improvements occurred in external rotation ($P = .772$). Pain scores improved from 6.1 to 2.7 ($P = .024$; Table II).

Comparison of preoperative with postoperative results for the autograft group alone showed that the ASES scores improved from 35 to 76 ($P < .0001$), Constant scores improved from 28.5 to 58 ($P < .0001$), and SST scores improved from 3 to 8.3 ($P < .0001$). Abduction improved from 73° to 103° ($P < .0003$), forward flexion improved from 78° to 116° ($P < .0001$), and external rotation improved from 10° to 26°

($P = .014$). Pain scores improved from 6.4 to 1.5 ($P < .0001$; Table III).

No significant differences were present between the allograft and autograft groups preoperatively (Table IV). The differences in postoperative outcome measures, pain scores, or range of motion (ROM) between the allograft and autograft groups (Table V) were not significant. There were also no significant differences in average improvement for all measures between the allograft and autograft groups (Table VI).

When the graft cohort was compared with an age- and sex-matched control cohort of primary RTSAs that did not require a bone graft, no preoperative differences were seen between the graft cohort and matched control cohort (Table VII). The matched control cohort showed significantly better postoperative results in all outcome measures, except for SPADI ($P = .051$), active abduction, and external rotation, compared with the bone graft cohort (Table VIII).

Radiographic evaluation

Evaluation of the entire cohort showed that 21 grafts (51.7%) fully incorporated, 12 (29.3%) partially incorporated, and 8 (19.5%) were not incorporated. The X-ray images in 3 patients were considered inadequate to quantify incorporation. The autograft group alone showed that 16 grafts fully incorporated (58.6%), 9 grafts partially incorporated (31%), and 4 grafts did not incorporate (13.8%). The allograft group alone showed that 5 grafts fully incorporated (41.7%), 3 grafts partially incorporated (25%), and 4 grafts did not incorporate (33.3%).

Six patients (13.6%) were considered to have radiographically loose baseplates determined by lucency around the screws or a change in position of the baseplate over time. Extended cage baseplates had been used in 3 of these patients.

Scapular notching of grades 1 to 2 was found in 6 patients (13.6%). Four patients showed humeral lucent lines of 2 mm or less, without evidence of humeral loosening. One patient was felt to have a loose humeral stem.

Complications

The major (clinically significant) complication rate was 13.6%. There were 2 graft failures that caused clinical loosening of the baseplate and required revision. Two infections occurred (1 autograft and 1 allograft). One was revised in a 2-stage procedure, and 1 elected to retain the antibiotic spacer. One patient with clinical humeral loosening required revision (autograft). One postoperative dislocation (autograft) occurred. The patient was treated with a closed reduction in the operating room and immobilized for 6 weeks. No further dislocations occurred.

Other minor (not clinically significant) complications included 6 patients with scapular notching of grades 1 or 2, and 4 patients with radiolucent lines of 2 mm around the humeral

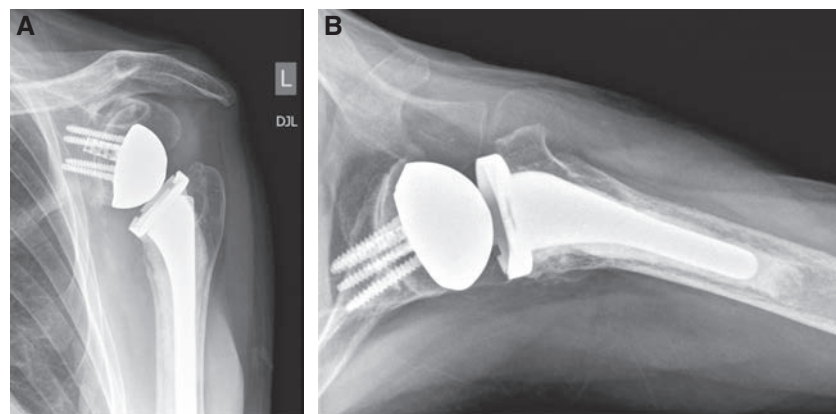


Figure 2 The structural graft is shown behind the glenoid baseplate in (A) anteroposterior and (B) axillary view radiographs. (The screws and cage traverse the graft into the native glenoid).

Table I Average preoperative and postoperative outcome scores of combined reverse total shoulder arthroplasty with an allograft or autograft

Time of assessment	Pain	ASES	Constant	SPADI	SST	Active abduction, °	Active forward flexion, °	Active external rotation, °
Preop, Avg ± SD	6.3 ± 2.3	35.9 ± 17.6	30.1 ± 11.1	85.2 ± 24.4	3.2 ± 2.6	70 ± 28	75 ± 28	14 ± 26
Postop, Avg ± SD	1.9 ± 2.6	74.9 ± 21.8	57.7 ± 14.8	35.0 ± 30.2	8.2 ± 3.5	102 ± 29	116 ± 26	26 ± 20
<i>P</i> value*	<.0001	<.0001	<.0001	<.0001	<.0001	<.0001	<.0001	.0209

ASES, American Shoulder and Elbow Surgeons; SD, standard deviation; SPADI, shoulder pain and disability index; SST, simple shoulder test.

* *P* values <.05 are statistically significant.

Table II Average preoperative and postoperative outcome scores of reverse total shoulder arthroplasty patients with an allograft

Time of assessment	Pain	ASES	Constant	SPADI	SST	Active abduction, °	Active forward flexion, °	Active external rotation, °
Preop, Avg ± SD	6.1 ± 2.7	38.3 ± 16.5	34.6 ± 15.2	81.6 ± 23.0	3.9 ± 2.3	61 ± 32	64 ± 32	24 ± 22
Postop, Avg ± SD	2.8 ± 3.7	72.6 ± 28.9	57.0 ± 15.2	34.1 ± 32.7	8.1 ± 3.2	101 ± 23	116 ± 28	26 ± 16
<i>P</i> value*	.0244	.0028	.0034	.0011	.0053	.0020	.0003	.7728

ASES, American Shoulder and Elbow Surgeons; SD, standard deviation; SPADI, shoulder pain and disability index; SST, simple shoulder test.

* *P* values <.05 are statistically significant.

Table III Average preoperative and postoperative outcome scores of reverse total shoulder arthroplasty patients with an autograft

Time of assessment	Pain	ASES	Constant	SPADI	SST	Active abduction, °	Active forward flexion, °	Active external rotation, °
Preop, Avg ± SD	6.4 ± 2.2	35.0 ± 18.2	28.6 ± 9.3	86.5 ± 25.1	2.9 ± 2.7	73 ± 27	80 ± 26	10 ± 27
Postop, Avg ± SD	1.5 ± 1.9	76.0 ± 18.0	58.0 ± 14.9	35.4 ± 29.5	8.3 ± 3.6	103 ± 31	116 ± 25	26 ± 22
<i>P</i> value	<.0001	<.0001	<.0001	<.0001	<.0001	.0003	<.0001	.0142

ASES, American Shoulder and Elbow Surgeons; SD, standard deviation; SPADI, shoulder pain and disability index; SST, simple shoulder test.

* *P* values <.05 are statistically significant.

stem but without evidence of gross loosening. This resulted in a total complication rate of 36%.

Discussion

Management of glenoid bone loss in shoulder arthroplasty remains a challenge. Severe glenoid bone loss can occur in many

situations, including osteoarthritis, rheumatoid arthritis, cuff tear arthropathy, fractures, chronic instability, congenital deformities, tumors, and revision arthroplasty. Inferior results have been demonstrated with shoulder arthroplasty in the face of significant glenoid wear.^{9,13,16,20,31} Options to address the glenoid wear include hemiarthroplasty that avoids the use of a glenoid implant, eccentric reaming, augmented implants, and bone graft-

Table IV Comparison of average preoperative measurements between reverse total shoulder arthroplasty patients with an allograft and an autograft

Time of assessment	Pain	ASES	Constant	SPADI	SST	Active abduction, °	Active forward flexion, °	Active external rotation, °
Preop allograft, Avg ± SD	6.1 ± 2.7	38.3 ± 16.5	34.6 ± 15.2	81.6 ± 23.0	3.9 ± 2.3	61 ± 32	64 ± 32	24 ± 22
Preop autograft Avg ± SD	6.4 ± 2.2	35.0 ± 18.2	28.6 ± 9.3	86.5 ± 25.1	2.9 ± 2.7	73 ± 27	80 ± 26	10 ± 27
<i>P</i> value	.7363	.6123	.1677	.6072	.4441	.2231	.0992	.1181

ASES, American Shoulder and Elbow Surgeons; *SD*, standard deviation; *SPADI*, shoulder pain and disability index; *SST*, simple shoulder test.

Table V Comparison of average postoperative measurements between reverse total shoulder arthroplasty patients with an allograft and an autograft

Time of assessment	Pain	ASES	Constant	SPADI	SST	Active abduction, °	Active forward flexion, °	Active external rotation, °
Postop allograft, Avg ± SD	2.8 ± 3.7	72.6 ± 28.9	57.0 ± 15.2	34.1 ± 32.7	8.1 ± 3.2	101 ± 23	116 ± 28	26 ± 16
Postop autograft, Avg ± SD	1.5 ± 1.9	76.0 ± 18.0	58.0 ± 14.9	35.4 ± 29.5	8.3 ± 3.6	103 ± 31	116 ± 25	26 ± 22
<i>P</i> value	.1193	.6304	.8479	.9017	.9134	.8399	.9990	.9879

ASES, American Shoulder and Elbow Surgeons; *SD*, standard deviation; *SPADI*, shoulder pain and disability index; *SST*, simple shoulder test.

Table VI Comparison of average improvement between reverse total shoulder arthroplasty patients with an allograft and an autograft

Graft	Pain	ASES	Constant	SPADI	SST	Active abduction, °	Active forward flexion, °	Active external rotation, °
Allograft Avg ± SD	2.7 ± 2.6	29.5 ± 24.6	24.2 ± 19.1	43.0 ± 40.1	4.1 ± 3.0	37 ± 30	47 ± 28	1 ± 35
Autograft Avg ± SD	4.9 ± 3.2	41.0 ± 18.8	29.1 ± 12.8	54.5 ± 21.9	5.1 ± 2.8	30 ± 35	38 ± 32	19 ± 23
<i>P</i> value	.0638	.1357	.3950	.2854	.4782	.5983	.4175	.0869

ASES, American Shoulder and Elbow Surgeons; *SD*, standard deviation; *SPADI*, shoulder pain and disability index; *SST*, simple shoulder test.

Table VII Comparison of average preoperative measurements between patients with an allograft or autograft and follow-up in an age- and gender-matched reverse total shoulder arthroplasty cohort without grafts

Time of assessment	Pain	ASES	Constant	SPADI	SST	Active abduction, °	Active forward flexion, °	Active external rotation, °
Preop graft, Avg ± SD	6.3 ± 2.3	35.9 ± 17.6	30.1 ± 11.1	85.2 ± 24.4	3.2 ± 2.6	70 ± 28	75 ± 28	14 ± 26
Preop no graft, Avg ± SD	6.8 ± 2.3	28.4 ± 19.0	27.9 ± 16.6	83.2 ± 21.4	2.4 ± 3.0	68 ± 35	84 ± 42	15 ± 21
<i>P</i> value	.3623	.0829	.5143	.7526	.2862	.8655	.2715	.8877

ASES, American Shoulder and Elbow Surgeons; *SD*, standard deviation; *SPADI*, shoulder pain and disability index; *SST*, simple shoulder test.

ing in cases where more correction is needed. This has been described with an autograft humeral head, iliac crest, and allograft femoral head. Advantages of this technique include maintenance of proper joint lateralization and preservation of glenoid bone stock. Disadvantages include the technical difficulty, fixation failure, and graft resorption that could secondarily lead to component loosening.

The use of grafts for glenoid defects in anatomic TSA has been well reported. Good results have been achieved, but they have certainly been variable, with high numbers of complications.^{1,6-8,14,15,18,24-27,29,30,32,33,37} More recently, numer-

ous studies have looked at the role of bone grafting with RTSA in the treatment of the deficient glenoid. Short-term results with bone grafting combined with RTSA have been encouraging.

Klein et al¹⁷ compared outcomes of RTSA in patients with and without glenoid bone loss. Of the 56 patients considered to have abnormal glenoids from bone loss, 22 required a bone graft (21 autograft humeral heads and 1 allograft femoral head). No differences were seen in clinical outcomes at the 2-year follow-up between normal and abnormal glenoids. The authors stressed the need for an alteration of

Table VIII Comparison of average postoperative measurements between all combined RTSA patients with an allograft or autograft and an follow-up in an age- and gender-matched reverse total shoulder arthroplasty cohort without grafts

Graft	Pain	ASES	Constant	SPADI	SST	Active abduction,°	Active forward flexion,°	Active external rotation,°
Postop graft, Avg ± SD	1.9 ± 2.6	74.9 ± 21.8	57.7 ± 14.8	35.0 ± 30.2	8.2 ± 3.5	102 ± 29	116 ± 26	26 ± 20
Postop no graft, Avg ± SD	0.6 ± 1.7	88.1 ± 16.3	76.5 ± 13.2	21.5 ± 25.3	10.0 ± 2.5	104 ± 22	146 ± 27	32 ± 17
<i>P</i> value*	.0089	.0019	<.0001	.0514	.0070	.7968	<.0001	.2093

ASES, American Shoulder and Elbow Surgeons; SD, standard deviation; SPADI, shoulder pain and disability index; SST, simple shoulder test.

* *P* values <.05 are statistically significant.

technique to place the baseplate central screw in abnormal glenoids. The screw was placed down the “alternative scapular centerline” to achieve fixation rather than a standard centerline perpendicular to the glenoid face. They reported no evidence of graft failure on postoperative radiographs.

Neyton et al²⁵ reported outcomes in 9 patients who underwent glenoid bone grafting with an autograft humeral head or iliac crest combined with RTSA. Constant scores, range of motion, and pain scores improved in all patients. No incidence of radiographic loosening occurred at the 2-year follow-up.

Boileau et al³ described the use of humeral head autograft to improve lateralization of the center of rotation. They used a 7- to 10-mm graft and an extended post on the baseplate. Screws through the baseplate achieved fixation as well. They achieved a 98% incorporation rate, with no loosening or revisions 28 months postoperatively.

Melis et al²¹ looked at 37 anatomic TSAs requiring revisions to RTSA; of these, 29 required a bone graft consisting of a structural iliac crest or cancellous autograft, and 3 allografts were used. At the mean follow-up of 47 months, 76% of the grafts incorporated. Melis et al²¹ reported a postoperative complication rate of 30% with a 22% repeat revision rate. Recurrent glenoid loosening occurred in 3 of these patients and was considered to be related to the use of a short peg in the baseplate that did not extend past the graft into the native bone. Reimplantation with a long peg baseplate was performed in 2 patients. The authors did not differentiate the results of allografts compared with autografts.

Werner et al³⁶ reported outcomes of RTSA for long-standing anterior shoulder dislocation with severe anterior glenoid bone loss. They reviewed 21 patients who received a humeral head autograft to the glenoid. At the latest follow-up, all patients showed improvement in functional scores. Two graft failures occurred, 1 of which was thought to be related to the use of a peg that was too short. The authors emphasized the use of an extended peg on the baseplate for success.

Bateman and Donald² reported the use of a hybrid grafting technique consisting of an allograft femoral neck packed with cancellous autograft in 5 patients. An extended center peg was used in all cases, and they reported no loosening or implant failures at the minimum 12-month follow-up. All grafts incorporated as early as 6 months. Walker et al³⁵ reported outcomes in 24 patients with revision of failed TSAs using RTSA. Ten patients required structural allograft femoral head grafts to the

glenoid. The authors showed improved outcomes in the cohort as a whole but also separated the group with structural allografts to the glenoid for comparison with those without glenoid grafts. The patients who required grafts showed no difference in outcomes to those that did not require grafts. Radiographically, 9 of 10 showed incorporation of the grafts at final follow-up.

The greatest advantage of RTSA for large glenoid deficiencies is that it allows reconstruction of the glenoid with large structural grafts that can be fixed to the native bone with baseplate screws and an extended peg or cage traversing the graft into native bone. This may allow a high graft union rate regardless of whether the graft is an autograft or allograft. Criteria for 1-stage revision with glenoid bone loss using allograft have been reported as good bone quality, a portion of the central peg or screw in the native bone, and the graft supported through 70% to 75% of its circumference by the native glenoid vault.³⁵ Although no accepted guidelines exist, we agree with these general criteria. However, the amount of graft support was not quantified objectively at the time of surgery in this study, and some of the grafts in this series may not have had 75% of the graft supported.

Our radiographic data show a graft incorporation rate in line with prior reports, with 81% of grafts showing complete or partial graft incorporation. The autograft group did show a higher rate of graft incorporation (86% complete or partial incorporation vs. 66.6% for allografts). However, the large difference between sample sizes of each group, the small numbers overall, and the categorical nature of the radiographic assessment make it difficult to tell whether this is a significant difference at this time. Of the 6 glenoids that were considered radiographically loose, 2 were allograft femoral head grafts, and the others were autograft humeral head grafts. Only 2 of these patients, however, were symptomatic and required revision. Both patients who required revision were in the autograft humeral head graft group. The remaining 4 patients could certainly be considered at risk for future failure of the baseplate and continued follow-up is necessary.

It must be noted that how much graft incorporation is necessary for stability of the implant is not known and that using radiographs to assess how much graft is remaining is difficult. Our category of “no incorporation” is actually 25% or less incorporation of the graft. Some of the graft could certainly be providing stability, and this could explain that although there appears to be a significant amount of resorption of some of the

grafts, very few showed clinical symptoms and needed revision. Also of note is that an extended cage baseplate was used in 13 of 44 patients to span the graft into the native bone. One of these patients (7%) showed no incorporation of the graft. The graft in 3 of 31 patients (10%) who received the standard caged baseplate was shown to be unincorporated.

Our view is that RTSA presents a more favorable environment for graft incorporation compared with anatomic TSA. This is due to the ability to achieve graft compression and fixation with screws placed through the baseplate in conjunction with a long peg or cage into the native glenoid. To our knowledge, this is the largest reported series of structural grafts used to reconstruct significant glenoid deficiencies during RTSA. This is also the first study to compare results of autograft vs. allograft reconstructions. All patients received a bulk structural graft using the baseplate and its screws for fixation. Significant improvement from the preoperative function occurred in all subjective and objective measures at a mean of 40.6 months of follow-up for both groups. Furthermore, no differences were demonstrated in postoperative results between the autograft humeral head/iliac crest reconstructions and the allograft femoral head reconstructions.

It should be noted that 8 of the 14 allografts were revision cases, whereas only 1 of the 30 autografts were revisions. Although revisions may certainly be predisposed to poorer outcomes, the finding that no significant differences were seen in postoperative measures between the 2 graft groups, despite a disproportionate amount of revisions in the allograft group, was striking. This underscores the frequent severity of glenoid deformity in these patients and the difficulty of this type of reconstruction, regardless of whether it is a revision or primary case.

Another important observation was that, unlike the results reported by Walker et al,³⁵ the bone graft group as a whole did not perform as well as the age- and sex-matched control cohort that required no bone grafts. The differences in the preoperative measurements in the 2 groups were not significant; therefore, we can conclude that although the RTSA with bone graft does show significant improvements, these patients still do not reach the same level of improvement as those who do not require bone grafts. Again, it is noteworthy that 9 revisions were required in the bone graft cohort. This may bias the bone graft cohort toward worse results and explain some of the drastic differences from the control cohort as well as the differences in our results vs. those reported by Walker et al³⁵

The difficulty of treating patients with these large defects is also demonstrated by our overall complication rate of 36%. However, only 13.6% of the complications were clinically significant and required further treatment. The others were asymptomatic radiographic findings. These patients will need continued follow-up because the radiographic findings could indicate impending loosening.

This series adds to the existing body of literature by showing good results with use of structural grafts to reconstruct large glenoid deficiencies in RTSA. Furthermore, we offer new evidence that allograft reconstructions may perform

equally as well as autograft reconstructions. This would allow for large allografts to be used in some situations, thereby avoiding the potential for donor site morbidity when the iliac crest is used as an autograft.

The present study has several limitations. It is a retrospective multicenter study involving 3 surgeons. This may introduce some inherent variability in technique, rehabilitation, and data collection.

Secondly, we did not use advanced imaging, such as computed tomography scans, to assess graft incorporation. Rather, we relied on standard radiographs to assess graft resorption and baseplate stability/loosening, as other studies have done.

Finally, our follow-up was relatively short. That longer-term follow-up may reveal changes not evident 2 years postoperatively is possible. It is noteworthy, however, that each of the patients with clinical loosening experienced the loosening within the 2-year postoperative window. Using the ongoing data registry, we continue to collect clinical and radiographic information.

Conclusion

An autograft humeral head/iliac crest or allograft femoral head may be used during RTSA to reconstruct large glenoid defects. Excellent clinical outcomes can be expected, as evidenced by improvements in postoperative function and clinical outcome measures 2 years postoperatively. However, final results may not equal those of patients undergoing RTSA without the need for bone graft. Using a baseplate with a long peg or cage to span the graft into the native glenoid is important.

Disclaimer

Richard B. Jones, Thomas W. Wright, and Joseph D. Zuckerman are paid consultants for Exactech, Inc. and receive royalties from Exactech, Inc.

References

1. Antuna SA, Sperling JW, Cofield RH, Rowland CM. Glenoid revision surgery after total shoulder arthroplasty. *J Shoulder Elbow Surg* 2001;10:217-24.
2. Bateman E, Donald S. Reconstruction of massive unconfined glenoid defects using a combined autograft-allograft construct with reverse shoulder arthroplasty: preliminary results. *J Shoulder Elbow Surg* 2012;21:925-34. <http://dx.doi.org/10.1016/j.jse.2011.07.009>
3. Boileau P, Moineau G, Roussanne Y, O'Shea K. Bony increased-offset reversed shoulder arthroplasty: minimizing scapular impingement while maximizing glenoid fixation. *Clin Orthop Relat Res* 2011;469:2558-67. <http://dx.doi.org/10.1007/s11999-011-1775-4>
4. Boileau P, Watkinson D, Hatzidakis AM, Hovorka I. Neer Award 2005: the Grammont reverse shoulder prosthesis: results in cuff tear arthritis,

- fracture sequelae and revision arthroplasty. *J Shoulder Elbow Surg* 2006;15:527-40. <http://dx.doi.org/10.1016/j.jse.2006.01.003>
5. Boileau P, Watkinson DJ, Hatzidakis AM, Balg F. Grammont reverse prosthesis: design, rationale and biomechanics. *J Shoulder Elbow Surg* 2005;14:S147-61. <http://dx.doi.org/10.1016/j.jse.2004.10.006>
 6. Cheung EV, Sperling JW, Cofield RH. Reimplantation of a glenoid component following component removal and allogenic bone-grafting. *J Bone Joint Surg Am* 2007;89:1777-83. <http://dx.doi.org/10.2106/JBJS.F.00711>
 7. De Biase CF, Ziveri G, Dr Caro F, Roberts N, Delcogliano M. Reverse shoulder arthroplasty using a "L" shaped allograft for glenoid reconstruction in a patient with massive glenoid bone loss: case report. *Eur Rev Med Pharmacol Sci* 2014;18:44-9.
 8. Elhassan B, Ozbaydar M, Higgins LD, Warner JJ. Glenoid reconstruction in revision shoulder arthroplasty. *Clin Orthop Relat Res* 2008;466:599-607. <http://dx.doi.org/10.1007/s11999-007-0108-0>
 9. Farron A, Terrier A, Büchler P. Risks of loosening of a prosthetic glenoid implanted in retroversion. *J Shoulder Elbow Surg* 2006;15:521-6. <http://dx.doi.org/10.1016/j.jse.2005.10.003>
 10. Frankle MA, Teramoto A, Lou ZP, Levy JC, Pupello D. Glenoid morphology in reverse shoulder arthroplasty: classification and surgical implications. *J Shoulder Elbow Surg* 2009;18:874-85. <http://dx.doi.org/10.1016/j.jse.2009.02.013>
 11. Gerber C, Pennington SD, Nyffeler RW. Reverse total shoulder arthroplasty. *J Am Acad Orthop Surg* 2009;17:8284-95.
 12. Grammont PM, Trouilloud P, Laffey JP, Deries X. [Concept study and realization of new total shoulder prosthesis]. *Rhumatologie* 1987;39:407-18.
 13. Hasan SS, Leith JM, Campbell B, Kapil R, Smith KL, Matsen FA III. Characteristics of unsatisfactory shoulder arthroplasties. *J Shoulder Elbow Surg* 2002;11:431-41. <http://dx.doi.org/10.1067/mse.2002.125806>
 14. Hill JM, Norris TR. Long-term results of total shoulder arthroplasty following bone-grafting of the glenoid. *J Bone Joint Surg Am* 2001;83:877-83.
 15. Hoffelner T, Moroder P, Auffarth A, Tauber M, Resch H. Outcomes after shoulder arthroplasty revision with glenoid reconstruction and bone grafting. *Int Orthop* 2014;38:775-82. <http://dx.doi.org/10.1007/s00264-013-2191-z>
 16. Iannotti JP, Norris TR. Influence of preoperative factors on outcome of shoulder arthroplasty for glenohumeral osteoarthritis. *J Bone Joint Surg Am* 2003;85:251-8.
 17. Klein SM, Dunning P, Mulieri P, Pupello D, Downes K, Frankle MA. Effects of acquired glenoid bone defects on surgical technique and clinical outcomes in reverse shoulder arthroplasty. *J Bone Joint Surg Am* 2010;92:1144-54. <http://dx.doi.org/10.2106/JBJS.I.00778>
 18. Klika BJ, Wooten CW, Sperling JW, Steinmann SP, Schleck CD, Harnsen WS, et al. Structural bone grafting for glenoid deficiency in primary total shoulder arthroplasty. *J Shoulder Elbow Surg* 2014;23:1066-72. <http://dx.doi.org/10.1016/j.jse.2013.09.017>
 19. Laver L, Garrigues GE. Avoiding superior tilt in reverse shoulder arthroplasty: a review of the literature and technical recommendations. *J Shoulder Elbow Surg* 2014;23:1582-90. <http://dx.doi.org/10.1016/j.jse.2014.06.029>
 20. Levine WN, Djurasovic M, Glasson J, Pollock RG, Glatow EL, Bigliani LU. Hemiarthroplasty for glenohumeral osteoarthritis: results correlated to degree of glenoid wear. *J Shoulder Elbow Surg* 1997;6:449-54.
 21. Melis B, Bonneville N, Neyton L, Lévine C, Favard L, Walch G, et al. Glenoid loosening and failure in anatomical total shoulder arthroplasty: is revision with a reverse shoulder arthroplasty a reliable option? *J Shoulder Elbow Surg* 2012;21:342-9. <http://dx.doi.org/10.1016/j.jse.2011.05.021>
 22. Mizuno N, Denard PJ, Raiss P, Walch G. Reverse total shoulder arthroplasty for primary glenohumeral osteoarthritis in patient with biconcave glenoid. *J Bone Joint Surg Am* 2013;95:1297-304. <http://dx.doi.org/10.2106/JBJS.L.00820>
 23. Moskal MJ, Duckworth D, Matsen FA. Abstract: an analysis of 122 failed shoulder arthroplasties. *J Shoulder Elbow Surg* 1999;8:554.
 24. Neer CS 2nd, Morrison DS. Glenoid bone grafting in total shoulder arthroplasty. *J Bone Joint Surg Am* 1988;70:1154-62.
 25. Neyton L, Boileau P, Nové-Josserand L, Edwards TB, Walch G. Glenoid bone grafting with a reverse design prosthesis. *J Shoulder Elbow Surg* 2007;16:S71-8. <http://dx.doi.org/10.1016/j.jse.2006.02.002>
 26. Neyton L, Walch G, Nové-Josserand L, Edwards TB. Glenoid corticocancellous bone grafting after glenoid component removal in the treatment of glenoid loosening. *J Shoulder Elbow Surg* 2006;15:173-6. <http://dx.doi.org/10.1016/j.jse.2005.07.010>
 27. Phipatanakul WP, Norris TR. Treatment of glenoid loosening and bone loss due to osteolysis with glenoid bone grafting. *J Shoulder Elbow Surg* 2006;15:84-7. <http://dx.doi.org/10.1016/j.jse.2005.06.004>
 28. Roche CP, Diep P, Hamilton M, Crosby LA, Flurin PH, Wright TW, et al. Impact of inferior glenoid tilt, humeral retroversion, bone grafting, and design parameters on muscle length and deltoid wrapping in reverse shoulder arthroplasty. *Bull Hosp Jt Dis* 2013;71:284-93.
 29. Sabesan V, Callanan M, Ho J, Iannotti JP. Clinical and radiographic outcomes of total shoulder arthroplasty with bone graft for osteoarthritis with severe glenoid bone loss. *J Bone Joint Surg Am* 2013;95:1290-6. <http://dx.doi.org/10.2106/JBJS.L.00097>
 30. Scalise JJ, Iannotti JP. Bone grafting severe glenoid defects in revision shoulder arthroplasty. *Clin Orthop Relat Res* 2008;466:139-45. <http://dx.doi.org/10.1007/s11999-007-0065-7>
 31. Shapiro TA, McGarry MH, Gupta R, Lee YS, Lee TQ. Biomechanical effects of glenoid retroversion in total shoulder arthroplasty. *J Shoulder Elbow Surg* 2007;16:S90-5. <http://dx.doi.org/10.1016/j.jse.2006.07.010>
 32. Steinmann SP, Cofield RH. Bone grafting for glenoid deficiency in total shoulder replacement. *J Shoulder Elbow Surg* 2000;9:361-7.
 33. Walch G, Moraga C, Young A, Castellanos-Rosas J. Results of anatomic nonconstrained prosthesis in primary osteoarthritis with biconcave glenoid. *J Shoulder Elbow Surg* 2012;21:1526-33. <http://dx.doi.org/10.1016/j.jse.2011.11.030>
 34. Walch G, Badet R, Boulahia A, Khoury A. Morphologic study of the glenoid in primary glenohumeral osteoarthritis. *J Arthroplasty* 1999;14:756-60.
 35. Walker M, Willis MP, Brooks JP, Pupello D, Mulieri PJ, Frankle MA. The use of the reverse shoulder arthroplasty for treatment of failed total shoulder arthroplasty. *J Shoulder Elbow Surg* 2012;21:514-22. <http://dx.doi.org/10.1016/j.jse.2011.03.006>
 36. Werner BS, Bohm D, Abdelkawi A, Gohlke F. Glenoid bone grafting in reverse shoulder arthroplasty for long-standing anterior shoulder dislocation. *J Shoulder Elbow Surg* 2014;23:1655-61. <http://dx.doi.org/10.1016/j.jse.2014.02.017>
 37. Williams GR Jr, Iannotti JP. Options for glenoid bone loss: composites of prosthetics and biologics. *J Shoulder Elbow Surg* 2007;19:S267-72. <http://dx.doi.org/10.1016/j.jse.2007.05.003>



Comparison of reverse total shoulder arthroplasty outcomes with and without subscapularis repair



Richard J. Friedman, MD, FRCS^{a,*}, Pierre-Henri Flurin, MD^b, Thomas W. Wright, MD^c, Joseph D. Zuckerman, MD^d, Christopher P. Roche, MSE, MBA^e

^aDepartment of Orthopaedics, Medical University of South Carolina, Charleston, SC, USA

^bDepartment of Orthopaedic Surgery, Clinique du Sport de Bordeaux-Mérignac, Mérignac, France

^cDepartment of Orthopaedic Surgery, University of Florida, Gainesville, FL, USA

^dDepartment of Orthopaedic Surgery, NYU Langone Medical Center, New York, NY, USA

^eExactech, Gainesville, FL, USA

Background: Repair of the subscapularis with reverse total shoulder arthroplasty (rTSA) is controversial. The purpose of this study is to quantify rTSA outcomes in patients with and without subscapularis repair to determine if there is any impact on clinical outcomes.

Methods: Three hundred forty patients received rTSA and had the subscapularis repaired, whereas 251 patients received rTSA and did not have the subscapularis repaired. The patients were scored preoperatively and at latest follow-up using the Simple Shoulder Test; University of California, Los Angeles; American Shoulder and Elbow Surgeons; Constant; and Shoulder Pain and Disability Index metrics. Motion was also measured. Mean follow-up was 37 months.

Results: All patients showed significant improvements in pain and function after treatment with rTSA. For both cohorts, American Shoulder and Elbow Surgeons and Constant scores significantly improved, as did range of motion. The repaired cohort had significantly higher postoperative scores as measured by 4 of the 5 metrics and significantly more internal rotation, whereas the non-repaired cohort had significantly more active abduction and passive external rotation. The complication rate was 7.4% (0% dislocations) for the subscapularis-repaired cohort and 6.8% (1.2% dislocations) for the non-subscapularis-repaired cohort.

Conclusions: Significant clinical improvements were observed for both the subscapularis-repaired and non-repaired cohorts, with some statistical differences observed using a variety of outcome measures. Repair of the subscapularis did not lead to inferior clinical outcomes as predicted by biomechanical models. No difference was noted in the complication or scapular notching rates between cohorts. These clinical results show that rTSA using a lateralized humeral prosthesis delivers reliable clinical improvements with a low risk of instability, regardless of subscapularis repair.

Level of evidence: Level III; Retrospective Cohort Design; Treatment Study

© 2016 Journal of Shoulder and Elbow Surgery Board of Trustees. All rights reserved.

Keywords: Shoulder; arthroplasty; reverse; subscapularis; dislocation; complications

Approved by the Medical University of South Carolina Institutional Review Board (protocol MS1_Pro00030914).

*Reprint requests: Richard J. Friedman, MD, FRCS, Medical University of South Carolina, 96 Jonathan Lucas St, CSB 708, MSC 622, Charleston, SC 29425, USA.

E-mail address: friedman@musc.edu (R.J. Friedman).

Reverse total shoulder arthroplasty (rTSA) has been used in the United States since 2003 to treat a variety of shoulder conditions, with good to excellent results in the vast majority of patients.^{4,14} This has been accomplished with 3 basic

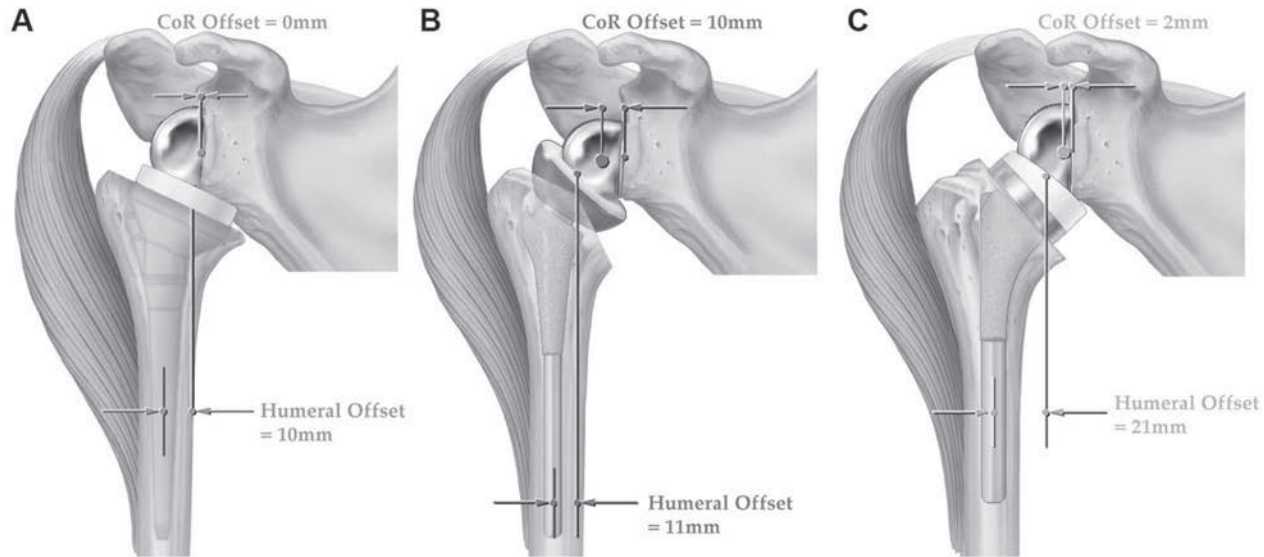


Figure 1 Drawings showing the differences among 3 different types of reverse total shoulder arthroplasty and the location of both the center of rotation (CoR) and the relative lateral displacement of the humerus based on the design of the implant: Grammont Delta III Reverse Shoulder, Depuy, Warsaw, IN (medial glenoid and medial humerus) (A), RSP Reverse Shoulder, DJO Surgical, Austin, TX (lateral glenoid and medial humerus) (B); and Equinoxe Reverse Shoulder (medial glenoid and lateral humerus) (C). Reprinted from: Routman HD, Flurin PH, Wright T, Zuckerman J, Hamilton M, Roche C. Reverse shoulder arthroplasty prosthesis design classification system. *Bull Hosp Jt Dis* 2015;73(Suppl 1):S5-14. With permission.

different prosthetic designs that influence the biomechanics of the shoulder and potentially the functional outcomes of the arthroplasty (Fig. 1). However, it remains controversial whether the subscapularis should be repaired or not in rTSA. Some studies have suggested that the risk of instability is increased if the subscapularis is not repaired with a prosthetic design that medializes the center of rotation and position of the humerus relative to the glenoid.³ Edwards et al³ reported a 5.1% dislocation rate with the Grammont prosthesis and concluded that the relative rate of dislocation with rTSA is doubled if the subscapularis is not repaired. Other studies have not found an increased risk of instability or complications if the subscapularis is not repaired using a prosthesis that lateralizes the center of rotation.² Clark et al² reported a 4.1% dislocation rate with the Reverse Shoulder Prosthesis (DJO, Vista, CA, USA), where 5.5% dislocations were reported for patients with the subscapularis repaired and 3.1% without repair. In addition, there are biomechanical studies that have reported that not repairing the subscapularis requires significantly less force to be generated by the deltoid and the posterior rotator cuff throughout arm abduction.⁶ If the subscapularis was repaired, the joint reaction force increased by 28%, the required deltoid force increased by 14%, and the required posterior rotator cuff force increased by 34%.⁶ Subscapularis repair is likely a function of prosthesis design and the position of the humerus relative to the glenoid center of rotation.

Reasons for repairing the subscapularis include anatomic preservation of a functioning rotator cuff muscle, an increased potential for internal rotation and therefore improved function, improved joint protection with better closure

of the joint, and improved stability of the arthroplasty. Theoretical reasons for not repairing the subscapularis include the following: it may be biomechanically unfavorable for deltoid function because with rTSA, the subscapularis functions as an adductor instead of an abductor as with an anatomic total shoulder arthroplasty, thus counteracting the work of the deltoid; it may be biomechanically unfavorable for the posterior rotator cuff as there are only 2 external rotators in the body that are often compromised, and not repairing the subscapularis minimizes the force required by these muscles to generate external rotation; and it may be unnecessary for stability in rTSA designs that lateralize the humerus, better tension the posterior rotator cuff, and improve deltoid wrapping.^{6,9,10}

Clearly, the issue regarding repairing the subscapularis in rTSA is unclear, with few data in the literature to guide the clinician on what is most appropriate to achieve the best possible clinical outcome for the patient. The purpose of this study, therefore, is to determine if not repairing the subscapularis affects the clinical outcomes as measured by a variety of outcome scoring metrics and range of motion. The null hypothesis is that not repairing the subscapularis does not affect clinical outcomes as measured by range of motion and outcome scoring metrics.

Materials and methods

A multinational database was analyzed to quantify rTSA outcomes in patients with and without subscapularis repair, with a minimum follow-up of 24 months, to determine if repair has any impact on outcomes with a modern rTSA lateral humerus prosthesis design. Preoperative and postoperative data were analyzed from

591 patients (mean age, 72.5 years; age range, 50-93 years) who received primary rTSA for cuff tear arthropathy, rotator cuff tearing with osteoarthritis, and/or rheumatoid arthritis, with a minimum of 2 years' follow-up (mean follow-up, 36.6 months), for whom data on whether the subscapularis was repaired or not were available. Twelve surgeons performed these operations; each surgeon contributed patients to each cohort, though the number for each surgeon varied. The surgical approach, management of the subscapularis release and repair (when done), and postoperative rehabilitation were up to the individual surgeon.

Three hundred forty patients (221 female patients with a mean age of 73.2 years and body mass index [BMI] of 26.8 and 119 male patients with a mean age of 72.2 years and BMI of 26.6) received a primary Equinox rTSA shoulder (Exactech, Gainesville, FL, USA) for treatment of CTA, RCT-OA, and/or RA and underwent subscapularis repair (mean age, 72.9 years). Two hundred fifty-one patients (146 female patients with a mean age of 72.9 years and BMI of 28.9 and 105 male patients with a mean age of 70.5 years and BMI of 30.1) received a primary Equinox rTSA shoulder for treatment of CTA, RCT-OA, and/or RA and did not undergo subscapularis repair (mean age, 71.9 years). The patients were evaluated and scored preoperatively and at latest follow-up using the Simple Shoulder Test (SST); University of California, Los Angeles (UCLA); American Shoulder and Elbow Surgeons (ASES); Constant; and Shoulder Pain and Disability Index scoring metrics. Active abduction, forward flexion, and external rotation were also measured. Internal rotation was measured by vertebral segments and was scored by the following discrete assignment: 0 degrees, 0; hip, 1; buttocks, 2; sacrum, 3; L4 to L5, 4; L1 to L3, 5; T8 to T12, 6; and T7 or higher, 7. Radiographic information was available for 72.4% of patients (251 of 340 patients in the subscapularis-repaired cohort and 177 of 251 patients in the non-subscapularis-repaired cohort). Scapular notching was assessed at latest clinical follow-up by the implanting surgeon from a combination of anteroposterior or Grashey and axillary radiographs using the Nerot-Sirveaux grading scale.¹² The average follow-up for rTSA patients with subscapularis repair was 37.3 months, and the average follow-up for rTSA patients without subscapularis repair was 35.7 months. The Anderson-Darling test for normality was performed, finding a nonparametric distribution of the data; for this reason, subsequent statistical analysis was performed using nonparametric tests. Specifically, the Mann-Whitney test was used to identify differences in preoperative and postoperative results, where $P < .05$ denoted a significant difference.

Results

All patients showed significant improvements in pain and function after treatment with rTSA regardless of whether the subscapularis was repaired. Some differences were noted between cohorts. The patients in the subscapularis-repaired cohort weighed significantly less (74 kg vs 82 kg, $P < .0001$) and had a significantly lower BMI (26.7 vs 29.4, $P < .0001$), and though not significant, the subscapularis-repaired cohort trended toward being older at the time of surgery (72.9 years vs 71.9 years, $P = .1015$) and had a higher percentage of female patients (65.0% vs 58.2%, $P = .0909$), as compared with the non-subscapularis-repaired cohort. For the subscapularis-repaired cohort, ASES scores significantly improved from a preoperative mean of 39 to a postoperative mean of 87; Con-

stant scores significantly improved from 35 to 73; active forward flexion significantly improved from 91° to 141°; and active external rotation significantly improved from 13° to 34°. For the non-subscapularis-repaired cohort, ASES scores significantly improved from 35 to 82; Constant scores significantly improved from 34 to 68; active forward flexion significantly improved from 85° to 137°; and active external rotation significantly improved from 20° to 35° (Tables I and II).

The subscapularis-repaired cohort had significantly higher preoperative scores as measured by ASES and UCLA metrics but significantly less active abduction ($P = .0200$) as well as active ($P = .0001$) and passive ($P = .0002$) external rotation relative to the non-repaired cohort. In addition, the repaired cohort had significantly higher postoperative scores as measured by 4 of the 5 metrics and significantly more internal rotation ($P < .0001$), whereas the non-repaired cohort had significantly more active abduction ($P < .0001$) and passive external rotation ($P < .0001$). Finally, the repaired cohort had significantly greater improvement in the SST and Constant metrics as well as significantly more improvement in active internal ($P = .0030$) and external ($P = .0045$) rotation (Table III).

The database contained 25 complications for the rTSA patients in the subscapularis-repaired cohort, for a complication rate of 7.4%. The database contained 17 complications for the rTSA patients who did not have the subscapularis repaired, for a complication rate of 6.8%. It should be noted that 3 of the 17 complications in the non-repaired cohort were for instability (non-repaired instability rate of 1.2%) whereas 0 of the 25 complications in the repaired cohort were for instability (repaired instability rate of 0%). The overall rTSA instability rate was 0.5% (3 of 591). Table IV presents a detailed description of complications for each cohort. In addition, the rTSA subscapularis-repaired cohort had a scapular notching rate of 10.4% (grade 0 in 225, grade 1 in 21, grade 2 in 2, grade 3 in 3, and grade 4 in 0), with an average scapular notching grade of 0.14; whereas the rTSA non-subscapularis-repaired cohort had a scapular notching rate of 10.7% (grade 0 in 158, grade 1 in 14, grade 2 in 4, grade 3 in 1, and grade 4 in 0), with an average scapular notching grade of 0.14. No significant differences were noted in the rate of complications, the rate of scapular notching, or the grade of scapular notching between cohorts.

Discussion

This study is the largest to date that compares rTSA outcomes with and without subscapularis repair. Treatment with rTSA significantly improved all 5 outcome score measurements and all 4 motion measurements regardless of repair. When compared with previous studies published in the literature, regardless of subscapularis repair or not, the outcome scores compare favorably^{1,5,7,8,12,13,15} (Table V). Although the preoperative ASES and Constant scores are similar, the postoperative scores are higher than those reported. With regard to range of motion reported in the literature, postoperative

Table I Comparison of average preoperative measurements in rTSA patients with and without subscapularis repair

	SST	UCLA	ASES	Constant	SPADI	Active abduction, °	Active forward flexion, °	Internal rotation score	Active external rotation, °	Passive external rotation, °	Maximum weight, kg
Repair	3.4 ± 2.6	13.7 ± 3.7	38.8 ± 13.7	34.8 ± 13.4	80.2 ± 21.8	67 ± 35	91 ± 42	3.3 ± 1.7	13 ± 22	23 ± 21	0.6 ± 1.1
No repair	3.3 ± 2.7	12.7 ± 4.2	34.9 ± 17.5	33.8 ± 14.3	84.6 ± 21.8	75 ± 36	85 ± 37	3.2 ± 1.8	20 ± 23	31 ± 25	0.5 ± 1.2
P value	.6510	.0041*	.0009*	.3581	.0712	.0200*	.1160	.6091	.0001*	.0002*	.0654

Data are presented as mean ± standard deviation.

ASES, American Shoulder and Elbow Surgeons; rTSA, reverse total shoulder arthroplasty; SPADI, Shoulder Pain and Disability Index; SST, Simple Shoulder Test; UCLA, University of California, Los Angeles.

* Statistically significant.

Table II Comparison of average postoperative measurements in rTSA patients with and without subscapularis repair

	SST	UCLA	ASES	Constant	SPADI	Active abduction, °	Active forward flexion, °	Internal rotation score	Active external rotation, °	Passive external rotation, °	Maximum weight, kg
Repair	10.5 ± 2.2	30.2 ± 4.5	86.7 ± 15.8	72.9 ± 12.5	15.9 ± 19.6	107 ± 23	141 ± 24	5.1 ± 1.3	34 ± 15	45 ± 16	3.9 ± 2.3
No repair	9.6 ± 2.8	29.7 ± 5.2	82.1 ± 18.2	67.9 ± 14.6	23.5 ± 25.3	119 ± 31	137 ± 29	4.4 ± 1.6	35 ± 19	50 ± 17	2.9 ± 2.6
P value	.0001*	.8108	.0008*	<.0001*	.0002*	<.0001*	.1292	<.0001*	.7783	.0028*	<.0001*

Data are presented as mean ± standard deviation.

ASES, American Shoulder and Elbow Surgeons; rTSA, reverse total shoulder arthroplasty; SPADI, Shoulder Pain and Disability Index; SST, Simple Shoulder Test; UCLA, University of California, Los Angeles.

* Statistically significant.

Table III Comparison of average improvement in rTSA patients with and without subscapularis repair

	SST	UCLA	ASES	Constant	SPADI	Active abduction, °	Active forward flexion, °	Internal rotation score	Active external rotation, °	Passive external rotation, °	Maximum weight, kg
Repair	7.1 ± 3.1	16.7 ± 5.4	47.7 ± 18.5	38.3 ± 16.3	63.2 ± 26.1	41 ± 36	50 ± 46	1.8 ± 1.9	22 ± 24	22 ± 22	3.3 ± 2.2
No repair	6.1 ± 3.5	17.0 ± 6.1	46.4 ± 22.2	32.7 ± 17.8	58.5 ± 30.4	45 ± 42	51 ± 44	1.2 ± 2.1	16 ± 26	19 ± 25	2.1 ± 2.2
P value	.0009*	.3709	.6805	.0006*	.1181	.3563	.8909	.0030*	.0045*	.0634	< .0001*

Data are presented as mean ± standard deviation.
 ASES, American Shoulder and Elbow Surgeons; rTSA, reverse total shoulder arthroplasty; SPADI, Shoulder Pain and Disability Index; SST, Simple Shoulder Test; UCLA, University of California, Los Angeles.
 * Statistically significant.

active forward flexion and external rotation are comparable regardless of subscapularis repair (Table VI). Clearly, the results of rTSA have improved over time as the procedure has become more widespread and the outcomes more consistent and reliable.

The subscapularis-repaired cohort had significantly higher preoperative scores as measured by ASES and UCLA metrics but significantly less active abduction and external rotation preoperatively relative to the non-repaired cohort. The subscapularis-repaired cohort had significantly higher post-operative scores as measured by 4 of the 5 metrics and significantly more internal rotation but less active abduction and passive external rotation. The subscapularis-repaired cohort was associated with significantly larger improvements in outcome scores according to the SST and Constant metrics and was significantly more effective at improving active internal and external rotation. Although these aforementioned differences between cohorts were statistically significant, it is important to note that these findings may not be clinically meaningful, as the average difference between each of the mean measurements is in every case less than the standard deviation (which is one measure of a “clinically meaningful difference”). The number of patients in each cohort emphasizes the power of this clinical database study, and the results suggest that, using this particular lateral humerus–medial glenoid rTSA prosthesis, clinical improvement with a low complication rate can be achieved regardless of whether the subscapularis is repaired.

The decision to repair the subscapularis may be implant specific. These results show that positive outcomes, with regard to both range of motion and outcome scores, are achievable both with and without subscapularis repair using an rTSA prosthesis design that lateralizes the humerus. A lateralized humerus rTSA prosthesis is associated with increased deltoid wrapping and more anatomic rotator cuff tensioning, both of which contribute to stability.^{9,10} It should be noted that the overall rate of instability in this study was only 0.5% (3 of 591), with both the subscapularis-repaired and non-repaired cohorts having a lower dislocation rate than previously reported.^{2,3} Thus, these findings related to stability with or without subscapularis repair may not be transferrable to rTSA prosthesis designs that do not lateralize the humerus.

This study has several limitations. It retrospectively reports on the short-term clinical results of a single-platform reverse shoulder system with an average follow-up of just over 3 years. Clinical results change with time, and longer-term clinical follow-up for rTSA with and without subscapularis repair is necessary. Furthermore, this study was not randomized or controlled, and as a result, there is selection bias. The decision to repair or not repair the subscapularis was left up to the individual surgeon, based on the surgeon’s preferences and judgment. Some patients clearly did not have a subscapularis to repair and therefore automatically fell into the non-repaired group, whereas others had a subscapularis able to be repaired but the repair was not performed based on the choice of the operating surgeon. In addition, the findings related

Table IV Comparison of complications for non–subscapularis-repaired and subscapularis-repaired cohorts

	Non–subscapularis-repaired cohort	Subscapularis-repaired cohort
Complication		
Instability	3 (1.2%)	0 (0%)
Periprosthetic humeral fracture	3 (1.2%)	4 (1.2%)
Scapular spine fracture	3 (1.2%)	2 (0.6%)
Radiographically loose glenoid	2 (0.8%)	2 (0.6%)
Unexplained pain	2 (0.8%)	1 (0.3%)
Infection	1 (0.4%)	5 (1.5%)
Loose humeral prosthesis	1 (0.4%)	2 (0.6%)
Deltoid or pectoralis muscle strain	1 (0.4%)	0 (0%)
Acromial pain	1 (0.4%)	1 (0.3%)
Pain after fall (no shoulder fracture)	0 (0%)	4 (1.2%)
Stiff shoulder	0 (0%)	3 (0.9%)
Pulmonary embolism	0 (0%)	1 (0.3%)
Overall complications	17 of 251 (6.8%)	25 of 340 (7.4%)

Table V Comparison of rTSA shoulder outcome scores reported in literature

Study	Sample size	Follow-up, mo	Average Constant score		Average ASES score	
			Preoperative	Postoperative	Preoperative	Postoperative
Sirveaux et al, ¹² 2004	N = 77	44	22.6	65.5	NR	NR
Werner et al, ¹⁵ 2005	N = 44	38	29	64	NR	NR
Frankle et al, ⁵ 2005	N = 60	33	NR	NR	34.3	68.2
Boileau et al, ¹ 2006	N = 42	40	17	58	NR	NR
Levigne et al, ⁷ 2008	N = 337	47	23	58	NR	NR
Stechel et al, ¹³ 2010	N = 59	48	15	55	NR	NR
Nolan et al, ⁸ 2011	N = 71	24	27.5	61.8	26	76.1
Present study	N = 591	36.6	Repair: 34.8 No repair: 33.8	Repair: 72.9 No repair: 67.9	Repair: 38.8 No repair: 34.9	Repair: 86.7 No repair: 82.1

ASES, American Shoulder and Elbow Surgeons; NR, measurement not reported; rTSA, reverse total shoulder arthroplasty.

Table VI Comparison of rTSA shoulder motion data reported in literature

Study	Average active forward flexion, °		Average active external rotation (arm at side), °	
	Preoperative	Postoperative	Preoperative	Postoperative
Sirveaux et al, ¹² 2004	73	138	3.5	11.2
Werner et al, ¹⁵ 2005	42	100	17	12
Frankle et al, ⁵ 2005	55.0	105.1	12.0	35.9
Boileau et al, ¹ 2006	55	121	7	11
Levigne et al, ⁷ 2008	70	125	7	9
Stechel et al, ¹³ 2010	47	105	–9	19
Nolan et al, ⁸ 2011	61.2	121.3	13.8	14.6
Present study	Repair: 91 No repair: 85	Repair: 141 No repair: 137	Repair: 13 No repair: 20	Repair: 34 No repair: 35

rTSA, reverse total shoulder arthroplasty.

to scapular notching were determined from radiographs, rather than from 3-dimensional reconstructions; also, the implanting surgeon performed the assessment, instead of an independent observer. However, the observed scapular notching rates reported in this study for each cohort are similar to those reported previously¹¹ when analyzed by multiple independent viewers in a blinded fashion.

It should also be noted that database analyses such as this contain numerous variables (different patient populations, different surgeons, different surgery centers, different rehabilitation methods, different data collection methods, and so on) that can limit their impact. We have done our best to standardize the practices of each data collection site and facilitated the use of standardized data collection forms to

quantify outcomes using multiple different scoring metrics. We regularly audited the data to confirm the quality and completeness of the inputs. Furthermore, the use of multiple different scoring metrics in particular acts to unify the methodology and also diversify any inherent bias between collection sites. Finally, the multi-institutional nature of this database, including the involvement of multiple surgeons, potentially allows for greater generalizability of the results across varying surgical techniques and experience. Future work should attempt to isolate the impact of different rehabilitation methods on rTSA outcomes, particularly as repair or non-repair of the subscapularis is considered.

Conclusion

Repair of the subscapularis did not lead to inferior clinical outcomes as predicted by biomechanical models.⁶ Although not repairing the subscapularis with a lateral humeral component led to significant clinical improvements, it did not result in higher outcome scores or greater range of motion. Furthermore, no difference was noted in the complication rates, scapular notching rates, or scapular notching grades between patients with subscapularis repair and those without repair. On the basis of the data from this study, positive and reliable clinical outcomes with a low risk of instability can be achieved using a lateralized humeral rTSA prosthesis, regardless of subscapularis repair. Some statistical differences were noted between cohorts with and without subscapularis repair with no difference in the complication rate; however, these absolute findings were small and are not likely clinically meaningful. This database analysis provides physicians with information regarding expected improvements with rTSA when the subscapularis is repaired or not repaired. Longer-term follow-up is required to confirm these findings and determine if they hold up over time.

Disclaimer

Richard J. Friedman received consultant payments from Exactech, which is directly related to the subject of this work.

Pierre-Henri Flurin received royalties and consultant payments from Exactech, which is directly related to the subject of this work.

Thomas W. Wright received royalties and consultant payments from Exactech, which is directly related to the subject of this work.

Joseph D. Zuckerman received royalties and consultant payments from Exactech, which is directly related to the subject of this work.

Christopher P. Roche is an employee of Exactech.

References

- Boileau P, Watkinson DJ, Hatzidakis AM, Hovorka I. Neer Award 2005: The Grammont reverse shoulder prosthesis: results in cuff tear arthritis, fracture sequelae, and revision arthroplasty. *J Shoulder Elbow Surg* 2006;15:527-40. <http://dx.doi.org/10.1016/j.jse.2006.01.003>
- Clark JC, Ritchie J, Song FS, Kissenberth MJ, Tolan SJ, Hart ND, et al. Complication rates, dislocation, pain, and postoperative range of motion after reverse shoulder arthroplasty in patients with and without repair of the subscapularis. *J Shoulder Elbow Surg* 2012;21:36-41. <http://dx.doi.org/10.1016/j.jse.2011.04.009>
- Edwards TB, Williams MD, Labriola JE, Elkousy HA, Gartsman GM, O'Connor DP. Subscapularis insufficiency and the risk of shoulder dislocation after reverse shoulder arthroplasty. *J Shoulder Elbow Surg* 2009;18:892-6. <http://dx.doi.org/10.1016/j.jse.2008.12.013>
- Flurin PH, Roche CP, Wright TW, Marczuk Y, Zuckerman JD. A comparison and correlation of clinical outcome metrics in anatomic and reverse total shoulder arthroplasty. *Bull Hosp Jt Dis* (2013) 2015;73(Suppl 1):S118-23. No doi.
- Frankle M, Siegal S, Pupello D, Saleem A, Mighell M, Vasey M. The reverse rotator cuff prosthesis for glenohumeral arthritis associated with severe rotator cuff deficiency. A minimum 2-year follow-up study of sixty patients. *J Bone Joint Surg Am* 2005;87:1697-705. <http://dx.doi.org/10.2106/JBJS.D.02813>
- Hansen ML, Nayak A, Narayanan MS, Worhac K, Stowell R, Jacofsky MC, et al. Role of subscapularis repair on muscle force requirements with reverse shoulder arthroplasty. *Bull Hosp Jt Dis* (2013) 2015;73(Suppl 1):S21-7. No doi.
- Lévigne C, Boileau P, Favard L, Garaud P, Molé D, Sirveaux F, et al. Scapular notching in reverse shoulder arthroplasty. *J Shoulder Elbow Surg* 2008;17:925-35. <http://dx.doi.org/10.1016/j.jse.2008.02.010>
- Nolan BM, Ankerson E, Wiater JM. Reverse total shoulder arthroplasty improves function in cuff tear arthropathy. *Clin Orthop Relat Res* 2011;469:2476-82. <http://dx.doi.org/10.1007/s11999-010-1683-z>
- Roche C, Crosby L. Kinematics and biomechanics of reverse total shoulder arthroplasty. In: AAOS orthopaedic knowledge update. #4. Rosemont, IL: American Academy of Orthopaedic Surgeons; 2013. p. 45-54.
- Roche CP, Diep P, Hamilton M, Crosby LA, Flurin PH, Wright TW, et al. Impact of inferior glenoid tilt, humeral retroversion, bone grafting, and design parameters on muscle length and deltoid wrapping in reverse shoulder arthroplasty. *Bull Hosp Jt Dis* (2013) 2013;71:284-93. No doi.
- Roche CP, Marczuk Y, Wright TW, Flurin PH, Grey S, Jones R, et al. Scapular notching and osteophyte formation after reverse shoulder replacement: radiological analysis of implant position in male and female patients. *Bone Joint J* 2013;95-B:530-5. <http://dx.doi.org/10.1302/0301-620X.95B4.30442>
- Sirveaux F, Favard L, Oudet D, Huquet D, Walch G, Mole D. Grammont inverted total shoulder arthroplasty in the treatment of glenohumeral osteoarthritis with massive rupture of the cuff: results of a multicentre study of 80 shoulders. *J Bone Joint Surg Br* 2004;86:388-95. <http://dx.doi.org/10.1302/0301-620X.86B3.14024>
- Stechel A, Fuhrmann U, Irlenbusch L, Rott O, Irlenbusch U. Reversed shoulder arthroplasty in cuff tear arthritis, fracture sequelae, and revision arthroplasty. *Acta Orthop* 2010;81:367-72. <http://dx.doi.org/10.3109/17453674.2010.487242>
- Wall B, Nové-Josserand L, O'Connor DP, Edwards TB, Walch G. Reverse total shoulder arthroplasty: a review of results according to etiology. *J Bone Joint Surg Am* 2007;89:1476-85. <http://dx.doi.org/10.2106/JBJS.F.00666>
- Werner CM, Steinman PA, Gilbert M, Gerber C. Treatment of painful pseudoparesis due to irreparable rotator cuff dysfunction with the Delta III reverse-ball-and-socket total shoulder prosthesis. *J Bone Joint Surg Am* 2005;87:1476-86. <http://dx.doi.org/10.2106/JBJS.D.02342>



ELSEVIER

ORIGINAL ARTICLE

Impact of scapular notching on clinical outcomes after reverse total shoulder arthroplasty: an analysis of 476 shoulders

Brent Mollon, MD, FRCSC^a, Siddharth A. Mahure, MD, MBA^a,
Christopher P. Roche, MSE^b, Joseph D. Zuckerman, MD^{a,*}

^aDepartment of Orthopaedic Surgery, Hospital for Joint Diseases, New York University, Langone Medical Center, New York, NY, USA

^bExactech, Inc., Gainesville, FL, USA

Background: Scapular notching is a complication unique to reverse total shoulder arthroplasty (rTSA), although its clinical implications are unclear and remains controversial.

Methods: We retrospectively reviewed rTSA patients of a single implant design in 476 shoulders with a minimum 2-year clinical and radiographic follow-up. Clinical measures included active range of motion and American Shoulder and Elbow Surgeons scores, in addition to one or more of the Constant score, Shoulder Pain and Disability Index, Simple Shoulder Test (SST), and University of California, Los Angeles Shoulder Rating Scale. Complications and rates of humeral radiolucencies were also recorded.

Results: Scapular notching was observed in 10.1% (48 of 476) of rTSAs and was associated with a longer clinical follow-up, lower body weight, lower body mass index, and when the operative side was the nondominant extremity. Patients with scapular notching had significantly lower postoperative scores on the Shoulder Pain and Disability Index, Constant, Simple Shoulder Test, and University of California, Los Angeles, Shoulder Rating Scale compared with patients without scapular notching. Patients with scapular notching also had significantly lower active abduction, significantly less strength, and trended toward significantly less active forward flexion ($P = .0527$). Finally, patients with scapular notching had a significantly higher complication rate and trended toward a significantly higher rate of humeral radiolucent lines ($P = .0896$) than patients without scapular notching.

Conclusions: This large-scale outcome study demonstrates that patients with scapular notching have significantly poorer clinical outcomes, significantly less strength and active range of motion, and a significantly higher complication rate than patients without scapular notching. Longer-term follow-up is necessary to confirm that these statistical observations in the short-term will result in greater clinically meaningful differences over time.

Level of evidence: Level III; Retrospective Cohort Design; Treatment Study

© 2017 Journal of Shoulder and Elbow Surgery Board of Trustees. All rights reserved.

Keywords: Scapular notching; rTSA; clinical outcomes; arthroplasty; complications; retrospective

Data acquisition and analysis was performed with approval from the Western Institutional Review Board (protocol # WIRB 20091701).

*Reprint requests: Joseph D. Zuckerman, MD, Department of Orthopaedic Surgery, NYU Hospital for Joint Diseases, 301 E 17th St, 14th Flr, New York, NY 10003, USA.

E-mail address: joseph.zuckerman@nyumc.org (J.D. Zuckerman).

Reverse total shoulder arthroplasty (rTSA) has been shown to alleviate pain and improve function at midterm follow-up in patients with rotator cuff arthropathy and glenohumeral arthritis with rotator cuff tears.^{11,23} Indications have expanded to include complex proximal humeral fractures and

revision shoulder arthroplasty.^{1,7,8,38} Despite improved surgeon experience and implant design, complication rates still range from 3% to 22% in recent series.^{11,13,18}

Scapular notching is a complication unique to rTSA. Notching occurs when the humeral polyethylene liner contacts the inferior scapular neck, resulting in bone loss beneath the glenoid baseplate and component failure in severe cases.^{24,27-29,32-34} Rates of scapular notching have ranged from 10% to 96% in recent series,^{7,8,17,19,20,28,29,32-34,36,39} with notching progressive with follow-up duration. The magnitude of scapular notching is defined by the Nerot-Sirveaux grading scale,³⁴ where grade 1 or 2 notches represent the mechanical limit of impingement (up to the inferior screw) and grade 3 and 4 notches involve a biologic response as the notch progresses past the inferior screw.^{19,20,34,39} Numerous patient and surgical technique factors (ie, glenosphere position, body mass index [BMI], scapular neck angle, scapular neck length, and humeral or glenoid retroversion),^{12,17,19,20,22-29} as well as prosthesis design parameters (ie, glenosphere inferior overhang, glenosphere thickness, center of rotation location, humeral neck angle, and humeral liner constraint)^{15,16,26,27,29} have been demonstrated to affect range of motion (ROM) and prosthesis impingement, thereby contributing to scapular notching. Substantial effort has attempted to reduce the rate of occurrence, with the most recent prosthesis designs and implantation techniques associated with substantially less scapular notching.^{17,22,27-29}

Biomechanical studies suggest scapular notching may increase baseplate micromotion and reduce fixation, potentially leading to implant failure.³⁰ However, the clinical effect of scapular notching remains unclear. Some clinical studies have reported poorer outcomes in patients with scapular notching,^{20,32-34,37} but others have found no difference compared with those without notching.^{7,8,19,36,39} Such conflicting reports regarding the clinical effect of scapular notching likely reflect issues in study design/power arising from the relatively high rate of notching associated with many rTSA prosthesis designs coupled with the inherent error in radiographic identification of the scapular notch. For example, Werner et al³⁹ reported that scapular notching did not correlate with any negative outcome, despite only 4% (2 of 48) of patients without scapular notching.

The rate of scapular notching has been demonstrated to be affected by BMI, with scapular notching less likely to occur in patients with a greater BMI.^{19,20,22} Therefore, clinical outcome studies using a prosthesis associated with very high scapular notching rates may not be comparing equivalent populations because greater BMI has been demonstrated to negatively affect patient outcomes with shoulder arthroplasty.^{5,14,21} We retrospectively reviewed a prospectively collected database of outcomes of an rTSA shoulder prosthesis associated with a well-defined and relatively low scapular notching rate^{17,22,27-29} to determine whether the presence of a scapular notch negatively affects clinical outcomes and the rate of complications.

Materials and methods

Patient selection

We retrospectively reviewed a prospectively collected database to identify patients who received primary rTSA with the Equinoxe rTSA platform shoulder arthroplasty system (Exactech, Inc., Gainesville, FL, USA) between 2007 and 2014. The database recorded information on demographics, preoperative functional scores, surgical indications, implanted rTSA component sizes, intraoperative and postoperative complications, postoperative outcomes, and radiographic findings. Exactech, Inc. funds and maintains this database but is not involved in any of the data input; all data input occurs at each of the clinical sites.

All patients were monitored for a minimum of 2 years and had complete preoperative and postoperative active ROM (AROM) values and American Shoulder and Elbow (ASES) scores. All data were recorded by a fellowship-trained shoulder surgeon who also performed the surgical procedure. The study excluded patients with a history of a previous arthroplasty procedure or a diagnosis of infection or acute proximal humeral fracture. Given the association between constrained polyethylene liners and scapular notching, patients receiving constrained implants were also excluded. Other nonarthroplasty surgical interventions were noted, but were not part of the exclusion criteria.

These criteria resulted in 464 patients who received 476 rTSAs by 1 of 9 fellowship-trained surgeons with mean follow-up of 38 months (range, 22-93 months; Fig. 1). Case distribution was not uniform because 3 of the 9 surgeons performed 69% of the operations. Twelve patients underwent bilateral procedures separated in time; thus, the final sample consisted of 476 shoulders with a mean age at surgery of 72.5 years (range, 53-90 years). Of the 476 rTSAs, 312 (66%) were performed in women, and 313 (67%) performed in the dominant shoulder. Additional demographic, preoperative, and operative information are reported in Table I.

Prosthetic design selection

The 38-, 42-, and 46-mm Equinoxe reverse shoulder prosthesis has a 145° neck angle, a humeral liner constraint of 0.260, 0.250, 0.240, and a standard glenosphere geometry of 38 × 21, 42 × 23, and 46 × 25 mm, respectively. The center of rotation of each size standard glenosphere averages 2.3 mm lateral to the spherically reamed glenoid surface to minimize torque on the glenoid fixation surface while also maximizing the length of the deltoid abductor moment arm. Because of the 4 mm superiorly shifted glenoid plate cage peg, when the inferior rim of the glenoid plate is aligned with the glenoid inferior rim, the 38-, 42-, and 46-mm Equinoxe is designed to provide 2.25, 4.25, and 6.25 mm of glenosphere overhang, respectively. Because of this inherent prosthesis inferior offset, inferior tilt is not recommended and was not performed in this study.

Expanded (≥4-mm thick) glenospheres are also provided in 38-mm and 42-mm sizes to help the surgeon lateralize the humerus and gain stability in instances of medial glenoid wear. In this study, 256 patients (227 women and 29 men) received a standard 38-mm × 21-mm glenosphere, 10 patients (7 women and 3 men) received a 38-mm × 25-mm expanded glenosphere, 189 patients (73 women and 116 men) received a standard 42-mm × 23-mm glenosphere, 11 patients (3 women and 8 men) received a 42-mm × 27-mm expanded glenosphere, and 10 patients (2 women and 8 men) received a standard 46-mm × 25-mm glenosphere.

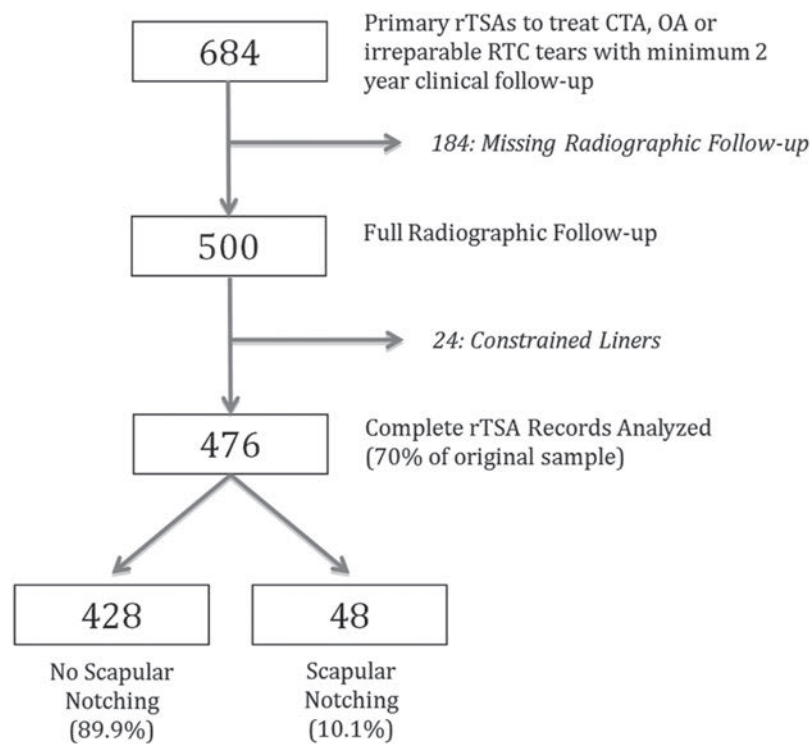


Figure 1 Inclusion of reverse total shoulder arthroplasties (rTSAs), with and without scapular notching, from a large implant database. CTA, cuff tear arthropathy; OA, osteoarthritis; RCT, rotator cuff tear.

Table I Comparison of baseline factors for shoulders with and without scapular notching (N = 476)

Variable*	No scapular notching (n = 428)	Scapular notching (n = 48)	Significance (P)
Age, y	72.4 ± 7.1	72.6 ± 7.7	.8088
Height, cm	165.7 ± 9.7	165.9 ± 11.1	.8465
Weight, kg	77.2 ± 16.9	71.1 ± 14.7	.0362
BMI, kg/m ²	28.0 ± 5.4	25.7 ± 4.1	.0061
Length of follow-up, mo	37.0 ± 15.9	46.1 ± 17.9	.0001
Male gender	34 (144/428)	42 (20/48)	.2682
Dominant extremity	67 (288/428)	52 (25/48)	.0355
Preoperative function			
Overall shoulder function	3.8 ± 2.0	3.7 ± 1.8	.9759
ASES score	38.2 ± 15.7	34.3 ± 15.0	.1074
Constant score	35.0 ± 13.8	32.7 ± 12.8	.4174
New SPADI score	81.0 ± 22.5	82.2 ± 21.8	.8340
Simple Shoulder Test score	3.5 ± 2.2	3 ± 2.2	.4340
UCLA Shoulder Rating scale	13.6 ± 4.0	13.1 ± 3.7	.5547
Active abduction, °	72 ± 36	70 ± 34	.9679
Active forward flexion, °	89 ± 40	89 ± 41	.8915
Active external rotation, °	16 ± 23	14 ± 21	.7757
Internal rotation score	3.3 ± 1.8	3.3 ± 1.8	.7818
Strength, lbs	1.3 ± 2.7	1.2 ± 2.4	.7822
Operative factors			
Latissimus dorsi transfer	0.5(2/428)	2 (1/48)	.1805
Subscapularis repaired	58 (233/400)	57 (26/46)	.8225
Baseplate screws, No.	4.2 ± 0.5	4.3 ± 0.5	.0853
Blood loss, mL	269 ± 116	314 ± 119	.0121

ASES, American Shoulder and Elbow Surgeons; BMI, body mass index; SPADI, Shoulder Pain and Disability Index; UCLA, University of California, Los Angeles.

* Continuous data are shown as mean ± standard deviation and categorical data as percentage (n/N).

Clinical assessment

Preoperative information collected included gender, age at surgery, primary diagnosis, BMI, strength, AROM (abduction, forward flexion, and internal/external rotation), and patient-perceived shoulder function. Intraoperative data included operative side, components used, blood loss, presence or absence of subscapularis repair, and the number of screws used with the glenoid baseplate. An assessment of glenoid wear and morphology (ie, retroversion, medialization) and information related to glenoid component placement were not recorded in the database. Postoperative data obtained at latest follow-up included AROM, patient-perceived shoulder function, strength, and any postoperative complication, including treatment required.

Surgeon-measured active internal rotation was standardized on an 8-point numeric score.¹² To summarize, internal rotation was measured by vertebral segments and was scored by the following discrete assignment: 0° = 0, hip = 1, buttocks = 2, sacrum = 3, L5 to L4 = 4, L3 to L1 = 5, Th12 to Th8 = 6, and Th7 or higher = 7. In addition, the following validated shoulder outcome scores were recorded preoperatively and at each postoperative follow-up: American Shoulder and Elbow (ASES) scores, Constant score, New Shoulder Pain and Disability Index (SPADI), Simple Shoulder Test (SST) score, and the University of California, Los Angeles (UCLA) Shoulder Rating Scale.^{2-4,9,31} All tests include physician and patient input when compiling the final score, with the exception of the ASES and SPADI scores, which are based entirely on patient assessment.

Radiographic assessment

The treating surgeons completed a standardized form pertaining to postoperative radiographic findings. Presence and grade of scapular notching was noted according to the Nerot-Sirveaux classification.³⁴ Rates of humeral radiolucency were also noted.³⁵ Because this was a retrospective review of a multicenter database, an independent review of radiographs was not performed.

Data analysis

Descriptive statistics are reported as mean \pm standard deviation for continuous variables and as percentages for categorical data. An

Anderson-Darling test for normality found a nonparametric distribution of the data. For this reason, subsequent statistical analysis used nonparametric tests. Specifically, a Mann-Whitney test was used to identify differences in preoperative, postoperative, and preoperative-to-postoperative improvements, where a $P = .05$ determined significance. Data were analyzed using Minitab 16 software (Minitab, Inc., State College, PA, USA).

Results

Rates of scapular notching

Scapular notching occurred in 10.1% (48 of 476) of shoulders. Preoperative and operative differences between patients with and without scapular notching are summarized in Table I. Notably, notching was more likely in shoulders with a longer clinical follow-up (46.1 ± 17.9 vs. 37.0 ± 15.9 months; $P = .0001$), lower body weight (71.1 ± 14.7 vs. 77.2 ± 16.9 kg; $P = .0362$), lower BMI (25.7 ± 4.1 vs. 28.0 ± 5.4 kg/m²; $P = .0061$), and when the operative side was the nondominant extremity (48% vs. 33%; $P = .0355$).

At final follow-up, 79% (38 of 48) of patients with scapular notching had a Sirveaux grade 1 notch, 13% (6 of 48) had a grade 2 notch, and 8% (4 of 48) had a grade 3 notch. No patients had a grade 4 scapular notch. Scapular notching rates increased with postoperative follow-up, where 21% (6 of 29) of shoulders monitored for more than 6 years demonstrated scapular notching (Fig. 2). In addition, shoulders with higher grades (ie, 2 or 3) of scapular notching were associated with significantly longer follow-up than patients with grade 1 notches (58.3 ± 19.0 vs. 42.9 ± 16.3 months; $P = .0130$).

The rate of scapular notching was similar in men (20 of 164 [12.2%]) and women (28 of 312 [9.0%]; $P = .2682$). Implant size differed by gender, where 75.0% of women received a 38-mm glenosphere and 80.5% of men received a 42-mm glenosphere or larger. Despite these differences in prosthetic use by gender, scapular notching rates were similar across glenosphere sizes. Specifically, notching occurred in

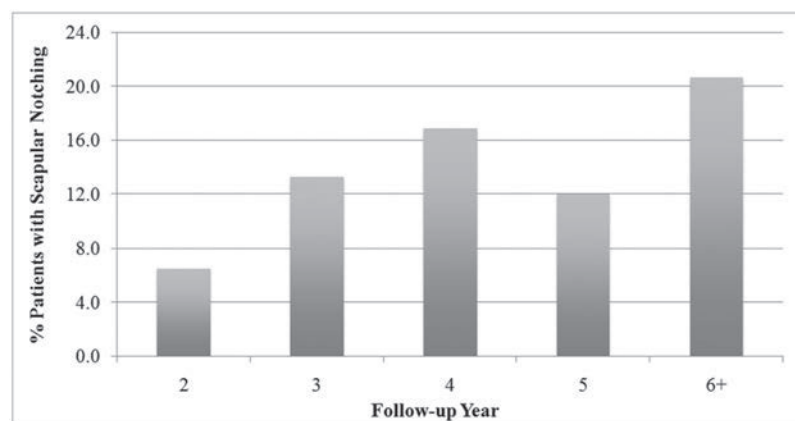


Figure 2 Percentage of patients diagnosed with scapular notching by duration of radiographic follow-up.

9.8% (25 of 256 patients; 19 of 227 women [8.3%]; 6 of 29 men [20.7%]) who received a standard 38-mm × 21-mm glenosphere, 10.0% (1 of 10 patients; 1 man) who received a 38-mm × 25-mm expanded glenosphere, 11.1% (21 of 189 patients, 8 of 73 women [11.0%]; 13 of 116 men [11.2%]) who received a standard 42-mm × 23-mm glenosphere, 0% (0 of 11 patients) who received a 42-mm × 27-mm expanded glenosphere, and in 10.0% (1 of 10 patients, 1 woman) who received a 46-mm × 25-mm glenosphere.

Clinical differences

After rTSA, shoulders had significant mean improvements in every ROM measurement and functional outcome score, regardless of the presence of a scapular notch. However, at the latest follow-up, shoulders with scapular notching had significantly lower ASES (78.1 ± 21.8 vs. 84.1 ± 17.1 ; $P = .0257$), Constant (66.0 ± 13.9 vs. 71.0 ± 14.2 ; $P = .0086$), SST (9.4 ± 3.0 vs. 10.1 ± 2.6 ; $P = .0218$), and UCLA scores (28.0 ± 6.3 vs. 30.1 ± 4.7 ; $P = .0131$) compared with patients without scapular notching (Table II). Shoulders with scapular notching also had significantly lower active abduction ($103^\circ \pm 23^\circ$ vs. $113^\circ \pm 27^\circ$; $P = .0054$), significantly less strength (5.1 ± 4.4 vs. 7.6 ± 5.6 lbs; $P = .0033$), and trended toward significantly less active forward flexion ($130^\circ \pm 30^\circ$ vs. $139^\circ \pm 26^\circ$; $P = .0527$) than patients without scapular notching. Interestingly, shoulders with scapular notching had a significantly larger internal rotation score (5.3 ± 1.5 vs. 4.8 ± 1.6 ; $P = .012$) compared with patients without scapular notching (Table II). In contrast to these significant postoperative differences, few differences were observed between cohorts in the mean change from preoperative values (Table III).

Finally, 31 complications (6.5%) were reported for both cohorts, where 24 complications occurred in patients without scapular notching and 7 complications occurred in patients with scapular notching (Table IV). Patients with scapular notching had a significantly higher complication rate (14.6% vs. 5.6%; $P = .0170$) compared with patients without scapular notching. In addition, 19 patients were reported to have humeral radiolucent lines, where 15 humeral radiolucent lines were reported for patients without scapular notching and 4 were reported for patients with scapular notching. Patients with scapular notching trended toward a significantly higher rate of humeral radiolucent lines (8.7% vs. 3.5%; $P = .0896$). Of note, the rate of humeral radiolucent lines was 0% for patients with grade 1 notches and 20% for those with grade 2 or 3 notches.

Discussion

This study, the largest series assessing the effect of scapular notching on clinical outcomes, has several noteworthy results related to differences between rTSA patients with and without notching. First, patients with scapular notching were associated

Table II Comparison of overall postoperative outcomes at final follow-up after reverse total shoulder arthroplasty for shoulders with and without scapular notching

Post-op outcomes	Shoulder function	ASES	Constant	New SPADI	SST score	UCLA score	Active range of motion, °			Internal rotation score	Strength, lbs
							Abduction	Forward flexion	External rotation		
No notching, mean ± SD	8.1 ± 1.7	84.1 ± 17.1	71.0 ± 14.2	20.4 ± 23.1	10.1 ± 2.6	30.1 ± 4.7	113 ± 27	139 ± 26	35 ± 17	4.8 ± 1.6	7.6 ± 5.6
Notching, mean ± SD	7.9 ± 1.9	78.1 ± 21.8	66.0 ± 13.9	26.7 ± 28.5	9.4 ± 3.0	28.0 ± 6.3	103 ± 23	130 ± 30	35 ± 16	5.3 ± 1.5	5.1 ± 4.4
Significance*	.3231	.0257	.0086	.1281	.0218	.0131	.0054	.0527	.7162	.0115	.0033

ASES, American Shoulder and Elbow Surgeons; SD, standard deviation; SPADI, Shoulder Pain and Disability Index; SST, Simple Shoulder Test; UCLA, University of California, Los Angeles.
* Bold values are statistically significant ($P < .05$).

Table III Comparison of clinical improvements after reverse total shoulder arthroplasty for shoulders with and without scapular notching

Pre- to-post improvement	Shoulder Function	ASES	Constant	New SPADI	SST score	UCLA score	Active range of motion, °		Internal rotation score	Strength, lbs	
							Abduction	Forward flexion			External rotation
No notching, mean ± SD	+4.3±2.5	+45.6±19.5	+35.9±16.9	-59.2±27.2	+6.6±3.2	+16.5±5.5	+42±38	+50±44	+19±25	+1.5±2.1	+6.2±5.2
Notching, mean ± SD	+4.4±2.1	+45.2±22.7	+33.4±16.2	-56.8±28.4	+6.6±3.1	+15.5±6.3	+33±36	+41±42	+22±21	+2.0±2.0	+4.1±4.0
Significance*	.6814	.792	.3142	.7184	.9571	.2503	.0776	.1403	.7391	.2877	.0124

ASES, American Shoulder and Elbow Surgeons; SD, standard deviation; SPADI, Shoulder Pain and Disability Index; SST, simple shoulder test; UCLA, University of California, Los Angeles.

* Bold values are statistically significant ($P < .05$).

Table IV Comparison of complications for shoulders with and without scapular notching

Complication	No scapular notching	Scapular notching
	(n = 428)	(n = 48)
	No. (%)	No. (%)
Aseptic humeral loosening	2 (0.5)	0 (0)
Deltoid strain	1 (0.2)	0 (0)
Dislocation/instability	2 (0.5)	0 (0)
Humeral fracture/periprosthetic fracture	5 (1.2)	2 (4.2)
Fractured scapula/stress fracture	3 (0.7)	1 (2.1)
Infection	4 (0.9)	0 (0)
Aseptic glenoid loosening	2 (0.5)	1 (2.1)
Persistent pain	4 (0.9)	3 (6.3)
Stiffness	1 (0.2)	0 (0)
Rate, %	5.6	14.6

with longer clinical follow-up, lower body weight, lower BMI, and more commonly occurred in the nondominant extremity. No differences in scapular notching rates were noted by gender or glenosphere size.

Second, patients with scapular notching were associated with significantly lower postoperative outcomes as measured by 4 of the 5 metrics used in this study, although few differences were noted relative to the mean change from the preoperative value.

Third, patients with scapular notching were associated with significantly less postoperative active abduction and strength and trended toward less active forward flexion but were also associated with significantly more active internal rotation.

Finally, patients with scapular notching had a significantly higher rate of complications compared with patients without scapular notching.

The scapular notching rate was 10.1% in our series after a mean follow-up of 38 months, where 2.1% of patients had a grade 2 or larger notch. These scapular notching rates are similar to those reported in other studies that used this particular rTSA prosthesis^{17,22,28,29} but are substantially lower than the 35% to 96% rates published for other rTSA designs with a medialized center of rotation.^{7,8,15,16,19,20,32-34,36,37,39}

Even though scapular notching rates and grades have been previously reported to be progressive and increase with follow-up duration,^{19,20,39} which is descriptively supported by our data, such minor comparative differences in follow-up do not explain the wide disparities in rates and grades. Instead, these substantial differences in scapular notching rates likely result from improvements in prosthesis design and surgical technique. For example, a humeral neck/liner angle of 145°, a 2 mm lateralized center of rotation, and larger/thicker glenospheres (ie, 42 mm to 46 mm) have all been associated with decreased rates of scapular notching.^{6,10,16,25,27-29} In addition, from a technical point of view, inferior glenosphere placement on the

glenoid has also been shown to decrease rates of notching.²⁶⁻²⁹ The culmination of these modifications increases impingement-free motion and thus decreases the rate and severity of notching.

Patients with scapular notching had a lower BMI and a lower body weight than patients without scapular notching. This finding is intuitive, because these patients can likely adduct their arm closer to their torso to permit humeral liner impingement with the scapular neck during activities of daily living. The observed lower average BMI and body weight may also suggest that patients with notching were more active and thus had more repetitive contact than less active patients who were not observed to notch. For example, Lévine et al²⁰ reported greater patient activity increased scapular notch development.

In addition, the finding that patients with scapular notching trended toward a significantly higher rate of humeral radiolucent lines, suggests that the resulting ultra-high-molecular-weight polyethylene (UHMWPE) wear debris may be related to the formation of radiolucent lines with an osteolytic response, as was suggested by Werner et al.³⁹ The relationship of such a mechanism is strengthened by the observation that 20% of patients with scapular notching grades of 2 or larger in our study were observed to have radiolucent lines, because larger size scapular notches result in greater amounts of UHMWPE debris, which could elicit an osteolytic response. The association between notching and radiolucent lines was also observed by Lévine et al,²⁰ who reported that patients with scapular notching had a significantly higher incidence of humeral radiolucent lines (36% notching vs. 17% no notching) and glenoid radiolucent lines (9% notching vs 3% no notching) than patients without scapular notching.

We found that patients with scapular notching had significantly lower postoperative metric scores, significantly less strength and AROM, and a significantly higher complication rate than patients without scapular notching. These statistical differences were relatively small but are still noteworthy because this study reports only short-term outcomes. Given the progressive nature of scapular notching and the potential association of UHMWPE debris with osteolysis, these statistical differences are likely to result in greater clinically meaningful differences at midterm and longer-term follow-up, as was found by Sadoghi et al³² in their series of patients with follow-up greater than 60 months. Table V summarizes the results of studies that examined the effect of scapular notching on clinical outcomes.^{8,19,20,32-34,37,39}

Our clinical results appear to confirm the findings of several recent studies which reported that scapular notching does negatively affect clinical outcomes.^{20,32-34,37} Sirveaux et al³⁴ first reported that patients with large scapular notches had significantly lower Constant scores than patients without scapular notching or patients who only had small scapular notches. Simovitch et al³³ reported that patients with scapular notching had significantly lower Constant scores (72 notching vs. 83 no notching), significantly lower active forward flexion

Table V Comparison of known studies comparing outcomes in patients with and without scapular notching

Study	No. of Shoulders	Mean F/U (mo.)	Mean F/U (%)	Notching (%)	No. of Shoulders with Scapular Notching	No. of Shoulders without Scapular Notching	Average Post-op Score	Average Reported Constant Score	Study Power Calculation (%)*	ASES Constant	Active Abduction	Active Forward Flexion	Active External Rotation	Strength
Current	476	38	10.1	2.1	48	428	70	70	94.9	↓	↓	↓	↓	↓
Simovitch³³	77	44	44.0	36.4	34	43	83	83	70.3	↓	↓	↓	↑	↓
Sirveaux³⁴	77	45	63.6	29.9	49	28	65.5	65.5	67.9	↓	↓	↓	↓	↓
Sadoghi³²	60	42	36.7	11.7	22	38	63.4	63.4	58.8	↓	N.S.	↓	↓	↓
Torrrens³⁷	36	40	36.1	25.0	13	23	50	50	41.9	↓	↓	↓	↓	↓
Lévine²⁰	461	51	68.0	46.0	312	149	NR	NR	NA	N.S.	↓	↓	↓	↓
Levigne¹⁹	337	47	62.0	40.0	209	128	58	58	99.8	N.S.	↓	↓	↓	↓
Boileau⁸	38	40	68.0	22.2	26	12	58	58	41.6	N.S.	↓	↓	↓	↓
Stechel³⁶	59	48	86.4	40.7	51	8	55	55	37.1	N.S.	↓	↓	↓	↓
Werner³⁹	48	38	96.0	>46.0	46	2	64	64	17.0	N.S.	↓	↓	↓	↓

N.S. represents no significant difference between patients with scapular notching and those without, ↓ represents a significant difference, where patients with a scapular notch have smaller magnitudes of a particular outcome measurement, and ↑ represents a significant difference, where patients with a scapular notch have a larger magnitude of a particular outcome measurement. ASES, American Shoulder and Elbow Surgeons; F/U, follow-up; N.S., not significant; SPADI, Shoulder Pain and Disability Index; UCLA, University of California, Los Angeles; MR, not reported; NA, not available.
 * Note that study power was calculated from a one-tail test using an alpha = 0.05. As the majority of cited studies did not report the constant score for each study group, we calculated the study power using the average reported Constant score for each study and assumed a difference in Constant score of 5 points and also assumed a Constant score standard deviation of 10 points for each group. Levigne²⁰ does not have a study power calculation because they did not report a Constant score.

(110° notching vs. 127° no notching), and significantly lower active abduction (102° notching vs. 118° no notching) than patients without scapular notching. Similarly, Sadoghi et al³² reported that patients with scapular notching at 60 months' follow-up were associated with more pain, less external rotation, and lower Constant scores. In addition to reporting the increased rate of humeral and glenoid radiolucent lines in patients with scapular notching, Lévigne, et al²⁰ also reported that patients with scapular notching had significantly lower strength (by 0.5 kg) and significantly lower passive (141° notching vs. 147° no notching) and active (128° notching vs. 134° no notching) forward flexion than patients without scapular notching.

Our results are strengthened by our large sample size and its statistical power, which is larger than all but 1 of the previous studies that have assessed the effect of scapular notching on clinical outcomes (Table V). Nonetheless, our study has certain limitations. First, it reports the short-term outcomes at a mean follow-up of 38 months. Given the progressive nature of scapular notching,^{19,20,39} longer follow-up is necessary to confirm both this relatively low rate and that scapular notching affects clinical outcomes in the long-term.

In addition, database analyses inherently contain numerous variables (ie, different patient populations, surgeons/surgical centers, implantation methods, and rehabilitation methods) that may limit their effect. Knowing this, we did our best to standardize the practices of each data collection site and facilitated the use of standardized data collection forms to quantify outcomes using 5 different scoring metrics to diversify any inherent bias, where most of patients are scored using all 5 metrics.

Next, the grading of scapular notching is limited because the implanting physicians scored their own radiographs (introducing bias), so no intraobserver or interobserver control was performed. The scapular notching rate varied little among the 9 implanting surgeons, with the smallest scapular notching rate being 4.8% and the largest scapular notching rate being 12.3%. In addition, the scapular notching grade was based on anteroposterior radiographs rather than fluoroscopy or 3-dimensional reconstructed images. Lévigne et al²⁰ reported that only 89% of the scapular notches could be observed in an anteroposterior radiograph because of imprecision in patient positioning. Future work should incorporate the use of a single reviewer or multiple independent reviewers of all radiographs to further minimize bias.

Finally, we did not attempt to characterize the preoperative glenoid wear pattern. Sirveaux et al³⁴ states that glenoid plate positioning in types E2 or E3 worn glenoids can increase in impingement, and Lévigne et al²⁰ reported that notching was correlated to the type of preoperative glenoid erosion. Future work should characterize the preoperative glenoid wear pattern, humeral version, glenoid retroversion/inclination, and also whether any rehabilitation therapies have been performed and attempt to isolate its effect on scapular notching rates and also identify any relationship with clinical outcomes.

Conclusions

This large-scale clinical outcome study demonstrates that patients with scapular notching had significantly poorer clinical outcomes, significantly less strength and AROM, and a significantly higher complication rate than patients without scapular notching. Contrary to previous reports,^{7,8,19,36,39} the conclusion of this study suggests that scapular notching does negatively affect clinical outcomes at short-term follow-up. Additional and longer-term follow-up is necessary to confirm that these statistically meaningful differences over time. Based on these short-term clinical outcome results, we recommend that surgeons make every effort to avoid scapular notching when performing rTSA.

Disclaimers

Funding for this manuscript was sponsored by Exactech, Inc.

Christopher P. Roche is an employee of Exactech, Inc. Joseph D. Zuckerman receives royalties from Exactech, Inc. The other authors, their immediate families, and any research foundations with which they are affiliated have not received any financial payments or other benefits from any commercial entity related to the subject of this article.

References

1. Acevedo DC, Vanbeek C, Lazarus MD, Williams GR, Abboud JA. Reverse shoulder arthroplasty for proximal humeral fractures: update on indications, technique, and results. *J Shoulder Elbow Surg* 2014;23:279-89. <http://dx.doi.org/10.1016/j.jse.2013.10.003>
2. Amstutz HC, Sew Hoy AL, Clarke IC. UCLA anatomic total shoulder arthroplasty. *Clin Orthop Relat Res* 1981;7-20.
3. Angst F, Goldhahn J, Drerup S, Aeschlimann A, Schwyzer HK, Simmen BR. Responsiveness of six outcome assessment instruments in total shoulder arthroplasty. *Arthritis Rheum* 2008;59:391-8. <http://dx.doi.org/10.1002/art.23318>
4. Angst F, Pap G, Mannion AF, Herren DB, Aeschlimann A, Schwyzer HK, et al. Comprehensive assessment of clinical outcome and quality of life after total shoulder arthroplasty: usefulness and validity of subjective outcome measures. *Arthritis Rheum* 2004;51:819-28. <http://dx.doi.org/10.1002/art.20688>
5. Beck JD, Irgit KS, Andreychik CM, Maloney PJ, Tang X, Harter GD. Reverse total shoulder arthroplasty in obese patients. *J Hand Surg Am* 2013;38:965-70. <http://dx.doi.org/10.1016/j.jhsa.2013.02.025>
6. Berhouet J, Garaud P, Favard L. Evaluation of the role of glenosphere design and humeral component retroversion in avoiding scapular notching during reverse shoulder arthroplasty. *J Shoulder Elbow Surg* 2014;23:151-8. <http://dx.doi.org/10.1016/j.jse.2013.05.009>
7. Boileau P, Gonzalez JF, Chuinard C, Bicknell R, Walch G. Reverse total shoulder arthroplasty after failed rotator cuff surgery. *J Shoulder Elbow Surg* 2009;18:600-6. <http://dx.doi.org/10.1016/j.jse.2009.03.011>
8. Boileau P, Watkinson D, Hatzidakis AM, Hovorka I, Neer Award 2005: the Grammont reverse shoulder prosthesis: results in cuff tear arthritis,

- fracture sequelae, and revision arthroplasty. *J Shoulder Elbow Surg* 2006;15:527-40. <http://dx.doi.org/10.1016/j.jse.2006.01.003>
9. Bot SD, Terwee CB, van der Windt DA, Bouter LM, Dekker J, de Vet HC. Clinimetric evaluation of shoulder disability questionnaires: a systematic review of the literature. *Ann Rheum Dis* 2004;63:335-41. <http://dx.doi.org/10.1136/ard.2003.007724>
 10. Chou J, Malak SF, Anderson IA, Astley T, Poon PC. Biomechanical evaluation of different designs of glenospheres in the SMR reverse total shoulder prosthesis: range of motion and risk of scapular notching. *J Shoulder Elbow Surg* 2009;18:354-9. <http://dx.doi.org/10.1016/j.jse.2009.01.015>
 11. Favard L, Lévine C, Nerot C, Gerber C, De Wilde L, Mole D. Reverse prostheses in arthropathies with cuff tear: are survivorship and function maintained over time? *Clin Orthop Relat Res* 2011;469:2469-75. <http://dx.doi.org/10.1007/s11999-011-1833-y>
 12. Flurin PH, Marczuk Y, Janout M, Wright TW, Zuckerman J, Roche CP. Comparison of outcomes using anatomic and reverse total shoulder arthroplasty. *Bull Hosp Jt Dis (2013) 2013;71(Suppl 2):101-7*.
 13. Groh GI, Groh GM. Complications rates, reoperation rates, and the learning curve in reverse shoulder arthroplasty. *J Shoulder Elbow Surg* 2014;23:388-94. <http://dx.doi.org/10.1016/j.jse.2013.06.002>
 14. Gupta AK, Chalmers PN, Rahman Z, Bruce B, Harris JD, McCormick F, et al. Reverse total shoulder arthroplasty in patients of varying body mass index. *J Shoulder Elbow Surg* 2014;23:35-42. <http://dx.doi.org/10.1016/j.jse.2013.07.043>
 15. Karelse AT, Bhatia DN, De Wilde LF. Prosthetic component relationship of the reverse Delta III total shoulder prosthesis in the transverse plane of the body. *J Shoulder Elbow Surg* 2008;17:602-7. <http://dx.doi.org/10.1016/j.jse.2008.02.005>
 16. Kempton LB, Balasubramaniam M, Ankerson E, Wiater JM. A radiographic analysis of the effects of glenosphere position on scapular notching following reverse total shoulder arthroplasty. *J Shoulder Elbow Surg* 2011;20:968-74. <http://dx.doi.org/10.1016/j.jse.2010.11.026>
 17. King JJ, Farmer KW, Struk AM, Wright TW. Uncemented versus cemented humeral stem fixation in reverse shoulder arthroplasty. *Int Orthop* 2015;39:291-8. <http://dx.doi.org/10.1007/s00264-014-2593-6>
 18. Klein SM, Dunning P, Mulieri P, Pupello D, Downes K, Frankle MA. Effects of acquired glenoid bone defects on surgical technique and clinical outcomes in reverse shoulder arthroplasty. *J Bone Joint Surg Am* 2010;92:1144-54. <http://dx.doi.org/10.2106/JBJS.I.00778>
 19. Lévine C, Boileau P, Favard L, Garaud P, Molé D, Sirveaux F, et al. Scapular notching in reverse shoulder arthroplasty. *J Shoulder Elbow Surg* 2008;17:925-35. <http://dx.doi.org/10.1016/j.jse.2008.02.010>
 20. Lévine C, Garret J, Boileau P, Alami G, Favard L, Walch G. Scapular notching in reverse shoulder arthroplasty: is it important to avoid it and how? *Clin Orthop Relat Res* 2011;469:2512-20. <http://dx.doi.org/10.1007/s11999-010-1695-8>
 21. Linberg CJ, Sperling JW, Schleck CD, Cofield RH. Shoulder arthroplasty in morbidly obese patients. *J Shoulder Elbow Surg* 2009;18:903-6. <http://dx.doi.org/10.1016/j.jse.2009.02.006>
 22. Mau EM, Roche CP, Zuckerman JD. Effects of body mass index on outcomes in total shoulder arthroplasty. *Bull Hosp Jt Dis (2013) 2015;73(Suppl 1):S99-106*.
 23. Melis B, DeFranco M, Lädermann A, Molé D, Favard L, Nérot C, et al. An evaluation of the radiological changes around the Grammont reverse geometry shoulder arthroplasty after eight to 12 years. *J Bone Joint Surg Br* 2011;93:1240-6. <http://dx.doi.org/10.1302/0301-620X.93B9.25926>
 24. Nam D, Kepler CK, Nho SJ, Craig EV, Warren RF, Wright TM. Observations on retrieved humeral polyethylene components from reverse total shoulder arthroplasty. *J Shoulder Elbow Surg* 2010;19:1003-12. <http://dx.doi.org/10.1016/j.jse.2010.05.014>
 25. Nolan BM, Ankerson E, Wiater JM. Reverse total shoulder arthroplasty improves function in cuff tear arthropathy. *Clin Orthop Relat Res* 2011;469:2476-82. <http://dx.doi.org/10.1007/s11999-010-1683-z>
 26. Nyffeler RW, Werner CM, Gerber C. Biomechanical relevance of glenoid component positioning in the reverse Delta III total shoulder prosthesis. *J Shoulder Elbow Surg* 2005;14:524-8. <http://dx.doi.org/10.1016/j.jse.2004.09.010>
 27. Roche C, Flurin PH, Wright T, Crosby LA, Mauldin M, Zuckerman JD. An evaluation of the relationships between reverse shoulder design parameters and range of motion, impingement, and stability. *J Shoulder Elbow Surg* 2009;18:734-41. <http://dx.doi.org/10.1016/j.jse.2008.12.008>
 28. Roche CP, Marczuk Y, Wright TW, Flurin PH, Grey S, Jones R, et al. Scapular notching and osteophyte formation after reverse shoulder replacement: radiological analysis of implant position in male and female patients. *Bone Joint J* 2013;95-B:530-5. <http://dx.doi.org/10.1302/0301-620X.95B4.30442>
 29. Roche CP, Marczuk Y, Wright TW, Flurin PH, Grey SG, Jones RB, et al. Scapular notching in reverse shoulder arthroplasty: validation of a computer impingement model. *Bull Hosp Jt Dis (2013) 2013;71:278-83*.
 30. Roche CP, Stroud NJ, Martin BL, Steiler CA, Flurin PH, Wright TW, et al. The impact of scapular notching on reverse shoulder glenoid fixation. *J Shoulder Elbow Surg* 2013;22:963-70. <http://dx.doi.org/10.1016/j.jse.2012.10.035>
 31. Roy JS, MacDermid JC, Woodhouse LJ. Measuring shoulder function: a systematic review of four questionnaires. *Arthritis Rheum* 2009;61:623-32. <http://dx.doi.org/10.1002/art.24396>
 32. Sadoghi P, Leithner A, Vavken P, Hölzer A, Hochreiter J, Weber G, et al. Infraglenoidal scapular notching in reverse total shoulder replacement: a prospective series of 60 cases and systematic review of the literature. *BMC Musculoskelet Disord* 2011;12:101. <http://dx.doi.org/10.1186/1471-2474-12-101>
 33. Simovitch RW, Zumstein MA, Lohri E, Helmy N, Gerber C. Predictors of scapular notching in patients managed with the Delta III reverse total shoulder replacement. *J Bone Joint Surg Am* 2007;89:588-600. <http://dx.doi.org/10.2106/JBJS.F.00226>
 34. Sirveaux F, Favard L, Oudet D, Huquet D, Walch G, Molé D. Grammont inverted total shoulder arthroplasty in the treatment of glenohumeral osteoarthritis with massive rupture of the cuff. Results of a multicentre study of 80 shoulders. *J Bone Joint Surg Br* 2004;86:388-95. <http://dx.doi.org/10.1302/0301-620X.86B3.14024>
 35. Sperling JW, Cofield RH, O'Driscoll SW, Torchia ME, Rowland CM. Radiographic assessment of ingrowth total shoulder arthroplasty. *J Shoulder Elbow Surg* 2000;9:507-13.
 36. Stechel A, Fuhrmann U, Irlenbusch L, Rott O, Irlenbusch U. Reversed shoulder arthroplasty in cuff tear arthritis, fracture sequelae, and revision arthroplasty: Outcome in 59 patients followed for 2-7 years. *Acta Orthop* 2010;81:367-72. <http://dx.doi.org/10.3109/17453674.2010.487242>
 37. Torrens C, Santana F, Picazo B, Cáceres E. Retrospective study of scapular notches in reverse shoulder arthroplasties. *Am J Orthop (Belle Mead NJ)* 2013;42:362-5.
 38. Walker M, Willis MP, Brooks JP, Pupello D, Mulieri PJ, Frankle MA. The use of the reverse shoulder arthroplasty for treatment of failed total shoulder arthroplasty. *J Shoulder Elbow Surg* 2012;21:514-22. <http://dx.doi.org/10.1016/j.jse.2011.03.006>
 39. Werner CM, Steinmann PA, Gilbert M, Gerber C. Treatment of painful pseudoparesis due to irreparable rotator cuff dysfunction with the Delta III reverse-ball-and-socket total shoulder prosthesis. *J Bone Joint Surg Am* 2005;87:1476-86. <http://dx.doi.org/10.2106/JBJS.D.02342>



Sports after shoulder arthroplasty: a comparative analysis of hemiarthroplasty and reverse total shoulder replacement

Joseph N. Liu, MD^{a,*}, Grant H. Garcia, MD^a, Gregory Mahony, BA^b, Hao-Hua Wu, BA^c, David M. Dines, MD^b, Russell F. Warren, MD^b, Lawrence V. Gulotta, MD^b

^aDepartment of Orthopaedic Surgery, Hospital for Special Surgery, New York, NY, USA

^bSports Medicine and Shoulder Service, Hospital for Special Surgery, New York, NY, USA

^cPerelman School of Medicine, University of Pennsylvania, Philadelphia, PA, USA

Background: Traditionally, fewer postoperative sport restrictions are imposed on hemiarthroplasty (HHA) patients on than reverse total shoulder arthroplasty (RTSA) patients. However, functional outcomes have been shown to be superior in RTSA. No direct comparison of RTSA vs HHA has been done on rates of return to sports in patients with glenohumeral arthritis and rotator cuff dysfunction, proximal humeral fractures, or rheumatoid arthritis.

Methods: This is a retrospective review of consecutive RTSA and HHA patients collected from our institution's shoulder arthroplasty registry. All patients playing sports preoperatively with minimum 1-year follow-up were included. Final follow-up included an additional patient-reported questionnaire with questions regarding physical fitness and sport activities.

Results: The study included 102 RTSA and 71 HHA patients. Average age at surgery was 72.3 years for RTSA compared with 65.6 years for HHA ($P < .001$). Patients undergoing RTSA had improved visual analog scale scores compared with HHA (-5.6 vs -4.2 , $P = .007$), returned to sports after RTSA at a significantly higher rate (85.9% vs 66.7%, $P = .02$), and were more likely to be satisfied with their ability to play sports ($P = .013$). HHA patients were also more likely to have postoperative complaints than RTSA patients (63% vs 29%, $P < .0001$). No sports-related complications occurred. Female sex, age < 70 years, surgery on the dominant extremity, and a preoperative diagnosis of arthritis with rotator cuff dysfunction predicted a higher likelihood of return to sports for patients undergoing RTSA compared with HHA.

Conclusions: Despite traditional sport restrictions placed on RTSA, patients undergoing RTSA can return to sports at rates higher than those undergoing HHA, with fewer postoperative complaints.

Level of evidence: Level III; Retrospective Cohort Design; Treatment Study

© 2016 Journal of Shoulder and Elbow Surgery Board of Trustees.

Keywords: Reverse total shoulder arthroplasty; hemiarthroplasty; sports; shoulder replacement; physical fitness; return to activity

The Hospital for Special Surgery Institutional Review Board approved this study (Study #2014-202 and #2014-033).

*Reprint requests: Joseph Liu, MD, Hospital for Special Surgery, 535 E 70th St, New York, NY 10021, USA.

E-mail address: LiuJ@hss.edu (J. Liu).

Physical fitness is an important consideration for patients undergoing joint replacement. Studies have demonstrated improved surgical satisfaction is associated with return to preoperative activity levels.²⁴ Evaluations of patient return to

activities have been extensively studied in hip and knee arthroplasty, demonstrating that up to 90% of patients resume preoperative physical activities.^{9,22,25} Despite the plethora of lower extremity data, more recent interest has developed evaluating athletics after shoulder replacement.^{11,14,18,22,27}

It is generally accepted that patients with glenohumeral osteoarthritis and an intact rotator cuff achieve the best results with anatomic total shoulder arthroplasty (TSA). However, in patients with rotator cuff dysfunction due to tears, denervation, inflammatory arthropathies, or fracture, surgeons and patients must decide whether to undergo humeral hemiarthroplasty (HHA) or reverse total shoulder arthroplasty (RTSA).^{2,15,23} HHA has been traditionally thought to be the safer option compared with RTSA for patients who wish to remain active because there is less risk of failure.

The ability of patients to return to their sporting activities after these 2 procedures has not been directly compared, however. Recent studies surveying shoulder surgeons show that they often place fewer postoperative sports restrictions on HHA patients than on those undergoing RTSA.^{7,13} As such, despite recent literature demonstrating improved functional and range of motion (ROM) outcomes for RTSA compared with HHA,^{1,3,5,12,26} surgeons may be inclined to perform the “safer” HHA operation on patients given their preference to return to more physical activities.

Limited literature exists evaluating RTSA or HHA and return to physical activities. The most recent evaluation of RTSA found up to 85% return to sport,⁶ whereas other studies have found similar postoperative participation without reporting specific rates of return.¹¹ Rates of return to physical activities range from 75% to 81% in the HHA literature, although most involved small cohorts.^{14,21,27} Although these rates aid in managing the expectations of patients undergoing these individual procedures, no study has directly compared rates of return to sports after RTSA and HHA or sports-related complications.

The purpose of this study was to determine if patients who are not candidates for anatomic TSA due to rotator cuff dysfunction, rheumatoid arthritis, or proximal humeral fracture had better return to sports when they underwent HHA compared with RTSA. We hypothesized that patients undergoing RTSA would return to preoperative physical activities at an equal level as patients undergoing HHA, with no additional increase in rate of complications from participation in sports. Secondly, we hypothesized that the RTSA cohort would have better functional and satisfaction outcomes than HHA patients with similar diagnoses.

Materials and methods

A prospectively collected shoulder arthroplasty registry was queried retrospectively for consecutive patients who under-

went HHA or RTSA from 2007 to 2013. All patients must have had a contraindication for an anatomic TSA, including rotator cuff dysfunction, inflammatory arthritis, or proximal humeral fracture. Therefore, all patients met indications criteria to receive HHA or RTSA. The decision between these 2 procedures was determined by shared decision making between the surgeons and the patients.

All patients in the cohort received a Biomet Comprehensive Reverse Total Shoulder Arthroplasty or a Biomet Comprehensive Hemiarthroplasty (Warsaw, IN, USA). Patients who underwent revision procedures and bilateral procedures were also included. Patients were excluded if they had follow-up of less than 1 year. Deceased status was confirmed using Social Security records. Patients unreachable after 5 telephone attempts and 1 mailing were considered lost to follow-up. Finally, during telephone interviews, patients who had not participated in a sport within 3 years preoperatively were excluded.

After applying our initial inclusion and exclusion criteria, 132 consecutive patients had undergone RTSA at a single institution with a least 1 year of follow-up, and 97 patients underwent HHA with at least 1 year of follow-up for the aforementioned indications. In the RTSA group, 21 patients were lost to follow-up, 5 patients declined to respond to the survey, and 4 had died. Thus, 102 RTSA patients were interviewed by phone. In the HHA group, 17 patients were lost to follow-up, 2 declined to participate, and 7 patients had died, leaving 71 patients remaining available for interview. All analyses were performed per-patient because only 4 patients underwent bilateral HHA.

Clinic and operative records for eligible patients were reviewed for preoperative diagnosis, body mass index (BMI), age, other medical comorbidities, and operative complications. The information obtained from the records was cross-referenced with patients during the telephone interview. Prospectively collected preoperative American Shoulder and Elbow Society (ASES) and visual analog scale (VAS) pain scores were also obtained from the shoulder arthroplasty registry.

The telephone interview used an outcome questionnaire (Appendix S1) based on the work by McCarty et al¹⁴ and other studies on return to sport after arthroplasty.^{7,25} This questionnaire included demographic data, preoperative activity assessment (including sports participation),^{7,8} postoperative activity assessment, and subjective fitness level. The fitness sports category was based on a similar categorization by prior studies^{16,25} and was defined as lightweight training or resistance bands (not used for physical therapy) with gym attendance greater than 2 hours weekly. No patient in either cohort participated in heavy weight lifting. If a sport was stopped postoperatively, we recorded the reason for discontinuation. Direct rates of return were calculated for each sport, but only if the patients participated in that specific sport preoperatively. New sports started postoperatively were recorded separately. Finally, ASES and VAS questionnaires were administered.¹⁸

Postoperative sports protocol

A similar postoperative rehabilitation protocol was followed for HHA and RTSA, which included 4 weeks in a sling, with the initiation of passive ROM at 2 weeks, active ROM at 6 weeks, and strengthening at 3 months. Prior recreational activities and work were encouraged after 3 months. The only restriction verbalized to the patient was to avoid contact sports.

Statistics

After skewness and kurtosis analysis a normally distributed data set, comparative differences between the study groups were done using independent-sample *t* tests for continuous variables and χ^2 and Fisher exact tests for categorical variables. Changes in patient-reported outcome measures were assessed using paired-sample *t* tests. Subanalyses were then performed by controlling for sex, age, and preoperative diagnoses. Patients with arthritis with rotator cuff dysfunction or rotator cuff tear arthropathy were grouped for analysis because they represent a similar group of patients in whom surgeons would consider performing HHA or RTSA: the competency of the rotator cuff in these patients was seen as a contraindication to anatomic TSA. All tests used 2-sided hypothesis testing with statistical significance set at $P < .05$ and were conducted with SPSS 19.0 software (IBM Corp, Armonk, NY, USA).

Results

Demographics

Compared with the HHA group, patients undergoing RTSA were generally older at the time of surgery (72.3 vs 65.6 years, $P < .001$) and at the time of follow-up (74.3 vs 70.9 years, $P = .014$). Average follow up was 31.7 months (range, 11.5-65 months) for RTSA and 62.9 months (range, 13-90.2 months) for HHA ($P < .001$). The gender proportions were equivalent, with a predominance of women in both groups (67.6% vs 67.6%, $P = 1$), and the average BMI (28.3 vs 28.5 kg/m², $P = .87$) was essentially equal. Both groups had similar distributions of surgery on their dominant extremity (RTSA: 56.9% vs HHA: 60.6%, $P = .64$; Table I).

Validated outcome measures

In terms of overall outcome measures, both groups had statistically significant improvements in the VAS score and ASES score after RTSA (Tables II and III). There was, however, better improvement in the VAS pain score for RTSA than for HHA (-5.64 vs -4.15, $P = .007$), which was more pronounced for patients older than age 70. There was no difference in the change in the ASES score (+38.8 vs +36.5, $P = .63$) regardless of diagnosis, gender, or age (Table III). Women also had

Table I Demographics of hemiarthroplasty and reverse total shoulder arthroplasty cohorts

Variable	HHA (n = 71) No. (%)	RTSA (n = 102) No. (%)	P value*
Diagnosis			
Arthritis + RCD	51 (71.8)	80 (78.4)	.3688
Proximal humeral fractures	17 (23.9)	17 (17.1)	.2493
Rheumatoid arthritis	3 (4.2)	5 (5.2)	1
Age, y			
<70	47 (66.2)	44 (43.1)	.0033
>70	24 (33.8)	58 (56.9)	.0033
Gender			
Male	23 (32.4)	33 (32.4)	1
Female	48 (67.6)	69 (67.6)	1
Extremity			
Dominant	43 (60.6)	58 (56.9)	.6418
Nondominant	28 (39.4)	44 (43.1)	.6418

HHA, hemiarthroplasty; RTSA, reverse total shoulder arthroplasty; RCD, rotator cuff dysfunction.

* Values in bold are statistically significant ($P < .05$).

Table II Change in visual analog scale score after shoulder arthroplasty

Variable	HHA	RTSA	P value*
Overall	-4.15	-5.64	.007
Diagnosis			
Arthritis + RCD	-3.90	-5.61	.008
Proximal humeral fractures	-4.24	-6.35	.53
Rheumatoid arthritis	-6.53	-6.58	.97
Age, y			
<70	-4.56	-5.66	.133
>70	-3.36	-5.61	.018
Gender			
Males	-4.78	-5.50	.44
Females	-3.84	-5.71	.007
Extremity			
Dominant	-3.94	-5.30	.057
Nondominant	-4.46	-6.12	.047

HHA, hemiarthroplasty; RCD, rotator cuff dysfunction; RTSA, reverse total shoulder arthroplasty.

* Values in bold are statistically significant ($P < .05$).

greater pain improvement after RTSA than after HHA (Table II). When subdivided by diagnosis, patients with arthritis and rotator cuff dysfunction had more improvement in their VAS pain scores postoperatively with RTSA than with HHA (Table II).

HHA patients were also more likely to have postoperative complaints than RTSA patients (63% vs 29%, $P < .0001$). Most commonly, 45% (32 of 71) of patients undergoing HHA complained of chronic pain and 32.4% (23 of 71) complained of stiffness compared with 10.5% (11 of 102) complaining of pain and 11.8% (12 of 102) complaining of stiffness in patients undergoing RTSA.

Table III Change in American Shoulder and Elbow Surgeons score after shoulder arthroplasty

Variable	HHA	RTSA	P value
Overall	+37	+39	.63
Diagnosis			
Arthritis + RCD	+34	+43	.083
Proximal humeral fractures	+34	+45	.48
Rheumatoid arthritis	+52	+61	.51
Age, y			
<70	+42	+42	.96
>70	+30	+38	.33
Gender			
Males	+42	+39	.96
Females	+35	+40	.44
Extremity			
Dominant	+33	+41	.21
Nondominant	+45	+39	.44

HHA, hemiarthroplasty; RCD, rotator cuff dysfunction; RTSA, reverse total shoulder arthroplasty.

Return to sports

A similar proportion of patients in both groups participated in sports preoperatively (HHA: 71.8% vs RTSA: 74.5%, $P = .73$). The average age of patients who participated in sports preoperatively was younger in the HHA group than in the RTSA group (63.51 vs 72.26 years, $P < .05$). RTSA patients returned to sports at a significantly higher rate (85.9% vs 66.7%, $P = .0154$). For those who returned, average time to full return to sports did not differ between the 2 groups (HHA: 6.2 months vs RTSA: 5.3 months, $P = .40$). Comorbidities and BMI had no effect on return to sport in either cohort.

For men, there was no difference in the rate of return between HHA and RTSA (68.1% vs 88.5%, $P = .15$). For women, the rate of return was higher for RTSA compared with HHA (88% vs 65.5%, $P = .022$; Table IV). When controlling for age, there was a significant difference in the rate of return to sports for patients younger than 70 years for RTSA compared with HHA (96.8% vs 65.0%, $P < .001$) but not for patients older than age 70 (81.2% vs 72.7%, $P = .67$). When controlling for surgery on the dominant vs nondominant extremity, patients undergoing RTSA had higher rates of return than those undergoing HHA for their dominant extremity only ($P = .004$).

When subanalyzed by diagnosis, overall rates of return to at least 1 sport only differed for the group with arthritis and rotator cuff dysfunction (RTSA: 89.8% vs HHA: 65.7%, $P < .01$). There was no difference in rates of return for proximal humeral fractures (76.9% vs 76.9%, $P = 1$), or rheumatoid arthritis (100% vs 33%, $P = .14$; Table IV).

Fitness sports, swimming, and cycling were among the top sports that patients returned to postoperatively in both groups. Patients returned to fitness sports at a greater rate after

undergoing RTSA than after HHA, but there was no difference between RTSA or HHA for sport-specific rates of return when categorized by level of impact (Table V).

Preoperative fitness levels and postoperative satisfaction

Preoperatively, there was no difference in the proportion of patients participating in 2 or more hours of physical fitness between the HHA and RTSA groups (60.5% vs 66.7%, $P = .42$). A similar percentage of patients in both groups felt their physical fitness improved (HHA: 40.8% vs RTSA: 41.1%, $P = 1$). More patients undergoing RTSA felt their sports outcome was good to excellent compared with patients undergoing HHA (86.3% vs 62.0%, $P = .013$). The proportion of patients who felt they had good to excellent surgical outcomes was also higher in the RTSA group (92.2% vs 81.6%, $P = .0566$). There were no sport-related complications in either group.

Discussion

Return to sports and physical activities has become an increasingly important part of patient satisfaction after orthopedic surgical procedures. There is a relative paucity of studies regarding return to sports in the shoulder arthroplasty literature compared with the literature in hip and knee arthroplasty. The lack of data on shoulder arthroplasty return to sports may be partly due to a lack of consensus among shoulder surgeons and the perceived need for surgeons to restrict patients' activity after shoulder arthroplasty, with HHA perceived to be "safer" than RTSA for patients who wish to return to sports.^{7,13}

This study is one of the largest to compare return to activity after RTSA vs HHA and the first to directly compare sport-specific rates between the 2 shoulder arthroplasty groups. The study was designed to help surgeons and patients decide between HHA and RTSA when TSA is contraindicated. In this investigation, we found that patients undergoing RTSA returned to ≥ 1 sporting activity at a higher rate than patients undergoing HHA, without an increase in sports-related complications. Also, more RTSA patients had subjectively higher satisfaction with their surgery and their ability to return to sports. Age, gender, surgery on the dominant vs nondominant extremity, and preoperative diagnosis were among the most important variables affecting return to sport. Specifically, women, patients younger than age 70, surgery on the dominant extremity, and patients with a preoperative diagnosis of arthritis/rotator cuff dysfunction returned to sports at a much higher rate after RTSA than after HHA.

In terms of sports-specific return rates, aside from fitness sports, the rates of return for the most commonly reported sports, such as swimming, cycling, doubles tennis, golf,

Table IV Return to ≥ 1 sport after shoulder arthroplasty surgery

Variable	HHA	RTSA	P value*
	No (%)	No (%)	
Overall	34/51 (66.7)	67/76 (88.2)	.0063
Diagnosis			
Arthritis + RCD	23/35 (65.7)	53/59 (89.8)	.0063
Proximal humeral fractures	10/13 (76.9)	10/13 (76.9)	1
Rheumatoid arthritis	1/3 (33)	4/4 (100)	.14
Age, y			
<70	26/40 (65.0)	31/32 (96.8)	.0009
>70	8/11 (72.7)	36/44 (81.2)	.6741
Gender			
Males	15/22 (68.1)	23/26 (88.5)	.15
Females	19/29 (65.5)	44/50 (88)	.022
Extremity			
Dominant	16/30 (53.3)	40/47 (85.1)	.0036
Nondominant	18/21 (85.7)	27/29 (93.1)	.64

HHA, hemiarthroplasty; RCD, rotator cuff dysfunction; RTSA, reverse total shoulder arthroplasty.

* Values in bold are statistically significant ($P < .05$).

Table V Top activities for patients before and after shoulder arthroplasty

Sport	Within 3 y before RTSA	After RTSA	Rate of return	Within 3 y before HHA	After HHA	Rate of return	P value*
	(No.)	(No.)	(%)	(No.)	(No.)	(%)	
Noncontact high-load sports							
Singles tennis	12	4	33.3	5	3	60	.59
Doubles tennis	8	3	37.5	6	4	66.7	.59
Softball/baseball	1	1	100	4	2	50	1
Noncontact low-load sports							
Swimming	33	23	69.7	15	9	60	.53
Fitness sports	27	27	100	13	9	69.2	.008
Golf	20	11	55	13	7	53.8	1
Cycling	12	8	66.7	7	4	57.1	1
Fishing	4	1	25	1	1	100	.4
Rowing	1	1	100	1	1	100	1
Non-upper extremity sports [†]							
Running	7	5	71.4	10	7	70	1
Downhill skiing	7	2	28.6	5	2	40	1
Dancing	2	1	50	2	1	50	1
Horseback riding	2	1	50	1	0	0	1
Contact sports							
Basketball	1	1	100	2	1	50	1

HHA, hemiarthroplasty; RTSA, reverse total shoulder arthroplasty.

* Values in bold are statistically significant ($P < .05$).

[†] With risk of falling.

downhill skiing, and singles tennis, were equivalent between RTSA and HHA; these values were lower on average, however, than those rates reported after TSA.^{14,18} We also found an essentially equivalent average time to return to full sports between HHA (6.2 months) and RTSA (5.3 months), which is comparable to the time reported in the TSA literature, which ranges from 4.5 to 11.2 months.^{10,14,18}

An important weakness of this study is the heterogeneity of the RTSA and HHA groups. Although there was no difference in gender proportion, proportion of surgery on the dominant extremity, BMI, or associated comorbidities, the RTSA cohort was on average older and had less follow-up than the HHA group. These differences create the potential for significant bias, but they occurred due to increasing

familiarity of the surgeons with RTSA during the study period. The more comfortable the surgeons became with the technique, outcomes, and expected complications, the more the indications for the procedure expanded.

Our experience is representative of national trends in RTSA use.¹⁷ However, it is possible that younger patients and those with higher functional expectations may have been counseled preoperatively toward HHA rather than to RTSA. In addition, lower expectations set at the time of surgery for RTSA may have led to a false sense of subjective success in postoperative ratings or patient satisfaction, or both.

Subanalyses controlling for those variables were performed to account for these differences (Tables II-IV). Of particular note, the rate of return to sports for RTSA compared with HHA was actually slightly more pronounced for patients younger than 70 years. However, by subdividing the cohort, some of our other statistical power decreased. This may explain why prior literature^{1,3,5,12,26} comparing RTSA vs HHA demonstrated improved functional outcomes for patients undergoing RTSA for rotator cuff arthropathy and proximal humeral fractures; however, these studies did not include any analysis on the rate of postoperative return to sports.

Our results did not reach statistical significance with regards to improvements in the ASES score when selecting for those specific diagnoses. Nevertheless, the difference in VAS pain score improvement was significant. In addition, our rates of return for specific diagnoses after HHA or RTSA are consistent with past rates reported in the literature in the elderly population.^{20,21}

Other limitations inherent to this study are its retrospective nature and potential for patient recall bias as well as investigator bias given the use of a telephone survey. However, telephone surveys have demonstrated a greater patient response rate compared with mailed surveys,¹⁹ and thus, our cohorts may be more diverse and representative. We also attempted to reduce patient recall bias by cross-referencing patient records when available.

Although both cohorts demonstrated success in return to noncontact high-load sports without sports-related complications and on average experienced improved VAS and ASES scores, caution should be used when applying these conclusions long-term. The average follow-up for the RTSA group and HHA group was 31 and 62 months respectively, without a final physical examination or radiographic assessment, which is left out in many studies regarding return to sports after shoulder arthroplasty.^{4,11,14,27} The lack of radiographic data to record possible wear, loosening, or other signs of hardware damage may discourage some orthopedic surgeons from recommending return to sports. Nevertheless, the lack of patient-reported complications as a result of participating in a wide-variety of sports as well as focus on ASES and VAS pain scores gives orthopedic surgeons a platform to discuss and manage patient expectations regard-

ing outcomes with respect to these 2 shoulder arthroplasty options.

Conclusions

Although postoperative activity restrictions have traditionally been the most stringent after RTSA, this study's findings suggest that patients undergoing RTSA can safely return to ≥ 1 sport at rates higher than those for HHA without an increase in sports-related complications. Women, patients aged younger than 70, surgery on the dominant extremity, and patients with a preoperative diagnosis of osteoarthritis with rotator cuff dysfunction predicted a higher rate of return to sport after RTSA compared with HHA. In addition, RTSA patients have significantly fewer postoperative complaints and are more likely to be satisfied with their sports outcomes than HHA patients. The reported outcomes in this study should help dispel the myth that HHA more reliably returns patients to sports compared with RTSA and help orthopedic surgeons manage patient expectations when discussing these 2 shoulder arthroplasties.

Disclaimer

David M. Dines and Russell F. Warren receive royalties from Biomet, which is related to the subject of this work. Lawrence V. Gulotta receives consultant payments from Biomet, which is related to the subject of this work. The other authors, their immediate families, and any research foundations with which they are affiliated have not received any financial payments or other benefits from any commercial entity related to the subject of this article.

Supplementary data

Supplementary data related to this article can be found online at doi:10.1016/j.jse.2015.11.003.

References

- Alentorn-Geli E, Guirro P, Santana F, Torrens C. Treatment of fracture sequelae of the proximal humerus: comparison of hemiarthroplasty and reverse total shoulder arthroplasty. *Arch Orthop Trauma Surg* 2014;134:1545-50. <http://dx.doi.org/10.1007/s00402-014-2074-9>
- Boileau P, Watkinson D, Hatzidakis AM, Hovorka I. Neer Award 2005: the Grammont reverse shoulder prosthesis: results in cuff tear arthritis, fracture sequelae, and revision arthroplasty. *J Shoulder Elbow Surg* 2006;15:527-40. <http://dx.doi.org/10.1016/j.jse.2006.01.003>
- Boyle MJ, Youn SM, Frampton CM, Ball CM. Functional outcomes of reverse shoulder arthroplasty compared with hemiarthroplasty for acute proximal humeral fractures. *J Shoulder Elbow Surg* 2013;22:32-7. <http://dx.doi.org/10.1016/j.jse.2012.03.006>
- Bulhoff M, Sattler P, Bruckner T, Loew M, Zeifang F, Raiss P. Do patients return to sports and work after total shoulder replacement

- surgery? *Am J Sports Med* 2015;43:423-7. <http://dx.doi.org/10.1177/0363546514557940>
5. Ferrel JR, Trinh TQ, Fischer RA. Reverse total shoulder arthroplasty versus hemiarthroplasty for proximal humeral fractures: a systematic review. *J Orthop Trauma* 2015;29:60-8. <http://dx.doi.org/10.1097/BOT.0000000000000224>
 6. Garcia GH, Taylor SA, DePalma BJ, Mahony GT, Grawe BM, Nguyen J, et al. Patient activity levels after reverse total shoulder arthroplasty: what are patients doing? *Am J Sports Med* 2015;43:2816-21. <http://dx.doi.org/10.1177/0363546515597673>
 7. Golant A, Christoforou D, Zuckerman JD, Kwon YW. Return to sports after shoulder arthroplasty: a survey of surgeons' preferences. *J Shoulder Elbow Surg* 2012;21:554-60. <http://dx.doi.org/10.1016/j.jse.2010.11.021>
 8. Healy WL, Iorio R, Lemos MJ. Athletic activity after joint replacement. *Am J Sports Med* 2001;29:377-88.
 9. Huch K, Muller KA, Sturmer T, Brenner H, Puhl W, Gunther KP. Sports activities 5 years after total knee or hip arthroplasty: the Ulm Osteoarthritis Study. *Ann Rheum Dis* 2005;64:1715-20. <http://dx.doi.org/10.1136/ard.2004.033266>
 10. Jensen KL, Rockwood CA Jr. Shoulder arthroplasty in recreational golfers. *J Shoulder Elbow Surg* 1998;7:362-7.
 11. Lawrence TM, Ahmadi S, Sanchez-Sotelo J, Sperling JW, Cofield RH. Patient reported activities after reverse shoulder arthroplasty: part II. *J Shoulder Elbow Surg* 2012;21:1464-9. <http://dx.doi.org/10.1016/j.jse.2011.11.012>
 12. Leung B, Horodyski M, Struk AM, Wright TW. Functional outcome of hemiarthroplasty compared with reverse total shoulder arthroplasty in the treatment of rotator cuff tear arthropathy. *J Shoulder Elbow Surg* 2012;21:319-23. <http://dx.doi.org/10.1016/j.jse.2011.05.023>
 13. Magnussen RA, Mallon WJ, Willems WJ, Moorman CT 3rd. Long-term activity restrictions after shoulder arthroplasty: an international survey of experienced shoulder surgeons. *J Shoulder Elbow Surg* 2011;20:281-9. <http://dx.doi.org/10.1016/j.jse.2010.07.021>
 14. McCarty EC, Marx RG, Maerz D, Altchek D, Warren RF. Sports participation after shoulder replacement surgery. *Am J Sports Med* 2008;36:1577-81. <http://dx.doi.org/10.1177/0363546508317126>
 15. Mulieri P, Dunning P, Klein S, Pupello D, Frankle M. Reverse shoulder arthroplasty for the treatment of irreparable rotator cuff tear without glenohumeral arthritis. *J Bone Joint Surg Am* 2010;92:2544-56. <http://dx.doi.org/10.2106/JBJS.I.00912>
 16. Naal FD, Fischer M, Preuss A, Goldhahn J, von Knoch F, Preiss S, et al. Return to sports and recreational activity after unicompartmental knee arthroplasty. *Am J Sports Med* 2007;35:1688-95. <http://dx.doi.org/10.1177/0363546507303562>
 17. Schairer WW, Nwachukwu BU, Lyman S, Craig EV, Gulotta LV. National utilization of reverse total shoulder arthroplasty in the United States. *J Shoulder Elbow Surg* 2015;24:91-7. <http://dx.doi.org/10.1016/j.jse.2014.08.026>
 18. Schumann K, Flury MP, Schwyzer HK, Simmen BR, Drerup S, Goldhahn J. Sports activity after anatomical total shoulder arthroplasty. *Am J Sports Med* 2010;38:2097-105. <http://dx.doi.org/10.1177/0363546510371368>
 19. Siemiatycki J. A comparison of mail, telephone, and home interview strategies for household health surveys. *Am J Public Health* 1979;69:238-45.
 20. Simovitch RW, Gerard BK, Brees JA, Fullick R, Kears JC. Outcomes of reverse total shoulder arthroplasty in a senior athletic population. *J Shoulder Elbow Surg* 2015;24:1481-5. <http://dx.doi.org/10.1016/j.jse.2015.03.011>
 21. Skutek M, Fremerey RW, Bosch U. Level of physical activity in elderly patients after hemiarthroplasty for three- and four-part fractures of the proximal humerus. *Arch Orthop Trauma Surg* 1998;117:252-5.
 22. Vogel LA, Carotenuto G, Basti JJ, Levine WN. Physical activity after total joint arthroplasty. *Sports Health* 2011;3:441-50. <http://dx.doi.org/10.1177/1941738111415826>
 23. Wall B, Nové-Josserand L, O'Connor DP, Edwards TB, Walch G. Reverse total shoulder arthroplasty: a review of results according to etiology. *J Bone Joint Surg Am* 2007;89:1476-85. <http://dx.doi.org/10.2106/JBJS.F.00666>
 24. Weiss JM, Noble PC, Condit MA, Kohl HW, Roberts S, Cook KF, et al. What functional activities are important to patients with knee replacements? *Clin Orthop Relat Res* 2002;404:172-88. <http://dx.doi.org/10.1097/00003086-200211000-00030>
 25. Wylde V, Blom A, Dieppe P, Hewlett S, Learmonth I. Return to sport after joint replacement. *J Bone Joint Surg Br* 2008;90:920-3.
 26. Young SW, Zhu M, Walker CG, Poon PC. Comparison of functional outcomes of reverse shoulder arthroplasty with those of hemiarthroplasty in the treatment of cuff-tear arthropathy: a matched-pair analysis. *J Bone Joint Surg Am* 2013;95:910-5. <http://dx.doi.org/10.2106/JBJS.L.00302>
 27. Zarkadas PC, Throckmorton TQ, Dahm DL, Sperling J, Schleck CD, Cofield R. Patient reported activities after shoulder replacement: total and hemiarthroplasty. *J Shoulder Elbow Surg* 2011;20:273-80. <http://dx.doi.org/10.1016/j.jse.2010.06.007>



Preoperative patient-reported scores can predict postoperative outcomes after shoulder arthroplasty



Stephanie E. Wong, MD*, Alan L. Zhang, MD, Jonathan L. Berliner, MD, C. Benjamin Ma, MD, Brian T. Feeley, MD

Department of Orthopaedics, University of California, San Francisco, San Francisco, CA, USA

Background: Total shoulder arthroplasty and reverse total shoulder arthroplasty are increasingly used to improve pain and function in patients with glenohumeral arthritis or cuff tear arthropathy. Our objective was to determine if preoperative patient-reported outcome measures predict which patients will achieve clinically meaningful improvements after shoulder arthroplasty.

Methods: Preoperative and 1-year postoperative 12-Item Short Form Health Survey (SF-12) Physical Component Summary (PCS) and Mental Component Summary (MCS) scores and American Shoulder and Elbow Surgeons (ASES) pain and function scores were prospectively collected from 107 patients who underwent total or reverse shoulder arthroplasty. The minimum clinically important difference (MCID) defined meaningful clinical improvement. Receiver operating characteristic analysis was used to calculate threshold values and *C* statistic. Multivariate logistic regression analysis was performed to determine preoperative measures that were indicative of achieving the MCID postoperatively.

Results: Threshold values below which patients were more likely to achieve MCID were 12 for ASES function, 25 for ASES pain, 46 for SF-12 PCS, and 42 for SF-12 MCS. Multivariate analysis revealed that preoperative ASES function (area under the curve, 0.79; $P = .006$) and ASES pain (area under the curve, 0.90; $P < .001$) measures were predictive of achieving the MCID postoperatively. Patients with higher preoperative SF-12 MCS scores had a higher likelihood of achieving MCID for each measure.

Conclusion: We determined threshold values that predict clinically meaningful improvement after shoulder arthroplasty. Patients with higher preoperative mental health scores and lower physical function and pain scores were more likely to gain significant benefits from surgery. These results can be used to facilitate shared decision-making and to forecast expected benefits after shoulder arthroplasty.

Level of evidence: Level II; Retrospective Design; Prognosis Study

© 2016 Journal of Shoulder and Elbow Surgery Board of Trustees.

Keywords: Total shoulder arthroplasty; reverse total shoulder arthroplasty; patient-reported outcomes; shoulder arthroplasty outcomes; ASES score; SF-12 score

This study has been approved by the UCSF Institutional Review Board (#10-02764).

*Reprint requests: Stephanie E. Wong, MD, University of California, 500 Parnassus Avenue, MU 320 West, San Francisco, CA 94143, USA.

E-mail address: Stephanie.wong2@ucsf.edu (S.E. Wong).

Shoulder arthroplasty is a highly effective procedure for improving function and decreasing pain in patients with glenohumeral disease or rotator cuff tear arthropathy. Since the development of total shoulder arthroplasty (TSA) by Neer in

the 1970s,²¹ very good medium- and long-term results have been demonstrated with TSA.^{5,12,26} More recently, reverse total shoulder arthroplasty (RTSA) has become a popular option, particularly in the setting of rotator cuff deficiency or revision. Although early studies of RTSA showed higher complication rates compared with conventional TSA,^{8,11,17,29} recent studies demonstrate outcomes and complication rates similar to those of TSA.^{18,24,33}

An increasing number of TSAs and RTSAs are being performed for degenerative shoulder disease.^{16,30-32} Despite the overall success of shoulder arthroplasty, certain patients experience less than optimal clinical or functional results after surgery.^{9,14} In addition, differences exist in patient selection based on age, gender, body mass index (BMI), and geographic region. These findings emphasize the importance of understanding factors that contribute to patient outcomes after shoulder arthroplasty. In recent years, evaluation of the success of procedures has shifted away from physician-based measures toward patient-reported outcome measures (PROMs), many of which have been used to describe outcomes after arthroplasty.^{22,28}

Preoperative assessment provides insight into the patient's perception of his or her preoperative level of function and pain and is an important predictor of postoperative outcome in hip and knee arthroplasty.² Postoperatively, PROMs demonstrate the impact of arthroplasty on pain, function, and patient satisfaction. In total hip arthroplasty, preoperative pain and function (both mental and physical) have been shown to be strongly predictive of postoperative pain and functional status.^{1,2,7,15,23} Total hip arthroplasty patients with worse baseline pain and function scores had greater absolute improvement but still had overall worse outcomes compared with patients with better preoperative status.¹⁵ Thus, the use of preoperative pain and function levels can guide discussion with patients about expected benefit after arthroplasty and support shared decision-making processes.²

Current studies have reported clinical, patient-reported, and radiographic outcomes as well as complications of TSA and RTSA, but none have investigated the association between preoperative patient function and postoperative outcomes.^{3,5,12,18,24,26,33} The objective of this study was to determine if preoperative PROMs predict which patients will achieve clinically meaningful improvements after TSA and RTSA. We hypothesized that threshold values will define the probability of achieving these improvements and that shoulder-specific outcome measures will be better predictors than those that measure general health.

Materials and methods

Data for this study were obtained from a prospectively collected shoulder arthroplasty outcomes database maintained at the authors' institution. The shoulder arthroplasty surgeries included in this study were performed by 3 sports medicine

and shoulder fellowship-trained orthopedic surgeons (C.B.M., B.T.F., A.L.Z.).

There were no major complications in the study population. A team of research assistants enrolled patients during clinic visits and collected demographic information and patient-reported outcome surveys on paper. These data were then entered into a privacy-protected electronic database (Research Electronic Data Capture [REDCap] system). The database includes demographic information (age, gender, BMI) and patient-reported outcome scores for TSA and RTSA. Preoperative and 1-year postoperative 12-Item Short Form Health Survey (SF-12) Physical Component Summary (PCS) and Mental Component Summary (MCS) scores as well as American Shoulder and Elbow Surgeons (ASES) pain and function scores were assessed from patients who underwent primary TSA or RTSA with Food and Drug Administration–approved shoulder arthroplasty implants at a single institution between 2011 and 2014. Patients included in the study had preoperative patient-reported outcome scores and at least 1 year of postoperative follow-up. Exclusion criteria were patients with pathologic fracture or malignant neoplasm.

There were 107 patients who met our inclusion criteria. This represents 81% of the 132 patients undergoing either TSA (50 patients) or RTSA (82 patients) in our shoulder arthroplasty outcomes database for the study period. Twenty-five patients were not included because they were lost to follow-up. The most common primary diagnosis was osteoarthritis (45%), followed by rotator cuff arthropathy (29%). Table I shows the primary diagnosis for all included patients. The average age of the patients was 66.8 years (standard deviation, 11.6) for RTSA and 66.2 years (standard deviation, 9.9) for TSA. In the RTSA population, 52% were male compared with 59% in the TSA group. The average BMI was 34.6 for patients undergoing RTSA and 29.2 for those undergoing TSA.

SF-12 and ASES PROMs were collected preoperatively and 1 year postoperatively. Respective scores were determined using the scoring algorithms for each outcome measure. The SF-12 version 2 survey was used for this study, which includes the same 12 questions as the original SF-12 survey but has been modified to improve formatting and

Table I Primary diagnoses for patients undergoing shoulder arthroplasty

Diagnosis	Percentage of patients
Osteoarthritis	45
Rotator cuff arthropathy	29
Failed shoulder replacement	12
Infection	6
Fracture	4
Malunion	1.5
Avascular necrosis	1.5
Failed open reduction–internal fixation	1

readability. The SF-12 survey instrument includes 2 components, the Physical Component Summary (PCS) and Mental Component Summary (MCS) scales, which were used as separate outcomes in this study. Both the PCS and MCS scores are calculated from the 12-question survey; each component score ranges from 0 to 100, with a score of 0 indicating the lowest health level and a score of 100 indicating the highest level of health. The ASES tool includes pain and function subscales that range from 0 to 50 for each subscale, with 0 indicating worse pain and functional loss and 50 indicating no pain and excellent function. Similarly, for the ASES instrument, the ASES pain and ASES function scores for the operative shoulder were used as separate outcomes.

Statistical analysis

Outcome measure analysis

The patients were separated into quintiles on the basis of preoperative ASES pain, ASES function, SF-12 PCS, and SF-12 MCS scores. Differences between the quintiles in mean baseline to 1-year change score and mean 1-year postoperative score were determined with analysis of variance.

Minimum clinically important difference (MCID)

There are various ways to define a successful surgical outcome, one of which is the MCID. The MCID was used to signify the smallest difference that patients find meaningful.²⁵ Distribution-based approaches are commonly used methods to calculate MCIDs.³⁴ We used the distribution-based method to estimate the MCID, given the ease of calculation compared with anchor- and consensus-based methods of calculating MCID. MCID values were individually calculated using a previously described distribution-based method for the SF-12 PCS, SF-12 MCS, ASES pain, and ASES function scores as half the standard deviation of the change in score from the preoperative to the postoperative time point for that specific PROM.²⁵

Univariate receiver operating characteristic (ROC) curves

Threshold values for each outcomes tool (ASES pain, ASES function, SF-12 PCS, and SF-12 MCS) were determined by a nonparametric ROC analysis. The optimal threshold values were calculated using the Youden Index, a statistic tool that balances the sensitivity and specificity of a test.⁶ The area under the curve (AUC, or *C* statistic) of the ROC analysis provides an indication of the ability of the outcomes tool to predict if a patient would achieve the MCID. A *C* statistic of 0.5 indicates that the measure is no better than chance at predicting a result. A *C* statistic of >0.7 is considered a reasonable predictive model, and if it is >0.8, the model is considered excellent.¹⁰ For the purposes of this study, a *C* statistic >0.7 was used to indicate a reasonably good predictive model.

Logistic regression and multivariate ROC curves

A hierarchical multivariate logistic regression analysis was performed to control for patient variables including age, gender, and BMI. Logistic regression analysis was performed to determine the influence of preoperative SF-12 MCS score on the likelihood of one's achieving the MCID postoperatively. An example of the logistic regression analysis is shown for ASES function for all shoulder arthroplasty patients in Figure 1. Youden thresholds for the outcome measures (SF-12 PCS, ASES pain, and ASES function) were then calculated on the basis of a patient's preoperative SF-12 MCS score using the fitted logistic regression equation. Using the new threshold values, *C* statistics for the multivariate curves were generated to show the ability of the outcome measures SF-12 PCS, ASES pain, and ASES function to predict clinically meaningful improvements once preoperative SF-12 MCS scores were controlled for.

Results

Outcome measure analysis

For each of the patient-reported measures, patients were separated into quintiles to assess differences in outcomes (Fig. 2, A-D). Overall, patients in all quintiles demonstrated improvement in ASES function, ASES pain, and SF-12 PCS scores at 1 year after surgery (Fig. 2, A-C). Patients in the lowest quintiles based on preoperative ASES pain scores had lower postoperative scores but greater magnitude of improvement (Fig. 2, B). Patients with higher preoperative SF-12 MCS scores had higher likelihood of achieving MCID for each measure (Fig. 2, D).

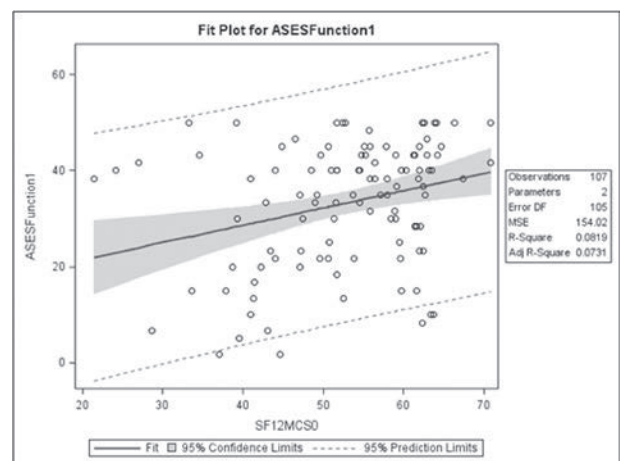


Figure 1 American Shoulder and Elbow Surgeons (ASES) function logistic regression analysis for all shoulder arthroplasty patients. SF12 MCS, 12-Item Short Form Health Survey Mental Component Summary.

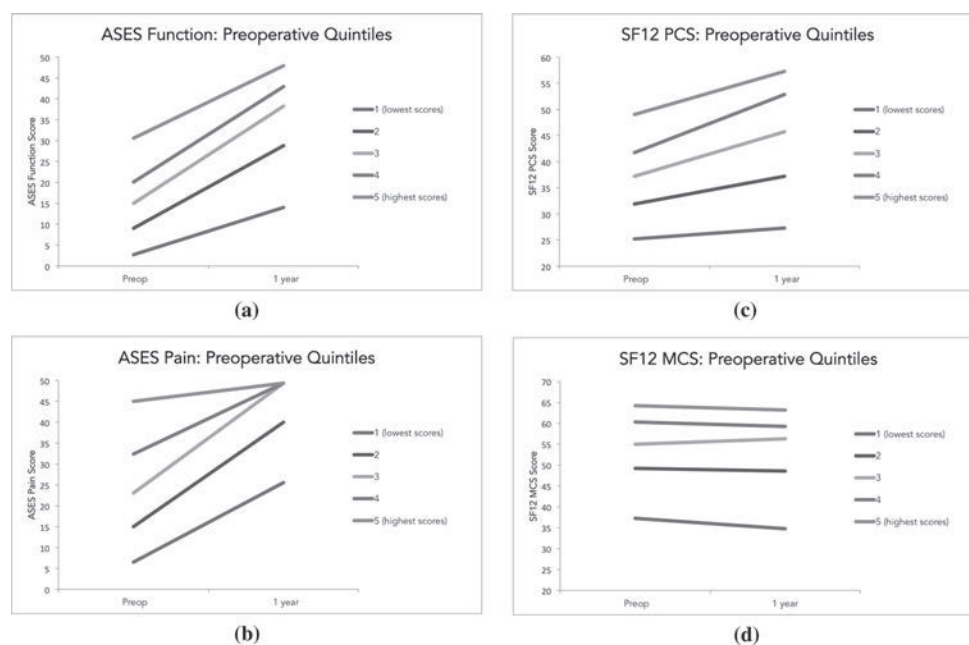


Figure 2 (A-D) Preoperative outcome measures predict postoperative outcome scores at 1-year follow-up. Patients in all quintiles demonstrated improvement in American Shoulder and Elbow Surgeons (ASES) function, ASES pain, and 12-Item Short Form Health Survey (SF12) Physical Component Summary (PCS) scores at 1 year after surgery (A-C). Patients in the lowest quintiles based on preoperative ASES pain scores had lower postoperative scores but greater magnitude of improvement (B). Patients with higher preoperative SF-12 Mental Component Summary (MCS) scores had higher likelihood of achieving MCID for each measure (D).

Table II MCID and threshold values for shoulder arthroplasty patients were defined by univariate analysis

	MCID	Threshold	AUC	Sensitivity	Specificity	P value
ASES function	6.5	<12	0.60	48%	74%	<.001
ASES pain	8.0	<25	0.79	83%	69%	<.001
SF-12 PCS	5.4	<46	0.62	36%	75%	.005
SF-12 MCS	5.7	<42	0.83	85%	71%	<.001

MCID, minimum clinically important difference; AUC, area under the curve; ASES, American Shoulder and Elbow Surgeons; SF-12, 12-Item Short Form Health Survey; PCS, Physical Component Summary; MCS, Mental Component Summary.

Preoperative ASES function, ASES pain, SF-12 PCS, and SF-12 MCS were predictive of clinically meaningful improvement at 1-year follow-up.

MCID analysis

The MCID is the difference in preoperative and postoperative scores needed to achieve meaningful clinical improvement. For all shoulder arthroplasty patients, the MCIDs were 6.5 for ASES function, 8.0 for ASES pain, 5.4 for SF-12 PCS, and 5.7 for SF-12 MCS. The percentages of patients who attained improvement greater than the MCID were as follows: ASES function, 82%; ASES pain, 76%; SF-12 PCS, 63%; and SF-12 MCS, 25%. Patients with higher preoperative SF-12 MCS scores had higher likelihood of achieving MCID for each measure.

Univariate analysis

Threshold values are the scores below which patients are likely to achieve the MCID. The threshold values for ASES function, ASES pain, SF-12 PCS, and SF-12 MCS were <12

(AUC, 0.60; $P < .001$), <25 (AUC, 0.79; $P < .001$), <46 (AUC, 0.62; $P = .005$), and <42 (AUC, 0.83; $P < .001$), respectively. Table II shows respective MCID and threshold values (including sensitivity and specificity values).

Multivariate analysis

Multivariate analysis revealed that the preoperative measures ASES function (AUC, 0.79; $P = .006$), ASES pain (AUC, 0.90; $P < .001$), and SF-12 MCS (AUC, 0.85; $P < .001$) were predictive of achieving the MCID postoperatively. There was a trend toward significance in SF-12 PCS (AUC to 0.74; $P = .05$).

Further analysis between RTSA and TSA subgroups demonstrated that for the RTSA subgroup, multivariate analysis controlling for the other preoperative measures increased threshold AUCs to 0.84 for ASES function ($P = .002$), 0.94 for ASES pain ($P < .001$), and 0.83 for SF-12 MCS ($P < .001$).

There was a trend toward increase in SF-12 PCS threshold AUC to 0.78 ($P = .06$). Multivariate analysis for the TSA subgroup was underpowered in this cohort as the only preoperative measure predictive of postoperative outcomes was SF-12 MCS (AUC, 0.90; $P = .05$).

Discussion

The objective of our study was to determine if preoperative outcome measures predict meaningful improvement after TSA and RTSA. We defined threshold values that predict clinically meaningful improvement after shoulder arthroplasty and found that shoulder-specific outcome measures are particularly strong predictors. Patients with higher preoperative mental health scores and lower physical function and pain scores were more likely to gain significant benefits from surgery.

There are several limitations of this study. First, this study was conducted at a single academic institution, and thus the results of our study may not be generalizable to all patient populations. We reported on 1-year follow-up for our cohort of shoulder arthroplasty patients. This length of follow-up may be considered a limitation; however, we believe this length of follow-up is adequate on the basis of our objective and supporting literature. Multiple studies show that patients have substantial improvement in pain and function within 1 year after shoulder arthroplasty. Levy et al demonstrated that pain relief was rapid (within 6 months) in both TSA and RTSA.¹⁹ In the same study, TSA patients demonstrated 90% to 100% functional improvement and RTSA patients had 72% to 91% improvement at 6 months.¹⁹ Return to sports literature shows that patients are able to return to full participation in recreational sports, such as golfing, swimming, and tennis, between 5 and 8 months after shoulder arthroplasty.^{20,27} The SF-12 and ASES scales were used as the general and shoulder-specific outcome measures in this study, respectively. Other shoulder-specific measures (ie, the Constant score, the Simple Shoulder Test, the University of California–Los Angeles shoulder score) were not analyzed in this study. Confounding factors that may affect postoperative outcomes should also be considered and include variability between different surgeons and variation in surgical technique and patient conformity to rehabilitation protocols. In addition, heterogeneity in shoulder pathologic processes in our study population may affect the results of this study.

The decision to proceed with shoulder arthroplasty is multifaceted for both patients and physicians. As more shoulder arthroplasty procedures are performed, many patients are satisfied with their postoperative outcomes. However, a subset of patients experience less than optimal outcomes, and it is important to determine who these patients are to maximize clinical utility of these procedures and to improve patient expectations and satisfaction.^{9,14}

Studies have evaluated the effect of shoulder arthroplasty on health-related quality of life measures, including

both generic and shoulder-specific measures.^{10,15} As expected, the studies concluded that shoulder arthroplasty was a successful procedure, resulting in significant improvements in pain and function compared with preoperative baseline scores. Our results are consistent with these studies, with the percentage of all shoulder arthroplasty patients attaining improvement greater than the MCID, ranging from 63% to 82% for ASES pain, function, and SF-12 PCS outcome measures.

We found that patients with higher preoperative mental health scores and lower physical function and pain scores were the most likely to achieve significant improvement postoperatively. Patients with higher preoperative SF-12 MCS scores had higher likelihood of achieving MCID for each measure. This suggests that optimizing a patient's baseline mental and emotional health may be beneficial in maximizing improvement in function and pain after surgery. Future studies could explore interventions aimed toward improving preoperative mental and emotional health in those at-risk patients to improve their outcomes.

In our study, we defined preoperative PROM threshold values for TSA and RTSA that predict clinically meaningful improvement. The results of our study were similar to those of published studies suggesting that preoperative pain and functional status predict postoperative improvement.^{1,3,4} Multivariate analysis demonstrated that shoulder-specific measures better predicted clinically significant improvement after surgery compared with generic measures, which is consistent with our hypothesis and existing literature.³ Both the ASES pain (AUC, 0.79; $P = .006$) and function (AUC, 0.90; $P < .001$) scores reached statistical significance, whereas there was a trend toward significance for the SF-12 PCS measure (AUC, 0.74; $P = .053$).

Lower preoperative ASES pain scores predicted lower scores at 1-year follow-up; however, this was a larger change from baseline compared with patients with higher preoperative scores. This finding suggests that patients with higher ASES pain scores preoperatively are less likely to realize significant improvement after surgery, possibly reflecting diminishing returns. This phenomenon has been previously described in the hip arthroplasty literature.¹⁵

Some have questioned the ability of arthroplasty to improve mental or emotional health.^{3,13} In our study, just 25% of patients had improvement greater than the SF-12 MCS MCID. This is consistent with other studies that have failed to show a change in mental health status after shoulder arthroplasty^{3,13} and hip arthroplasty.² These results imply that shoulder arthroplasty may not have an effect on mental health, and thus we propose that the SF-12 MCS threshold value of 42 is not clinically applicable. We caution against using the preoperative mental health score to exclude patients from surgery (concerns about lack of improvement in mental or emotional health postoperatively) as patients do exhibit clinically significant improvements in pain and function after shoulder arthroplasty.

Conclusion

In this study, we defined threshold values as a new tool for interpreting preoperative outcome measure scores to predict clinically meaningful improvement after shoulder arthroplasty. Those with lower preoperative physical function and pain scores and higher mental health scores were more likely to benefit after surgery. The results of our study can be used to forecast expected benefits and overall enhance the richness of physician-patient discussion surrounding the decision-making process.

Disclaimer

Zimmer, Inc provided a grant for this research study. These funds were not used in the data collection, data analysis, or preparation or editing of this manuscript.

Brian T. Feeley has received research support funding from Zimmer.

C. Benjamin Ma has received research support funding from Zimmer. He or a member of his immediate family has received or may receive payments or benefits during the study period from Zimmer.

The other authors, their immediate families, and any research foundations with which they are affiliated have not received any financial payments or other benefits from any commercial entity related to the subject of this article.

References

- Ayers DC, Franklin PD, Trief PM, Ploutz-Snyder R, Freund D. Psychological attributes of preoperative total joint replacement patients: implications for optimal physical outcome. *J Arthroplasty* 2004;19(Suppl 2):125-30. <http://dx.doi.org/10.1016/j.arth.2004.06.019>
- Berliner JL, Brodke DJ, Chan V, SooHoo NF, Bozic KJ. John Charnley Award: preoperative patient-reported outcome measures predict clinically meaningful improvement in function after THA. *Clin Orthop* 2015;474:321-9. <http://dx.doi.org/10.1007/s11999-015-4350-6>
- Carter MJ, Mikuls TR, Nayak S, Fehringer EV, Michaud K. Impact of total shoulder arthroplasty on generic and shoulder-specific health-related quality-of-life measures: a systematic literature review and meta-analysis. *J Bone Joint Surg Am* 2012;94:e127. <http://dx.doi.org/10.2106/JBJS.K.00204>
- Castricini R, Gasparini G, Di Luggo F, De Benedetto M, De Gori M, Galasso O. Health-related quality of life and functionality after reverse shoulder arthroplasty. *J Shoulder Elbow Surg* 2013;22:1639-49. <http://dx.doi.org/10.1016/j.jse.2013.01.020>
- Deshmukh AV, Koris M, Zurakowski D, Thornhill TS. Total shoulder arthroplasty: long-term survivorship, functional outcome, and quality of life. *J Shoulder Elbow Surg* 2005;14:471-9. <http://dx.doi.org/10.1016/j.jse.2005.02.009>
- Fluss R, Faraggi D, Reiser B. Estimation of the Youden Index and its associated cutoff point. *Biom J* 2005;47:458-72. <http://dx.doi.org/10.1002/bimj.200410135>
- Fortin PR, Clarke AE, Joseph L, Liang MH, Tanzer M, Ferland D, et al. Outcomes of total hip and knee replacement: preoperative functional status predicts outcomes at six months after surgery. *Arthritis Rheum* 1999;42:1722-8.
- Frankle M, Siegal S, Pupello D, Saleem A, Mighell M, Vasey M. The reverse shoulder prosthesis for glenohumeral arthritis associated with severe rotator cuff deficiency. A minimum two-year follow-up study of sixty patients. *J Bone Joint Surg Am* 2005;87:1697-705. <http://dx.doi.org/10.2106/JBJS.D.02813>
- Franta AK, Lenters TR, Mounce D, Neradilek B, Matsen FA 3rd. The complex characteristics of 282 unsatisfactory shoulder arthroplasties. *J Shoulder Elbow Surg* 2007;16:555-62. <http://dx.doi.org/10.1016/j.jse.2006.11.004>
- Gortmaker SL, Hosmer DW, Lemeshow S. Applied logistic regression. *Contemp Sociol* 1994;23:159.
- Guery J, Favard L, Sirveaux F, Oudet D, Mole D, Walch G. Reverse total shoulder arthroplasty. Survivorship analysis of eighty replacements Followed for five to ten years. *J Bone Joint Surg Am* 2006;88:1742-7. <http://dx.doi.org/10.2106/JBJS.E.00851>
- Haines JF. The results of arthroplasty in osteoarthritis of the shoulder. *J Bone Joint Surg Am* 2006;88-B:496-501. <http://dx.doi.org/10.1302/0301-620X.88B4.16604>
- Harreld K, Clark R, Downes K, Virani N, Frankle M. Correlation of subjective and objective measures before and after shoulder arthroplasty. *Orthopedics* 2013;36:808-14. <http://dx.doi.org/10.3928/01477447-20130523-29>
- Hasan SS, Leith JM, Campbell B, Kapil R, Smith KL, Matsen FA 3rd. Characteristics of unsatisfactory shoulder arthroplasties. *J Shoulder Elbow Surg* 2002;11:431-41. <http://dx.doi.org/10.1067/mse.2002.125806>
- Holtzman J, Saleh K, Kane R. Effect of baseline functional status and pain on outcomes of total hip arthroplasty. *J Bone Joint Surg Am* 2002;84-A:1942-8.
- Jain NB, Yamaguchi K. The contribution of reverse shoulder arthroplasty to utilization of primary shoulder arthroplasty. *J Shoulder Elbow Surg* 2014;23:1905-12. <http://dx.doi.org/10.1016/j.jse.2014.06.055>
- Kempton LB, Ankerson E, Wiater JM. A complication-based learning curve from 200 reverse shoulder arthroplasties. *Clin Orthop Relat Res* 2011;469:2496-504. <http://dx.doi.org/10.1007/s11999-011-1811-4>
- Kiet TK, Feeley BT, Naimark M, Gajju T, Hall SL, Chung TT, et al. Outcomes after shoulder replacement: comparison between reverse and anatomic total shoulder arthroplasty. *J Shoulder Elbow Surg* 2015;24:179-85. <http://dx.doi.org/10.1016/j.jse.2014.06.039>
- Levy JC, Everding NG, Gil CCJ, Stephens S, Giveans MR. Speed of recovery after shoulder arthroplasty: a comparison of reverse and anatomic total shoulder arthroplasty. *J Shoulder Elbow Surg* 2014;23:1872-81. <http://dx.doi.org/10.1016/j.jse.2014.04.014>
- McCarty EC, Marx RG, Maerz D, Altchek D, Warren RF. Sports participation after shoulder replacement surgery. *Am J Sports Med* 2008;36:1577-81. <http://dx.doi.org/10.1177/0363546508317126>
- Neer CS, Watson KC, Stanton FJ. Recent experience in total shoulder replacement. *J Bone Joint Surg Am* 1982;64:319-37.
- Neuburger J, Hutchings A, Black N, van der Meulen JH. Socioeconomic differences in patient-reported outcomes after a hip or knee replacement in the English National Health Service. *J Public Health (Oxf)* 2013;35:115-24. <http://dx.doi.org/10.1093/pubmed/fds048>
- Nilsdotter A-K, Petersson IF, Roos EM, Lohmander LS. Predictors of patient relevant outcome after total hip replacement for osteoarthritis: a prospective study. *Ann Rheum Dis* 2003;62:923-30. <http://dx.doi.org/10.1136/ard.62.10.923>
- Nolan BM, Ankerson E, Wiater JM. Reverse total shoulder arthroplasty improves function in cuff tear arthropathy. *Clin Orthop Relat Res* 2011;469:2476-82. <http://dx.doi.org/10.1007/s11999-010-1683-z>
- Norman GR, Sloan JA, Wyrwich KW. The truly remarkable universality of half a standard deviation: confirmation through another look. *Expert Rev Pharmacoecon Outcomes Res*. 2004;581-5. <http://doi.doi.org/10.1586/14737167.4.5.581>
- Orfaly RM, Rockwood CA, Esenyel CZ, Wirth MA. A prospective functional outcome study of shoulder arthroplasty for osteoarthritis

- with an intact rotator cuff. *J Shoulder Elbow Surg* 2003;12:214-21. [http://dx.doi.org/10.1016/S1058-2746\(02\)86882-3](http://dx.doi.org/10.1016/S1058-2746(02)86882-3)
27. Papaliadis D, Richardson N, Tartaglione J, Roberts T, Whipple R, Zanos G. Impact of total shoulder arthroplasty on golfing activity. *Clin J Sport Med* 2015;25:338-40. <http://dx.doi.org/10.1097/JSM.0000000000000148>
 28. Rolfson O, Kärrholm J, Dahlberg LE, Garellick G. Patient-reported outcomes in the Swedish Hip Arthroplasty Register: results of a nationwide prospective observational study. *J Bone Joint Surg Br* 2011;93:867-75. <http://dx.doi.org/10.1302/0301-620X.93B7.25737>
 29. Scarlat MM. Complications with reverse total shoulder arthroplasty and recent evolutions. *Int Orthop* 2013;37:843-51. <http://dx.doi.org/10.1007/s00264-013-1832-6>
 30. Schairer WW, Nwachukwu BU, Lyman S, Craig EV, Gulotta LV. National utilization of reverse total shoulder arthroplasty in the United States. *J Shoulder Elbow Surg* 2015;24:91-7. <http://dx.doi.org/10.1016/j.jse.2014.08.026>
 31. Schwartz BE, Savin DD, Youderian AR, Mossad D, Goldberg BA. National trends and perioperative outcomes in primary and revision total shoulder arthroplasty: trends in total shoulder arthroplasty. *Int Orthop* 2014;39:271-6. <http://dx.doi.org/10.1007/s00264-014-2614-5>
 32. Trofa D, Rajae SS, Smith EL. Nationwide trends in total shoulder arthroplasty and hemiarthroplasty for osteoarthritis. *Am J Orthop (Belle Mead NJ)* 2014;43:166-72.
 33. Wiater JM, Moravek JEJ, Budge MD, Koueiter DM, Marcantonio D, Wiater BP. Clinical and radiographic results of cementless reverse total shoulder arthroplasty: a comparative study with 2 to 5 years of follow-up. *J Shoulder Elbow Surg* 2014;23:1208-14. <http://dx.doi.org/10.1016/j.jse.2013.11.032>
 34. Wyrwich KW, Norquist JM, Lenderking WR, Acaster S, Industry Advisory Committee of International Society for Quality of Life Research (ISOQOL). Methods for interpreting change over time in patient-reported outcome measures. *Qual Life Res* 2013;22:475-83. <http://dx.doi.org/10.1007/s11136-012-0175-x>

